

Anatomy of use for the Endoscopic Surgeon

The Ureter
The Vessels
The Nerves
in the female pelvis

B. J van Herendael
A. de Bruin
A. Wattiez
M. Ceccaroni

Know Anatomy
Use Anatomy
Don't Loose Anatomy

Arnaud Wattiez

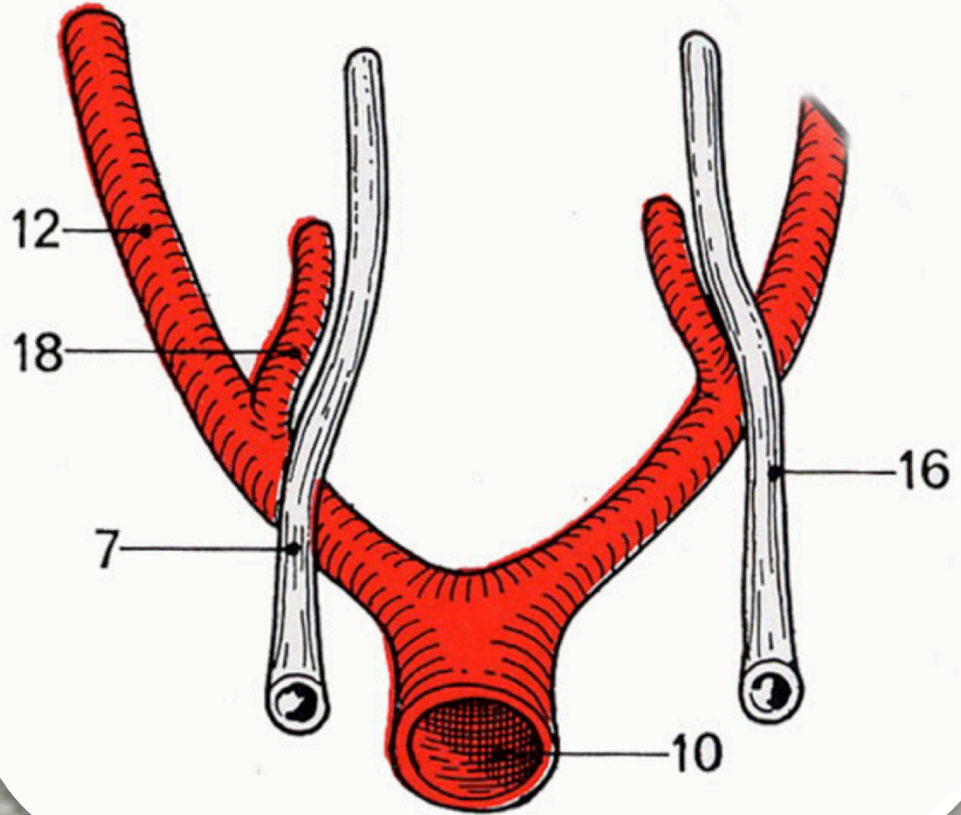
Difference between

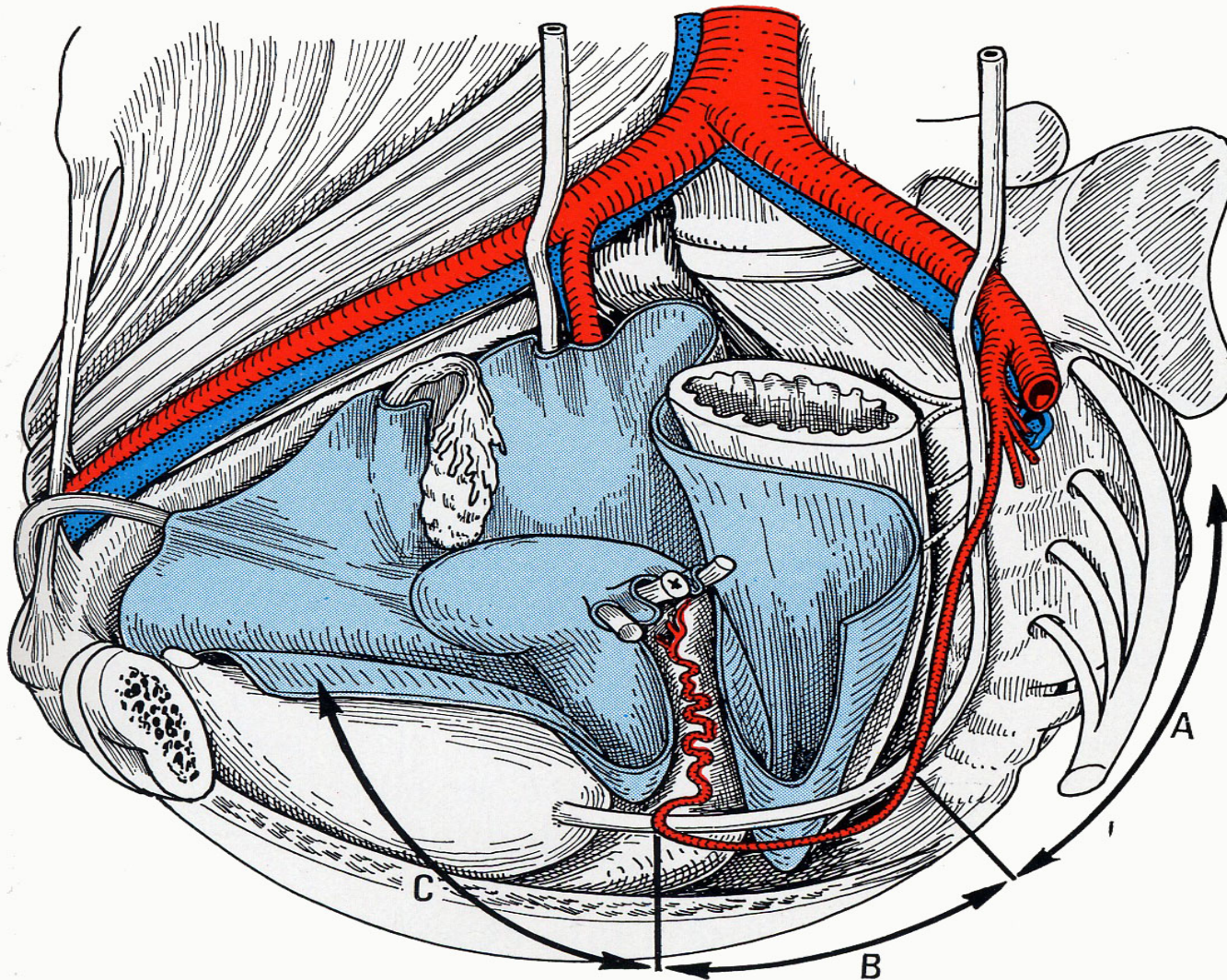
- **The left:**

Ureter crosses the Iliaca Externa and runs parallel to the Iliaca Interna outside

- **The Right:**

Ureter crosses more medial the Iliaca Communis and runs parallel to the Iliaca Interna inside

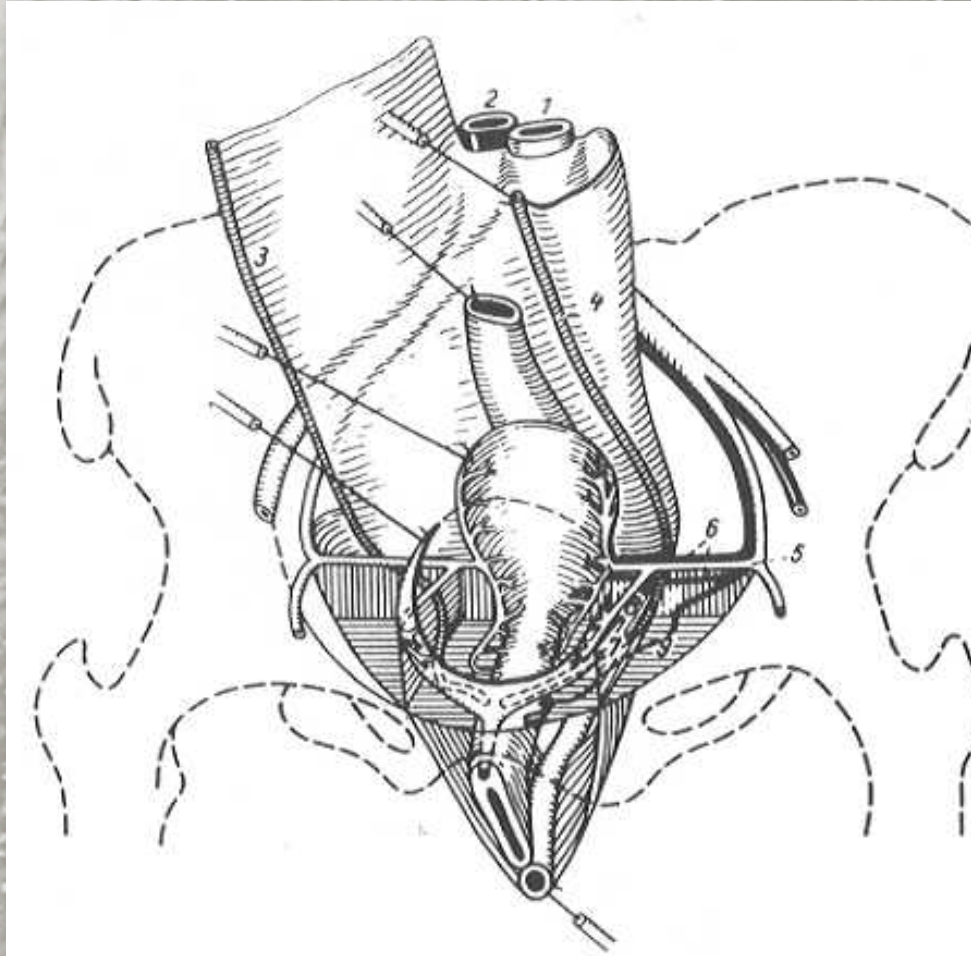




Kamina, 1984

Mesoureter

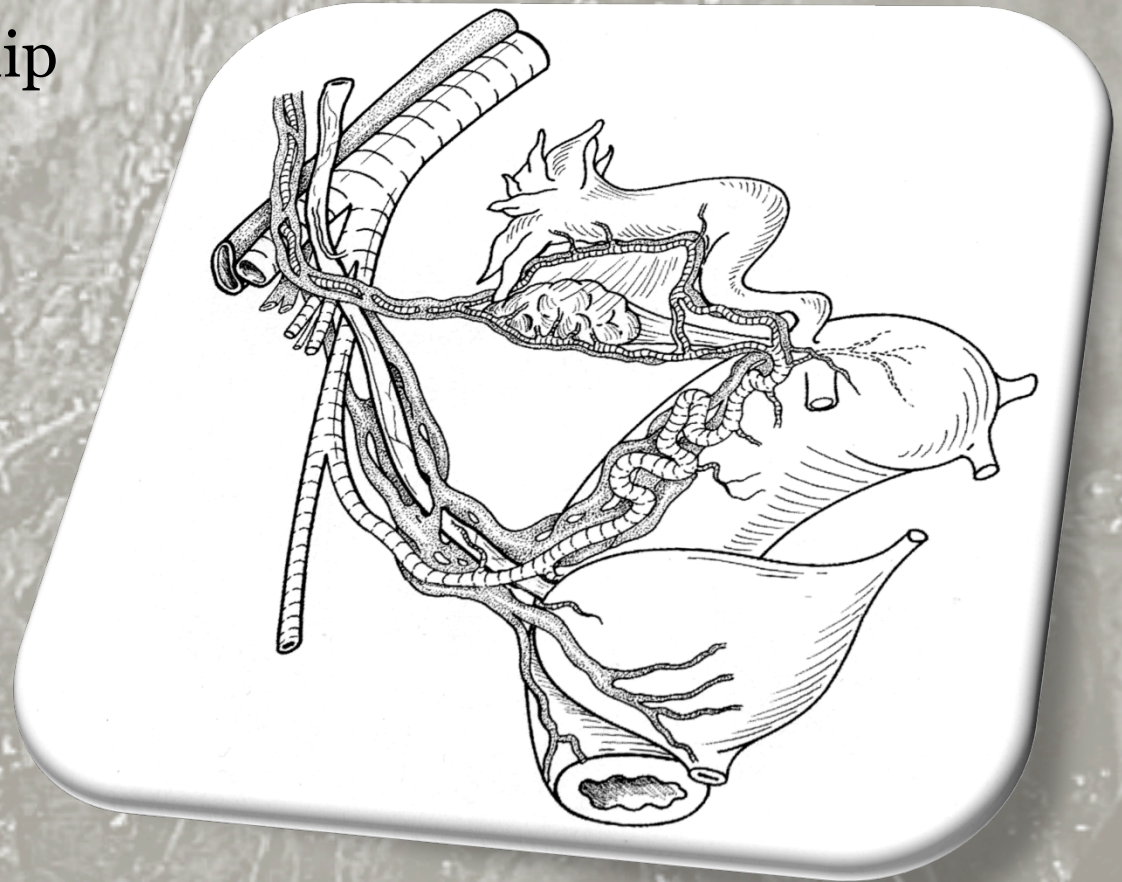
Reiffenstuhl, 1964



Right Side

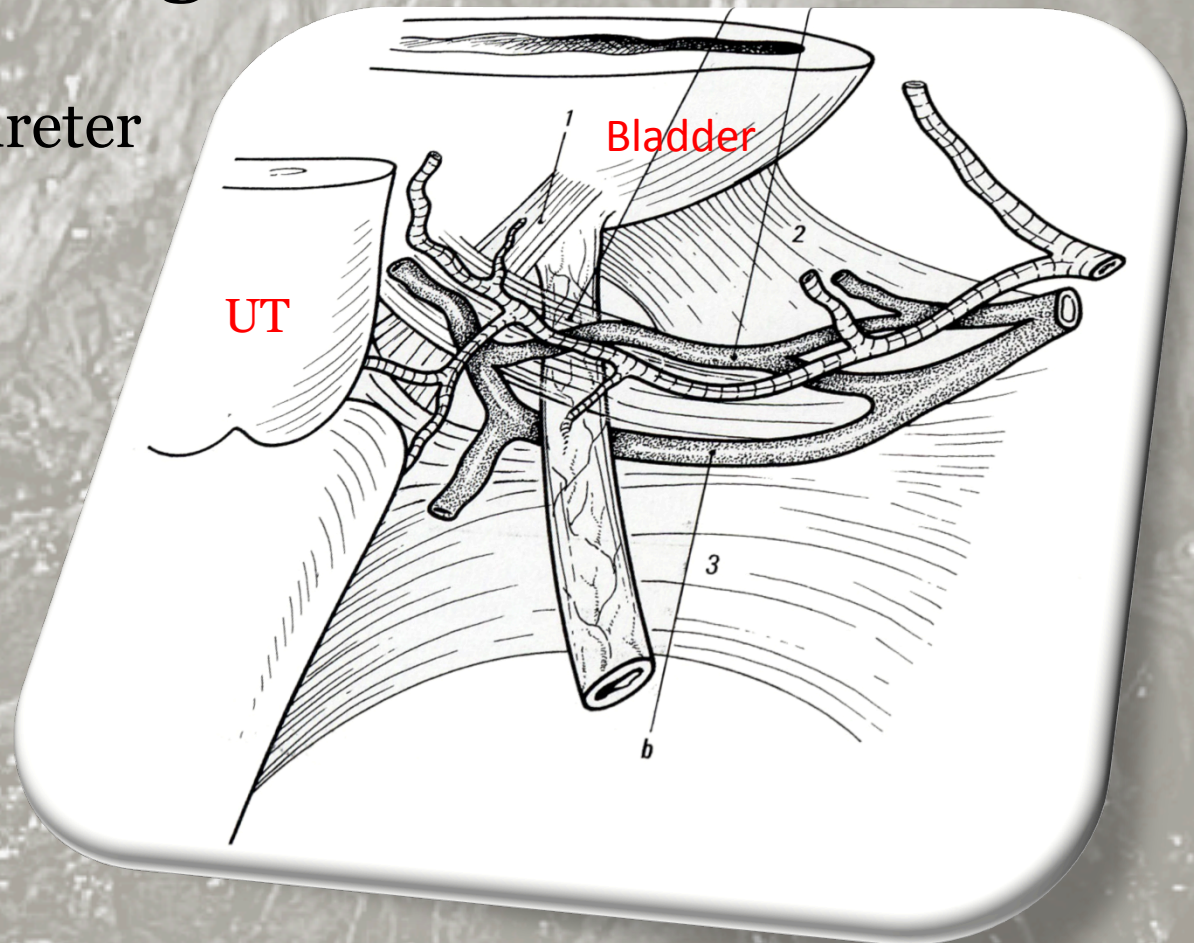
The complex relationship
Between:

- Arteries
- Ureter
- Venous elements
superficial and deep



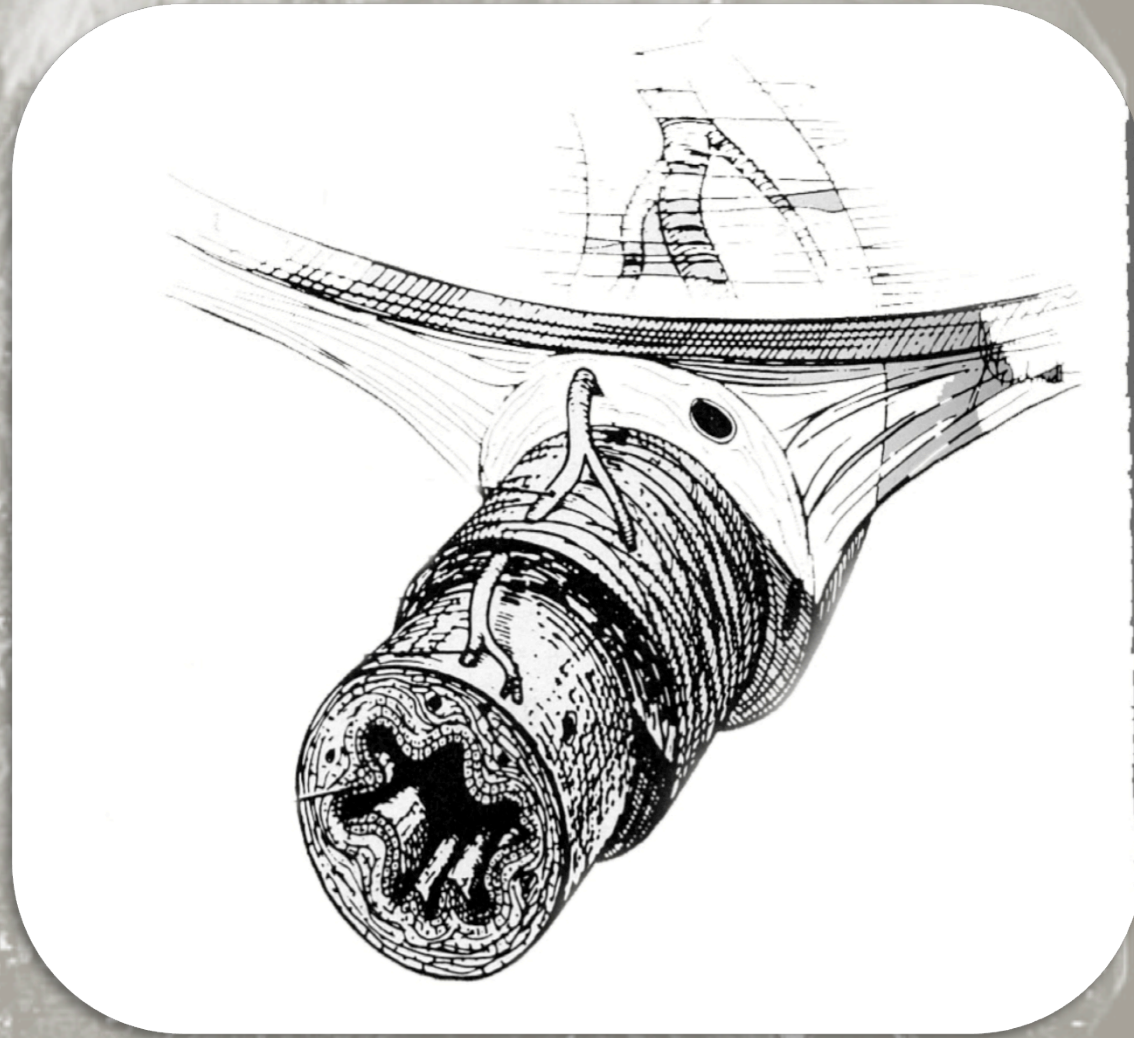
Right Side

- Detail inflow of the ureter in the bladder



Three Sheets:

- Adventitia (vascularization)
- Muscularis
- Mucosa



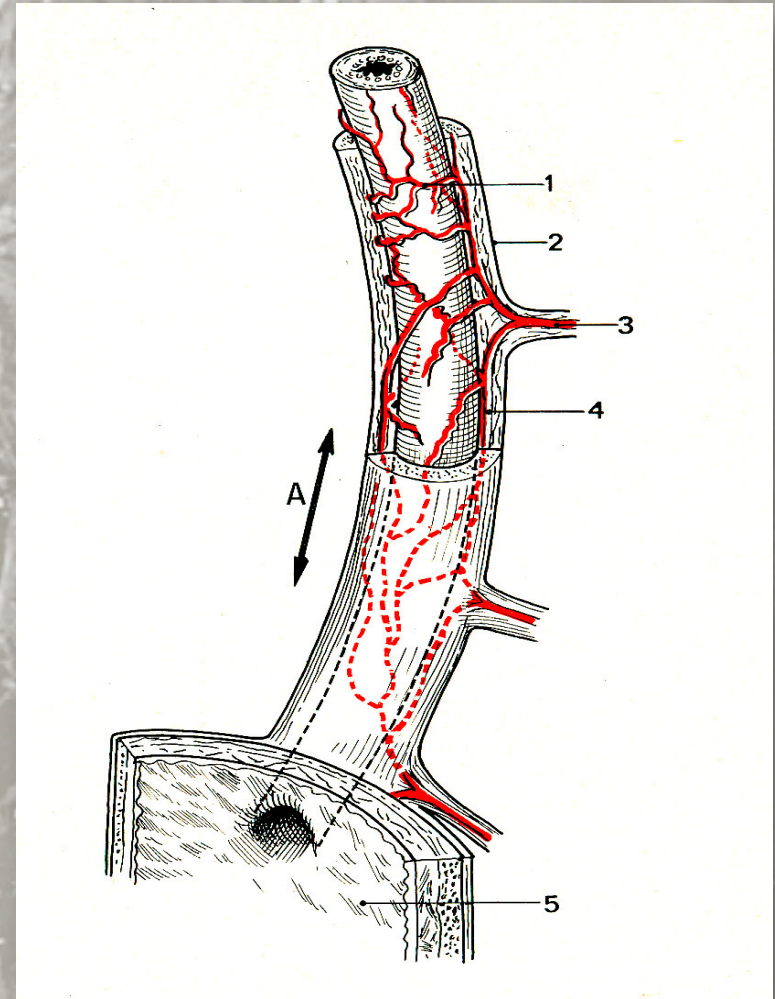
The Pelvic Ureter

The wall of the ureter consists of 3 distinct layers.

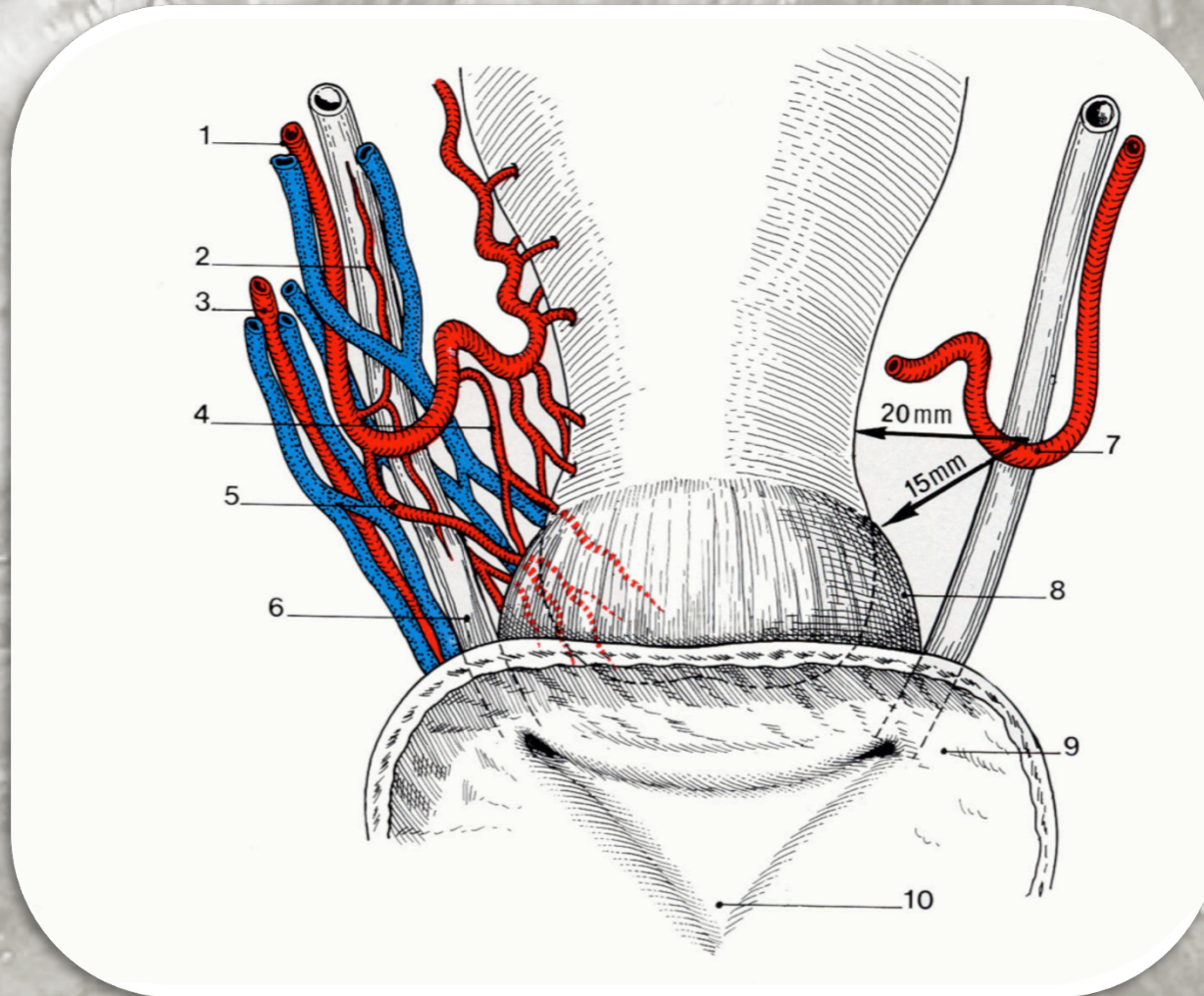
The *inner one* is transitional epithelium;

The *middle one* consists of circular and longitudinal smooth muscular fibers;

The *outer one* is an adventitial sheath. Direct abrasion of the adventitial and muscular layers must be avoided as this trauma may compromise ureteral blood supply and lead to stricture and fistula formation.



VASCULARIZATION of the URETER



VASCULARIZATION of the URETER

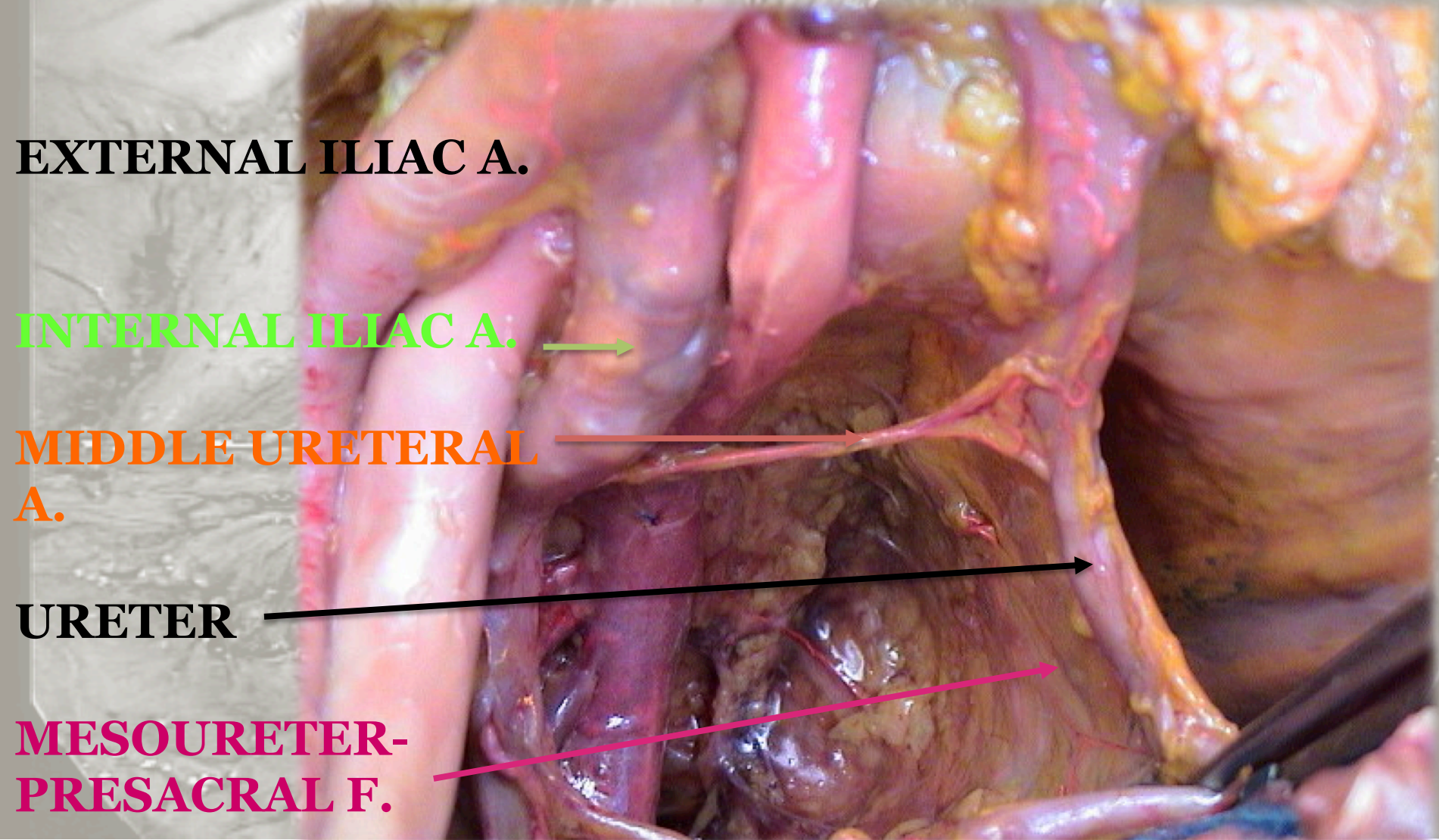
EXTERNAL ILIAC A.

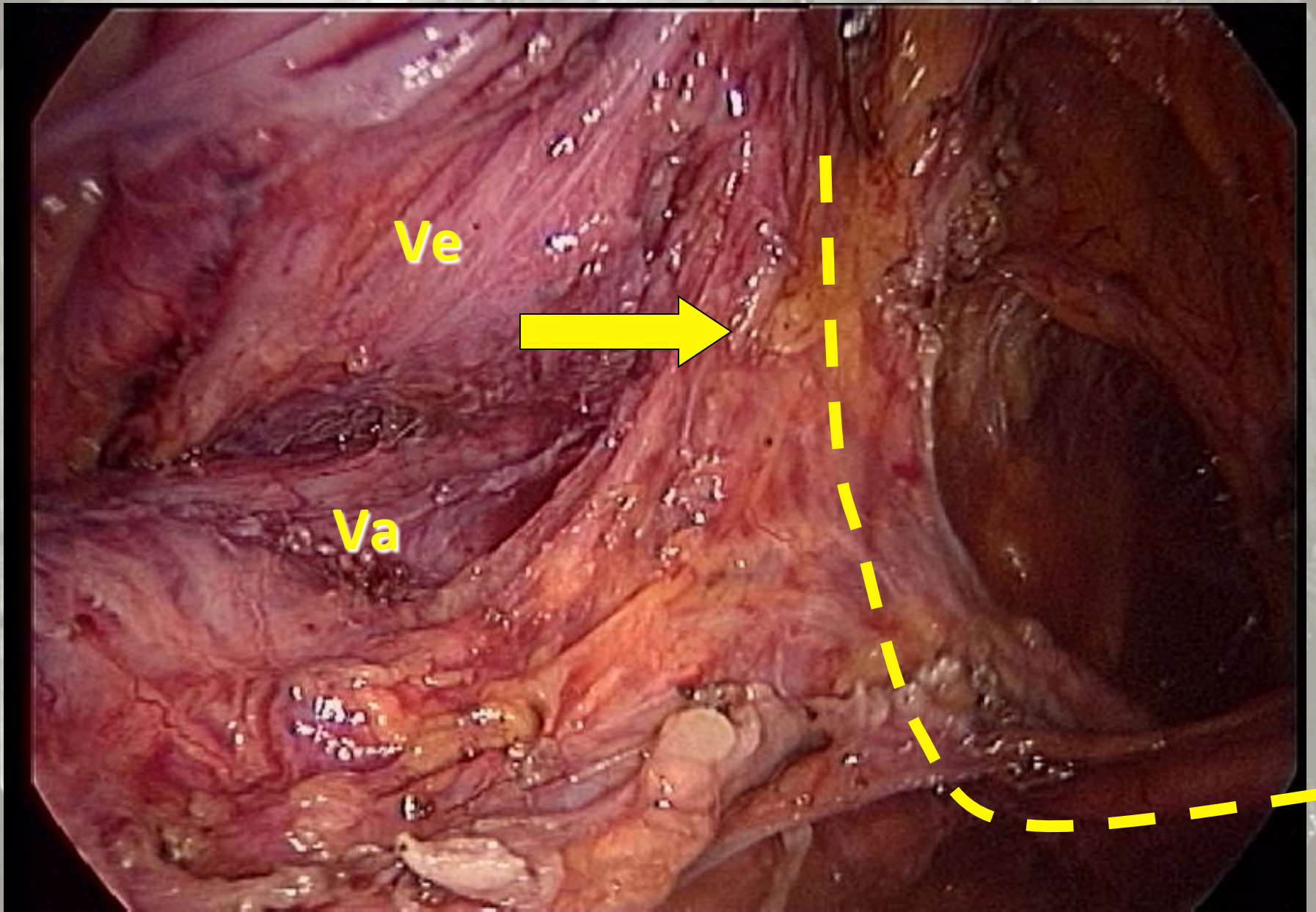
INTERNAL ILIAC A. →

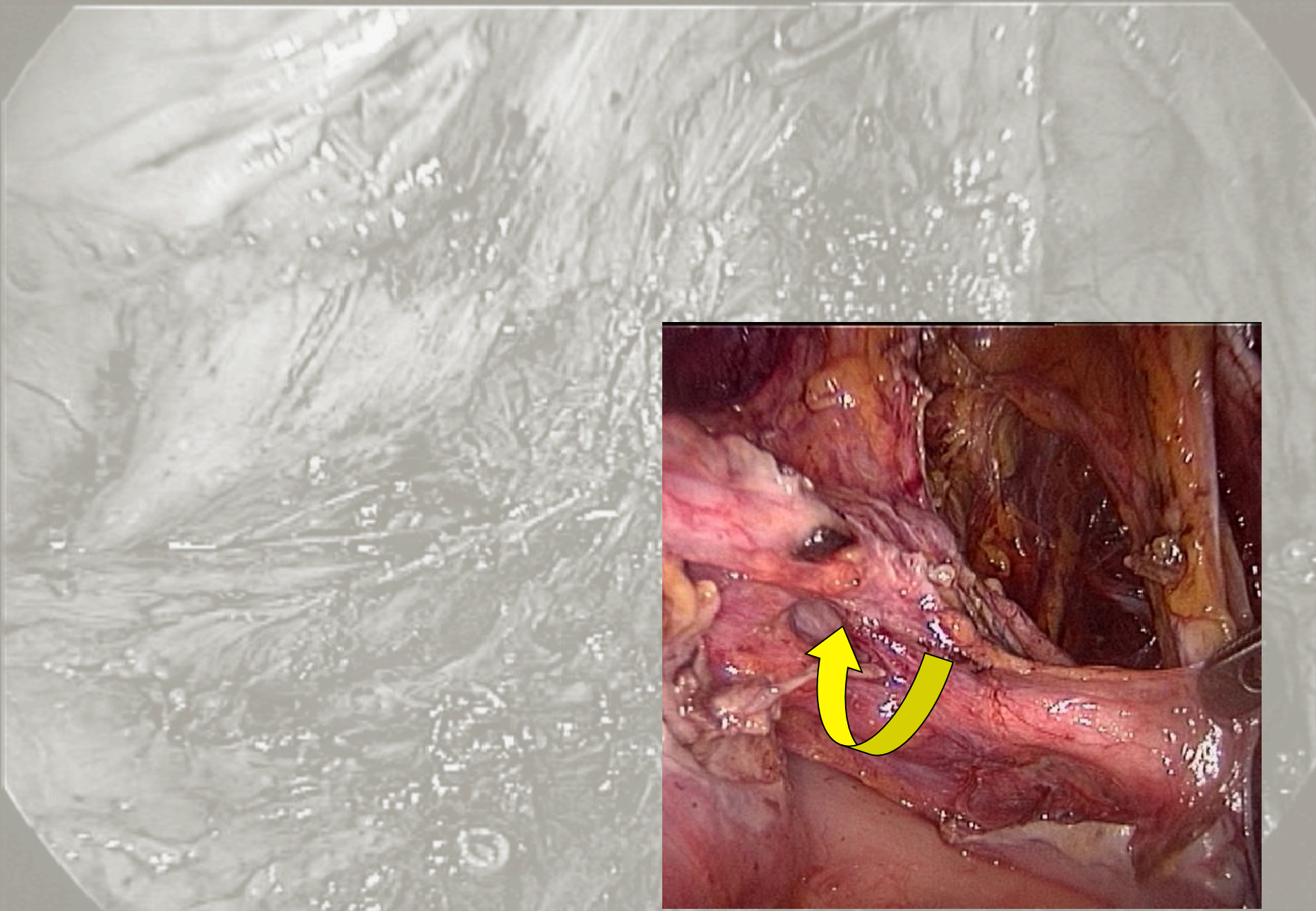
MIDDLE URETERAL A. →

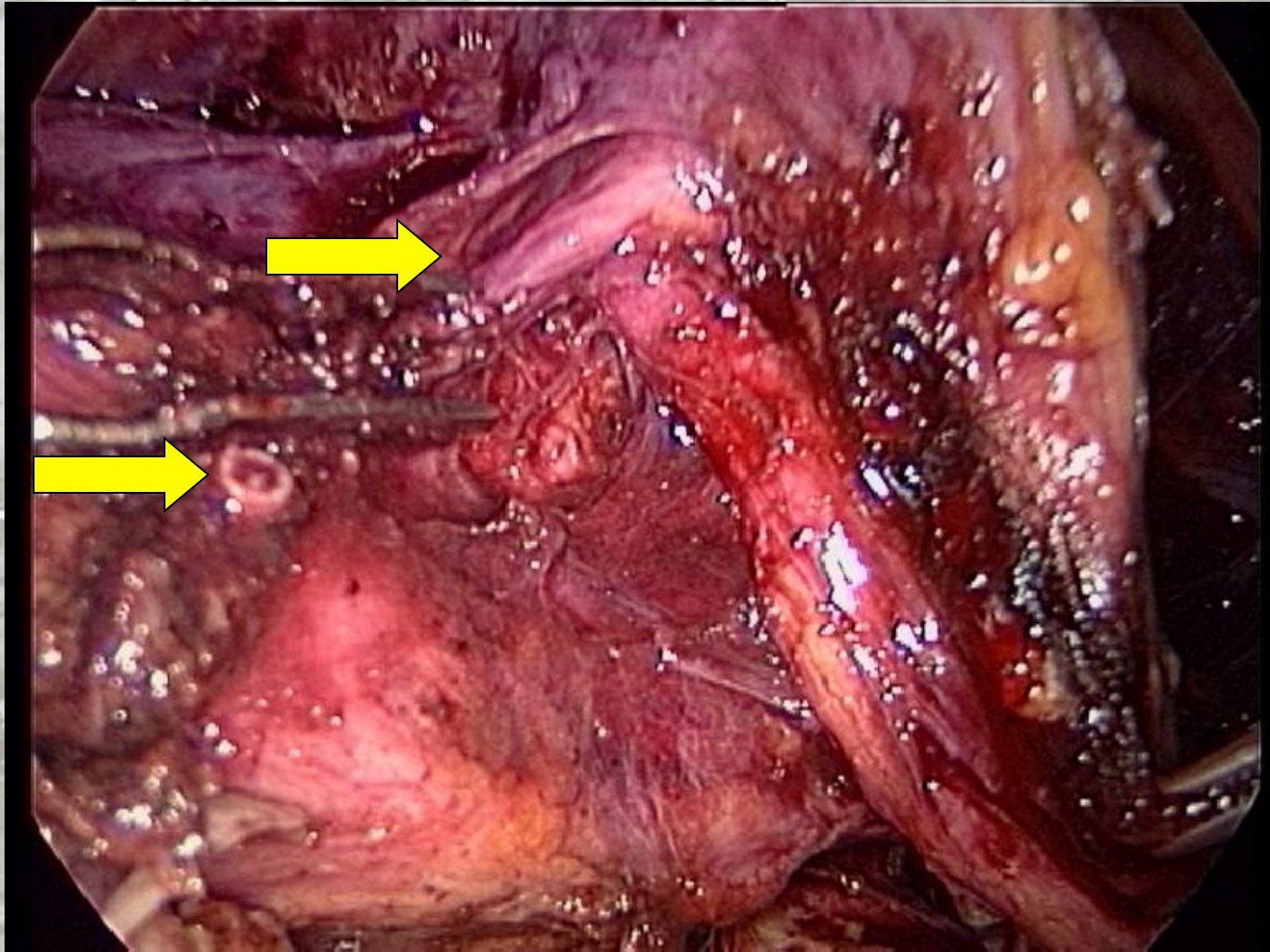
URETER →

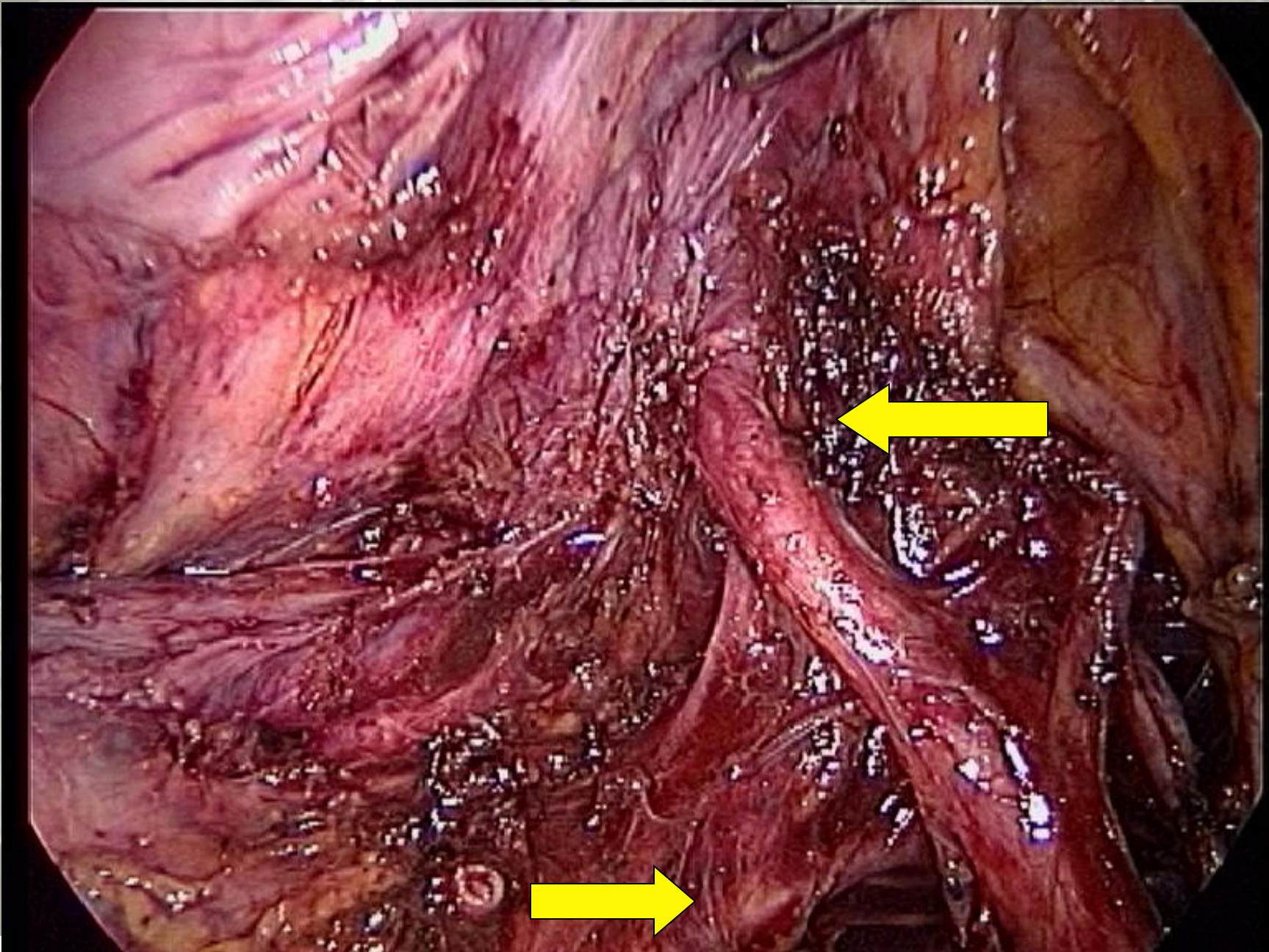
MESoureTER-PRESACRAL F. →











Dorsal comp: lateral area (med-to-lat)

Presacral fascia

Okabayashi pararectal s. - Holy plane (Heald)

Mesoureter

Ureter and Hypogastric nerve and plexus

Uterosacral/rectovaginal lig.

Latzko pararectal space

Lateral Parametrium and Paracervix

Visceral branches of Hypogastric vessels

Pelvic splanchnic nerves (S2-S4)

Hypogastric and lateral sacral vessels

Sacral roots

Parietal fascia and muscles

Hypogastric nerve

Located in the Mesoureter, 10 mm (range: 5-30 mm) caudal to the ureter and always cranial in respect to the Uterosacral lig.

It enters into the Inferior Hypogastric plexus.

Ercoli et al., Surg Rad Anat, 2003

Lesion:

Orgasm without ejaculation in men, women... ?

Loss of bladder sensitivity

Inferior Hypogastric Plexus

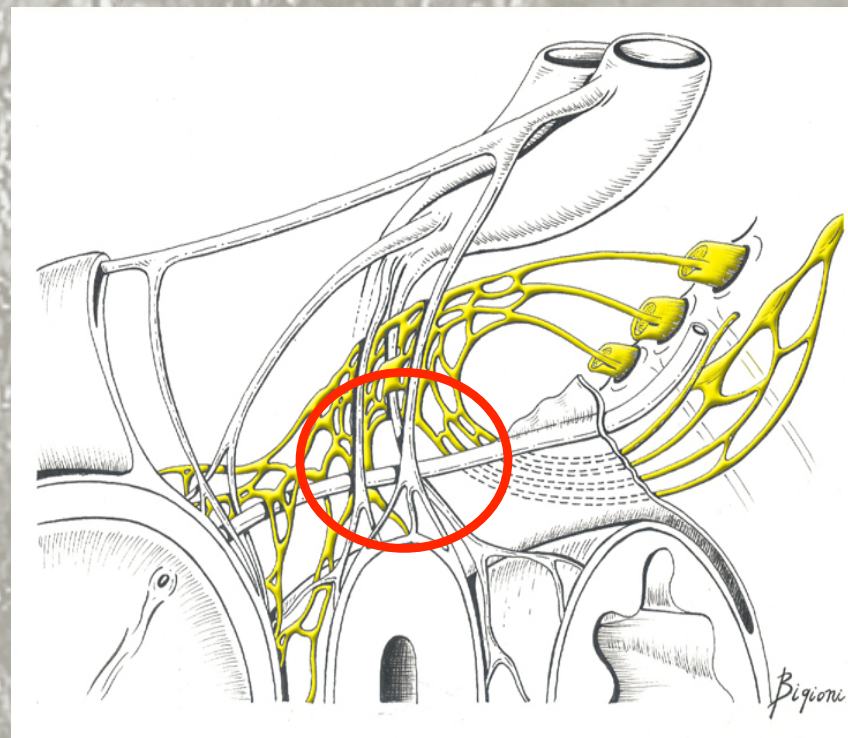
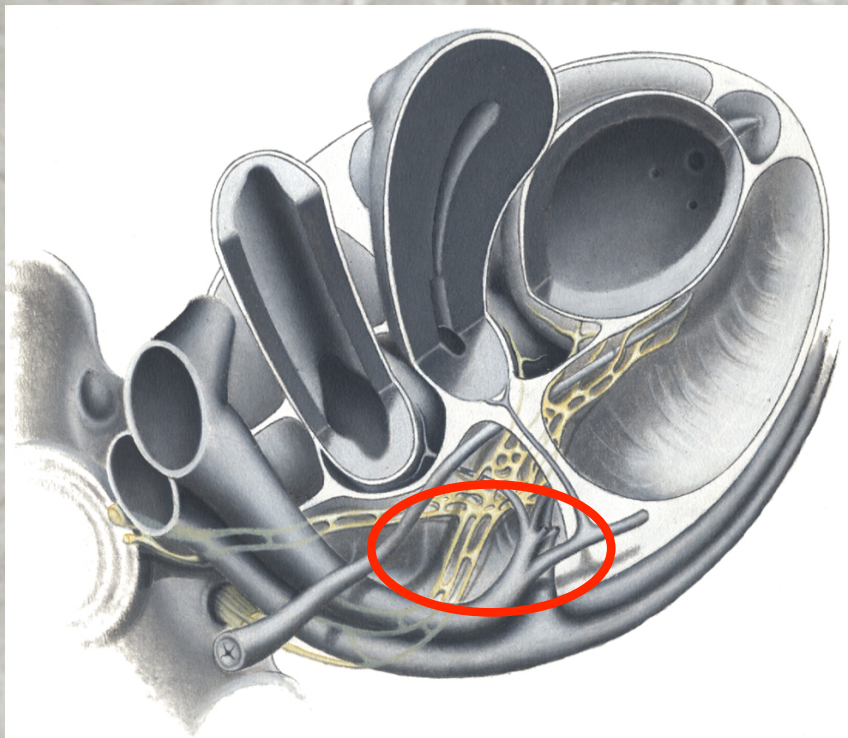
Area of nervous tissue (10-20 mm dorso-ventral length, 5-8 mm medial-lateral length) located in the Mesoureter and the Uterosacral/rectovaginal lig. formed by:

- ✓ Hypogastric nerves
- ✓ Pelvic splanchnic nerve
- ✓ Anterior branches of the sacral sympathetic chain
- ✓ Afferent-Efferent branches for pelvic organs

Lesion:

Loss of bladder sensitivity - Bladder compliance alterations - Vesico-urethral dyssinergia

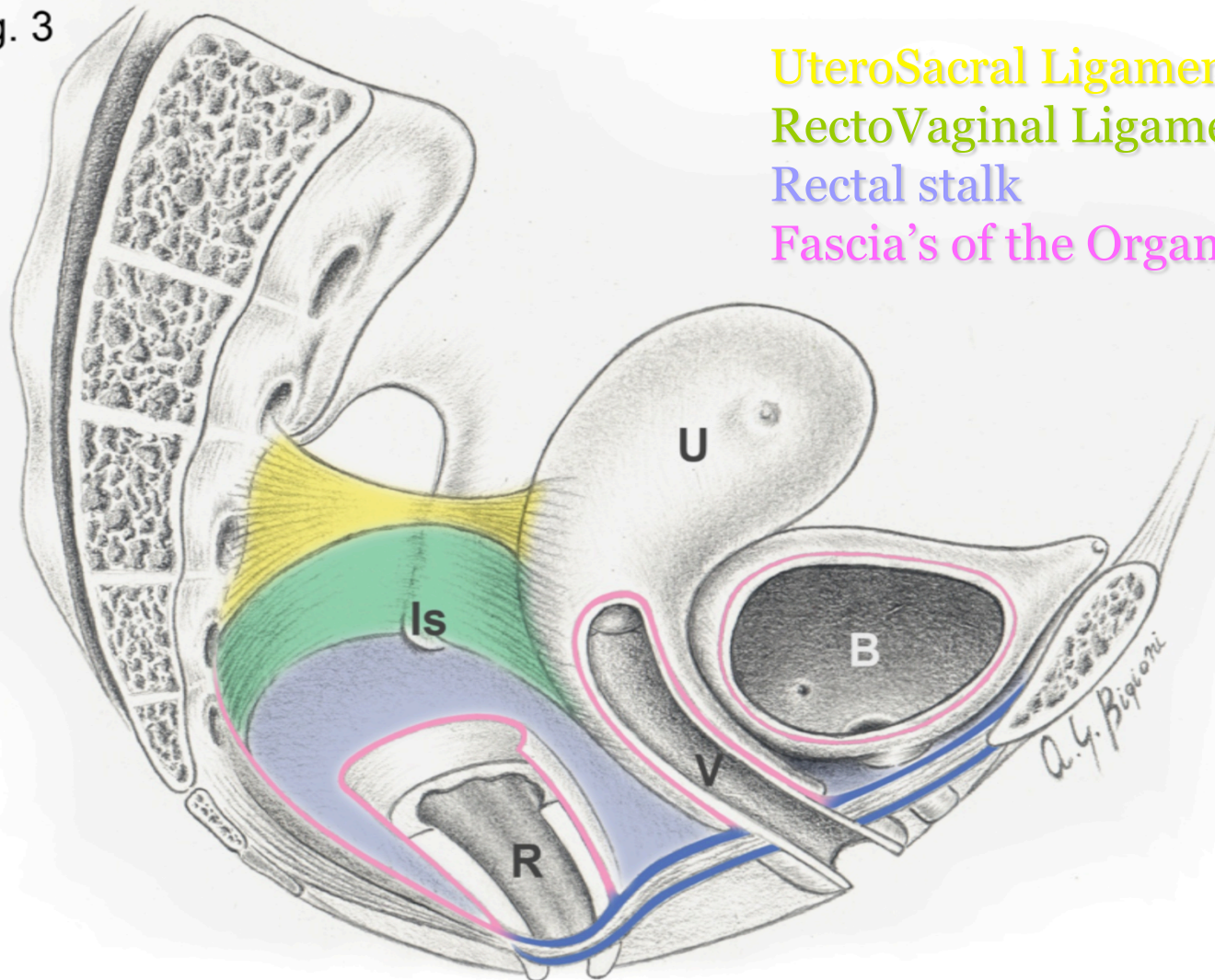
Hypogastric nerve and Inferior Hypogastric Plexus



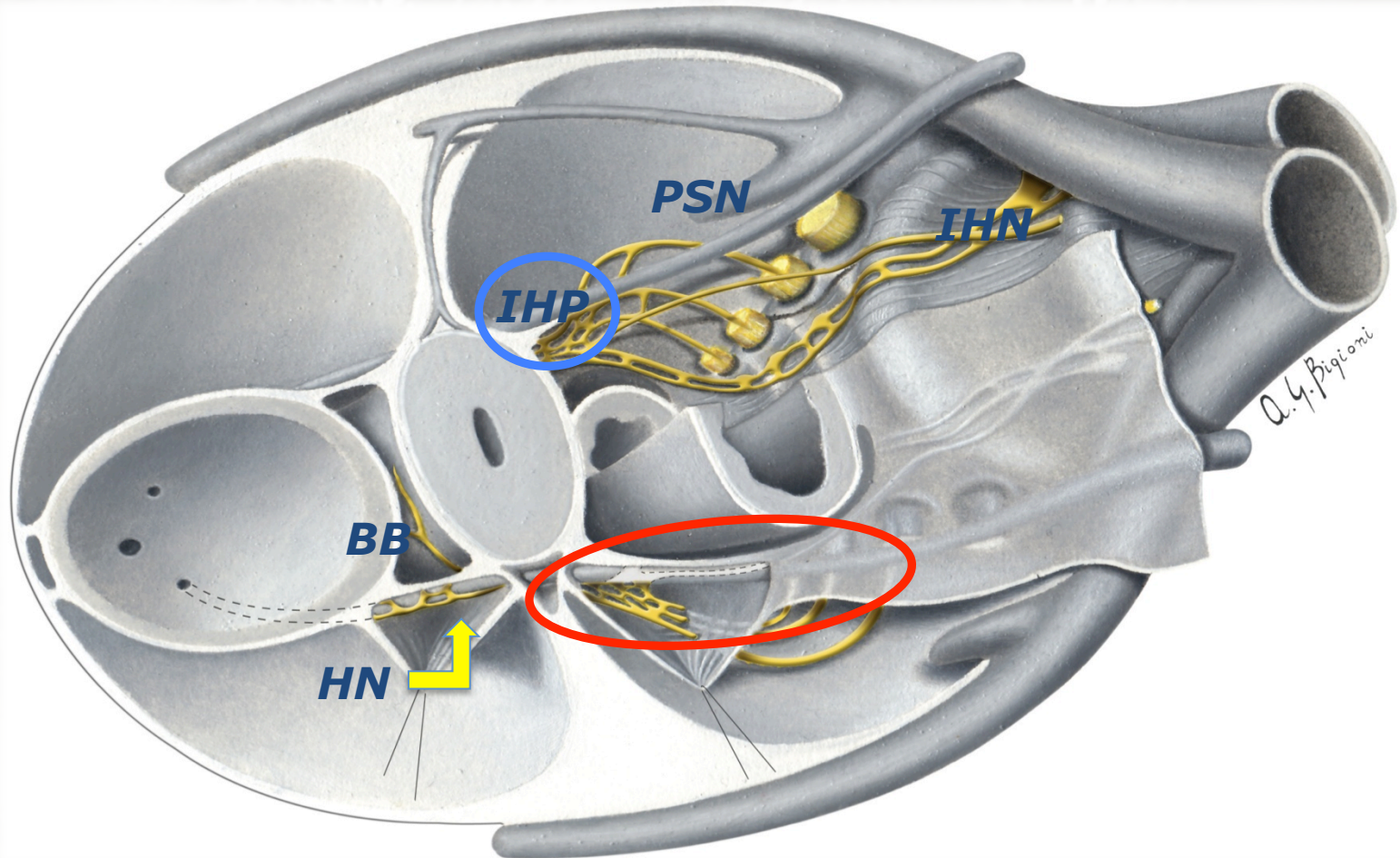
Ceccaroni M, Fanfani F, Ercoli A, Scambia G. Edizioni CIC, 2006

Uterosacral/rectovaginal lig. rectal stalk/rectosacral fascia

Fig. 3



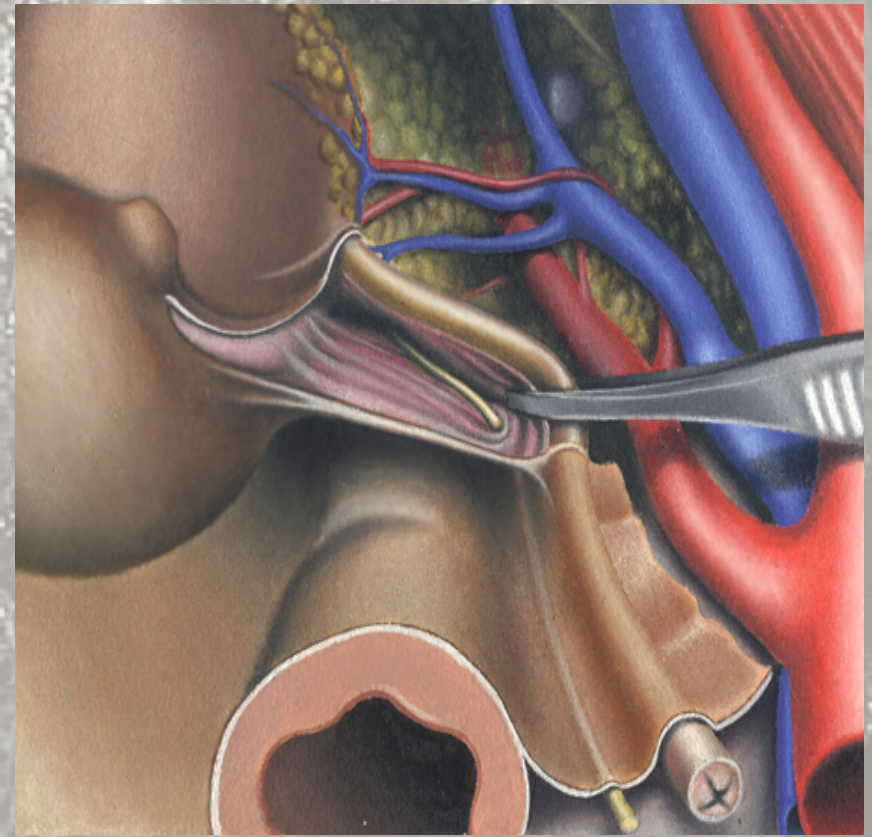
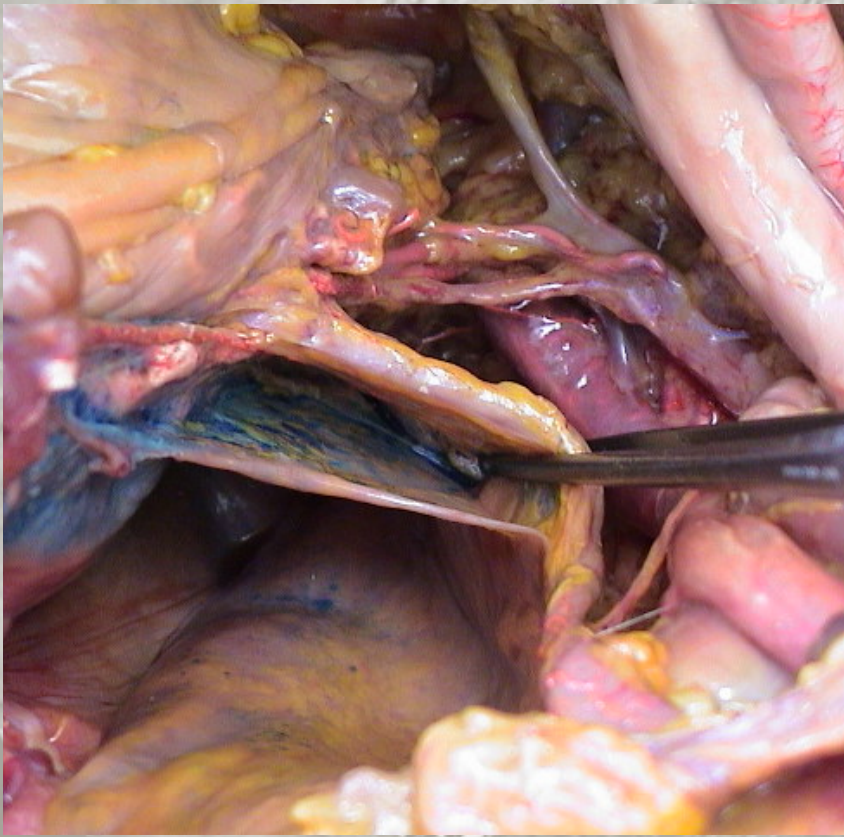
Uterosacral/rectovaginal lig. and HYP



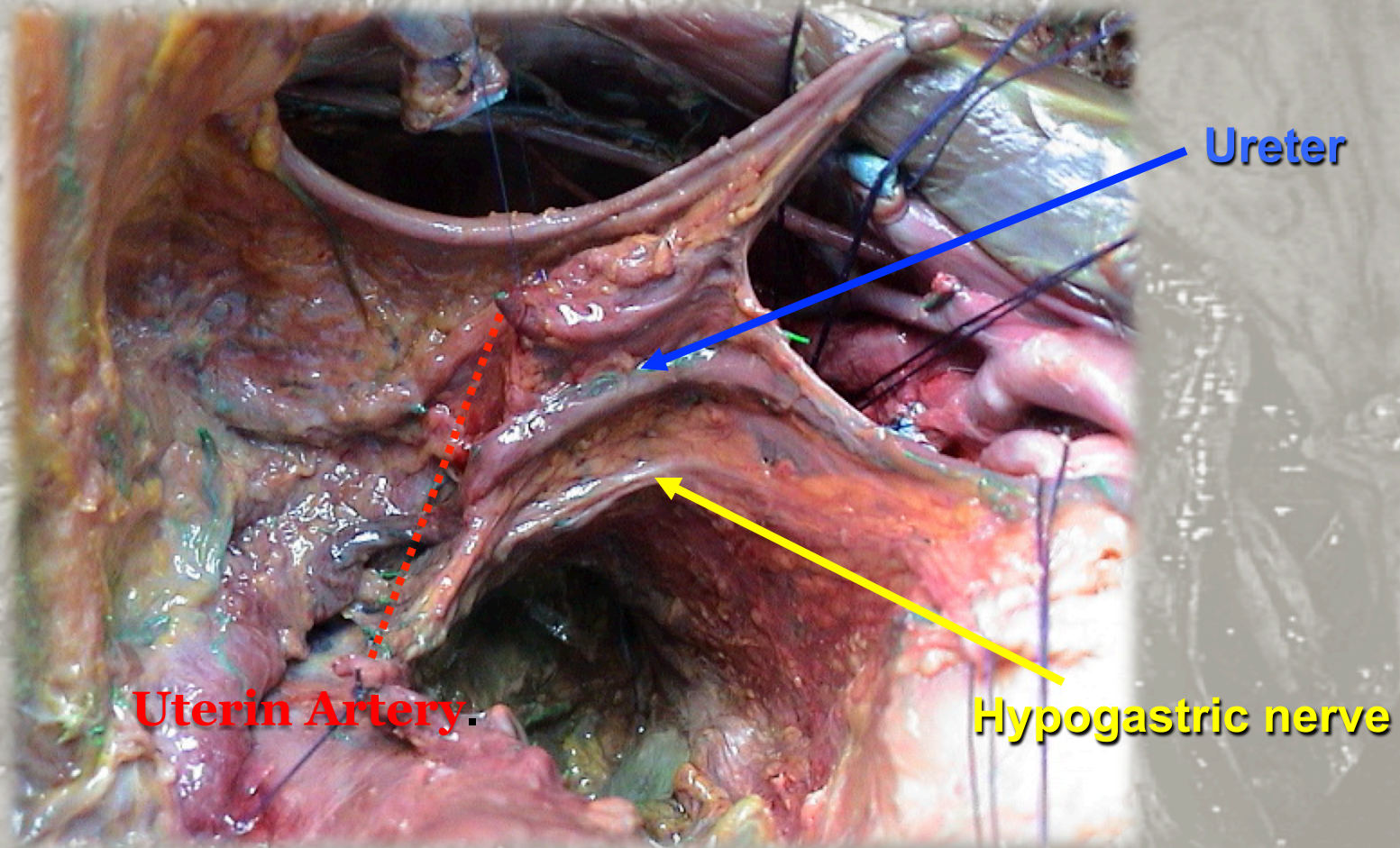
Ceccaroni M, Fanfani F, Ercoli A, Scambia G. Edizioni CIC, 2006

Pararectal space (dorso-cranial chamber)

Sec. Okabayashi

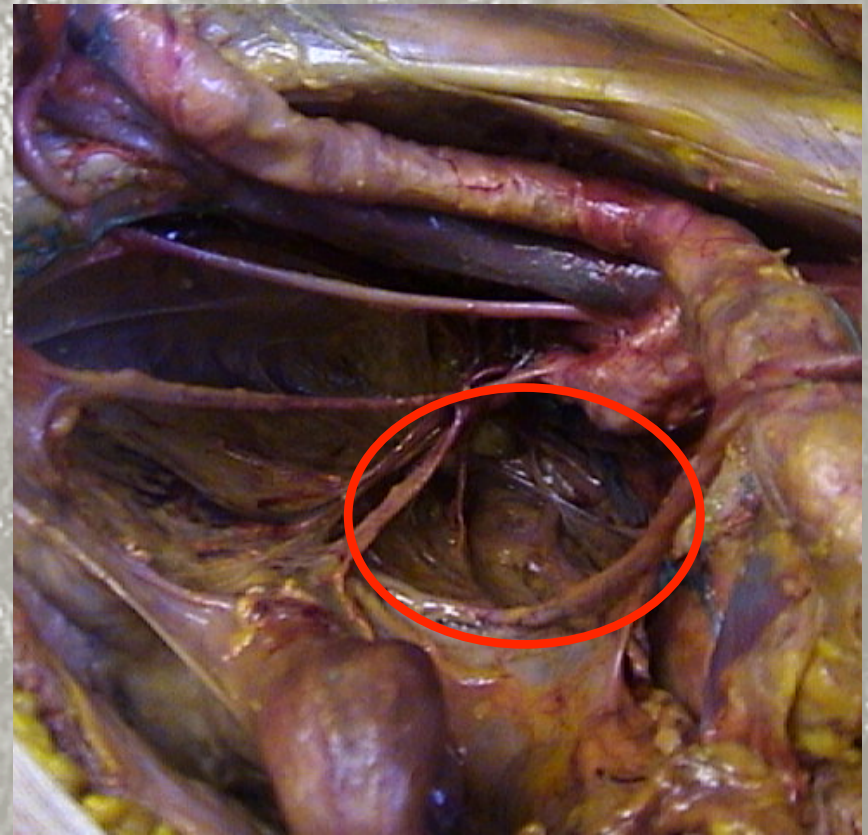
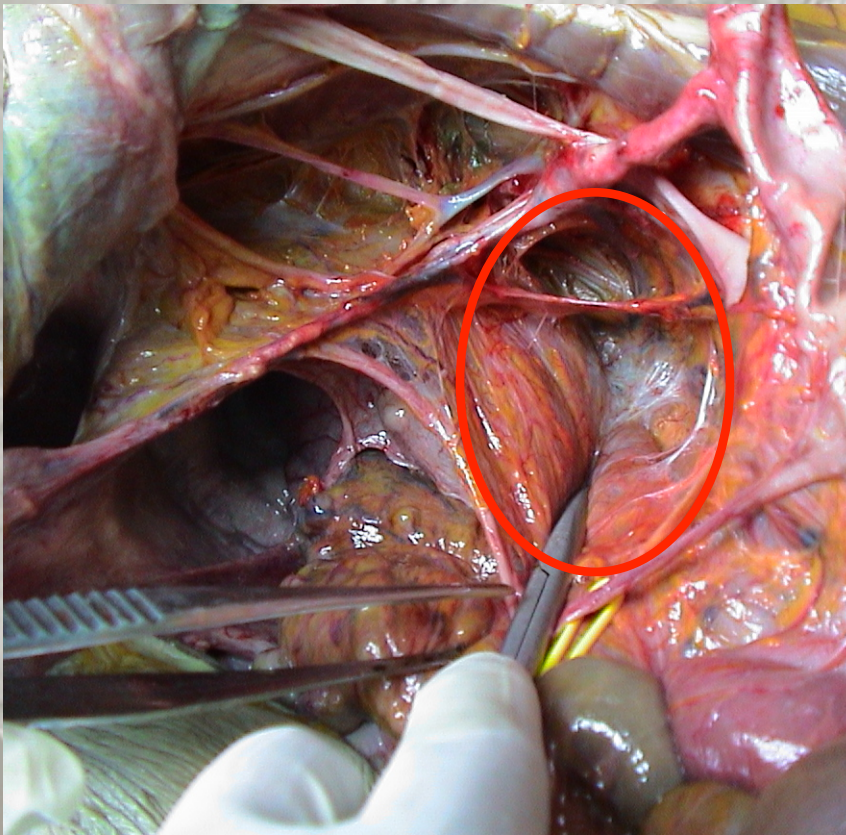


Anatomical landmarks for HN - HYP: Mesoureter-ureter



Pararectal space (dorso-cranial chamber)

Sec. Latzko



VISCERAL BRANCHES OF INTERNAL ILIAC VESSELS

Obturator nerve

Umbilical a.

Deep uterine v.

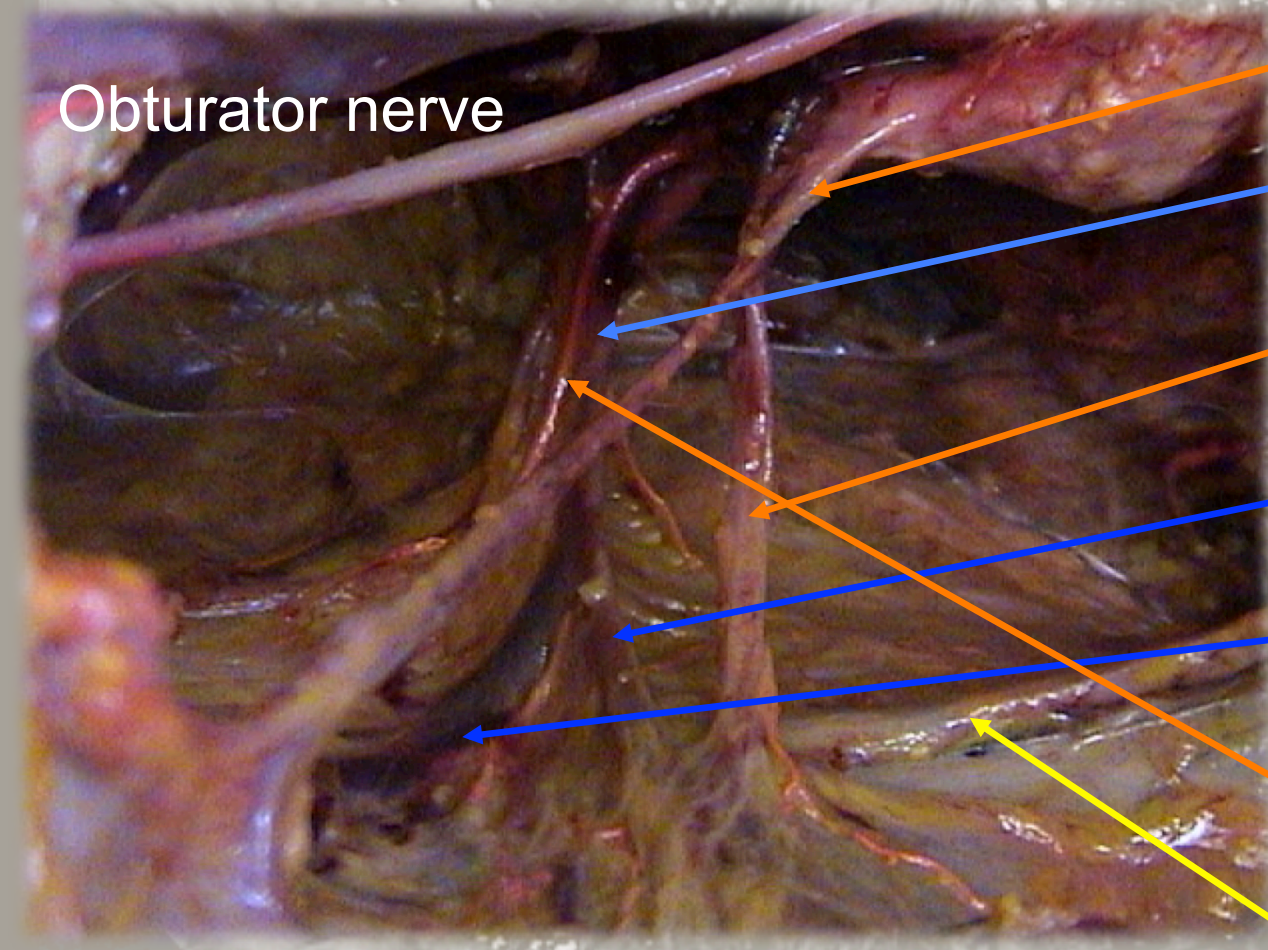
Uterin a.

Superf. uterin v.

Middle vesical v.

Inferior vesical a.

Ureter



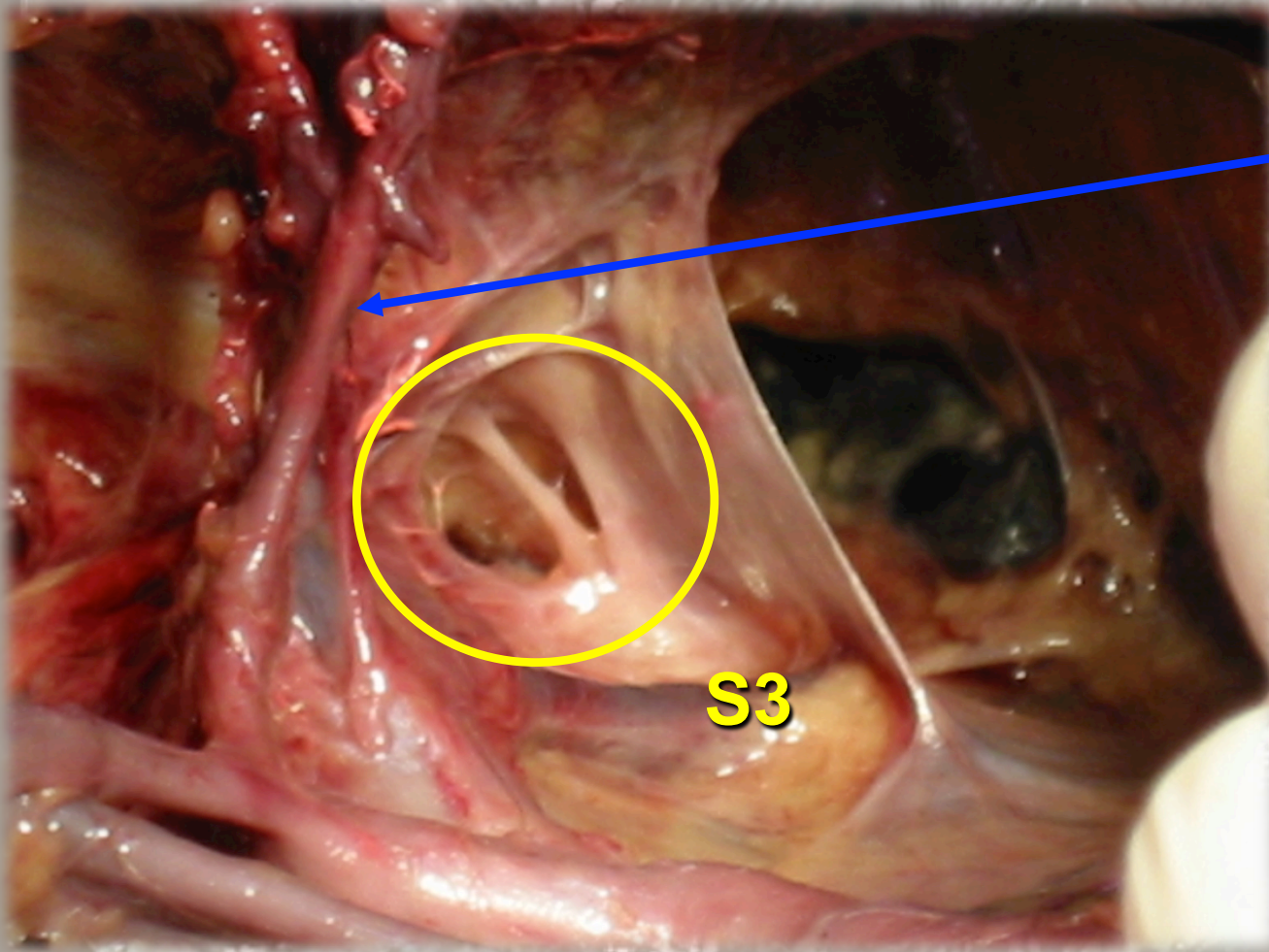
Pelvic Splanchnic nerve

2-3 nervous branches originating from S3 + nervous branches from S4 (18%), S2 (11%), S1 (9%) e S5 (6%)

They enters the Inferior Hypogastric plexus

Located caudal in respect to the deep uterin vein and the middle rectal vessels

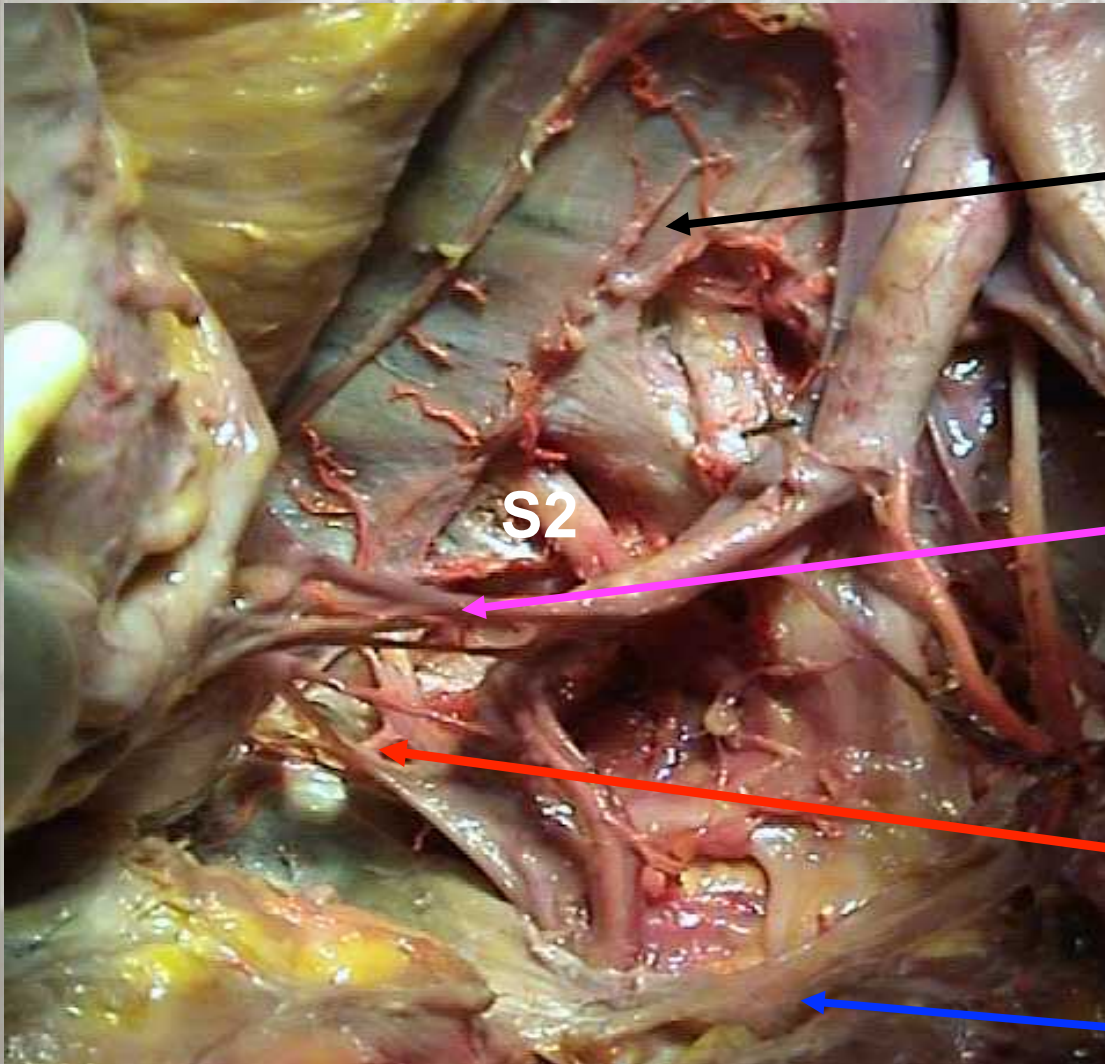
Pelvic Splanchnic Nerves



Deep uterin vein.

S3

MIDDLE RECTAL VESSELS



Sacral symphatetic chain

Middle rectal artery and/or vein
55/60 (92%) spec.

Origin from:
43/60 (72%) Int. iliac
12/60 (20%) Vaginal

Pelvic splanchnic nerves

Sacrospinous Lig.

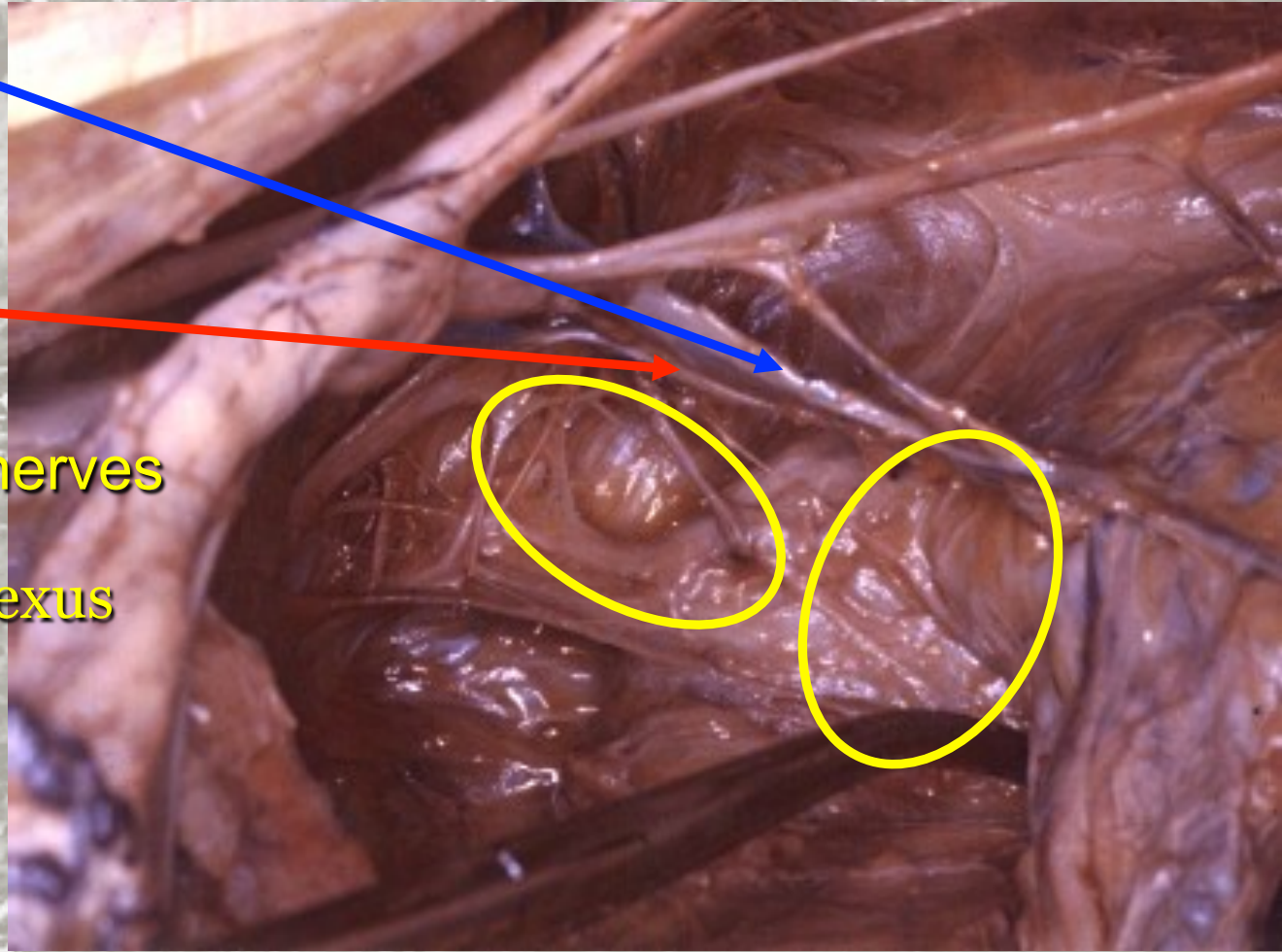
Anatomical landmarks for Pelvic Splanchnic Nerves and Hypogastric Plexus

Deep uterin v.

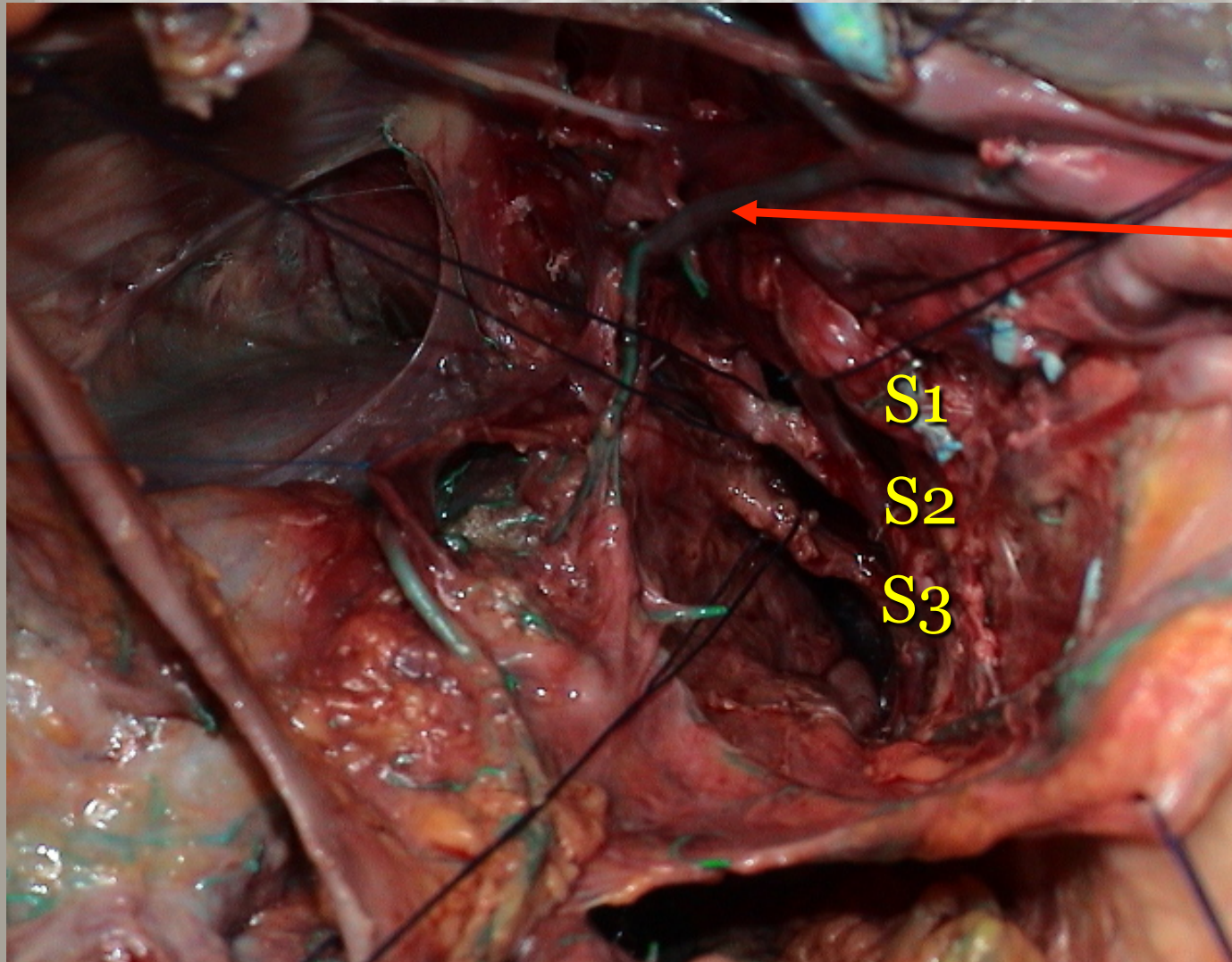
Middle Rectal A.

Pelvic Splanchnic nerves

Inf. Hypogastric Plexus



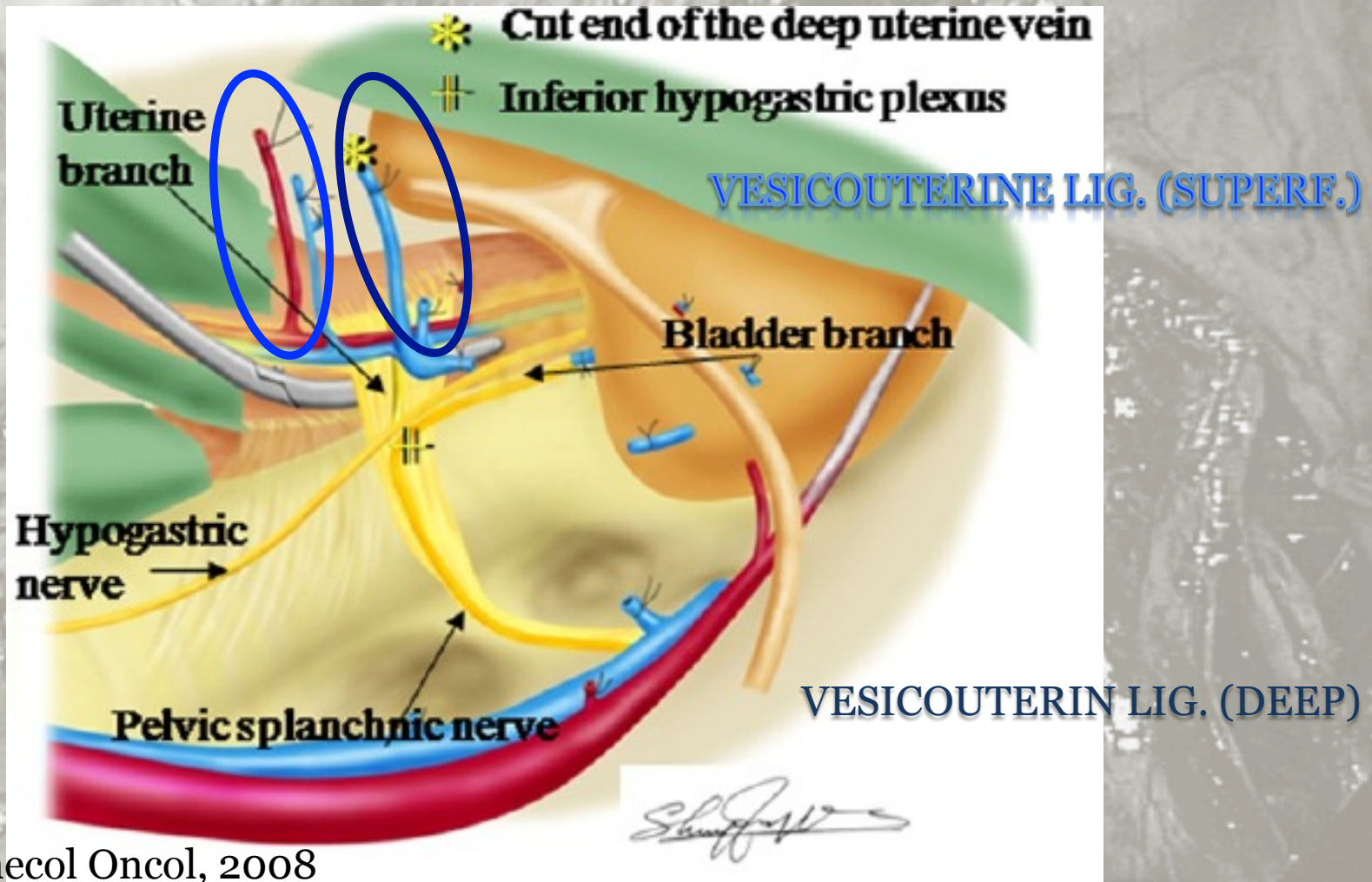
Sacral roots



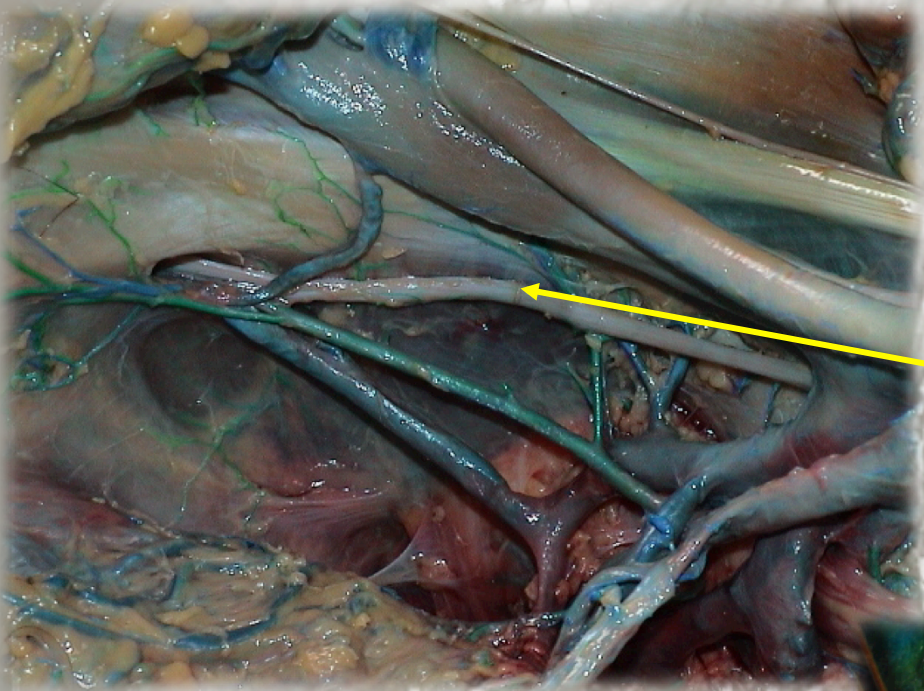
Hypogastric a.

Ercoli et al., Surg
Rad Anat, 2003

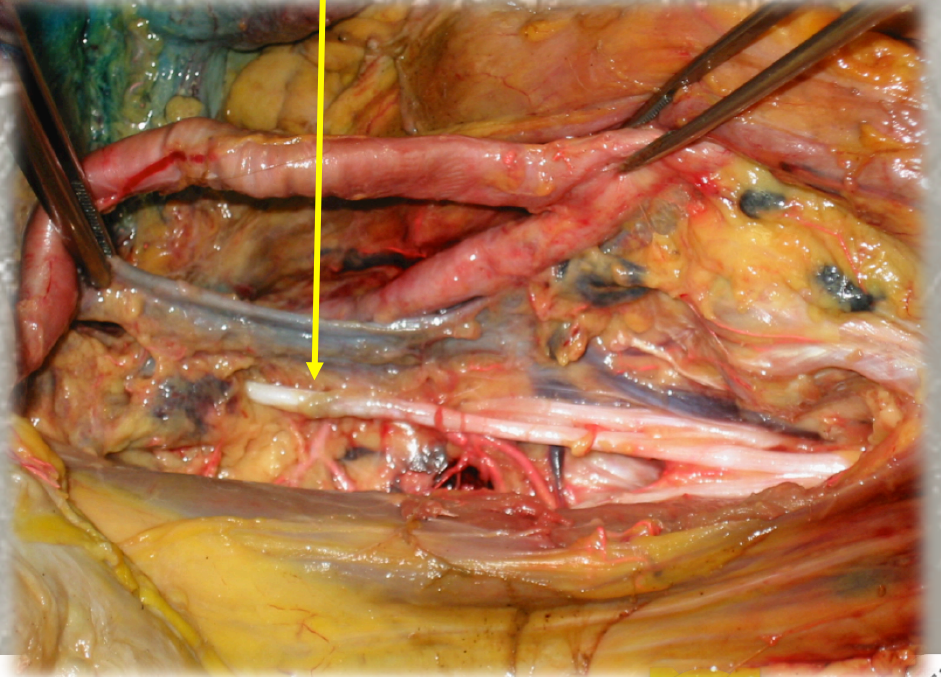
Anatomical landmarks for bladder branches of Hypogastric Plexus



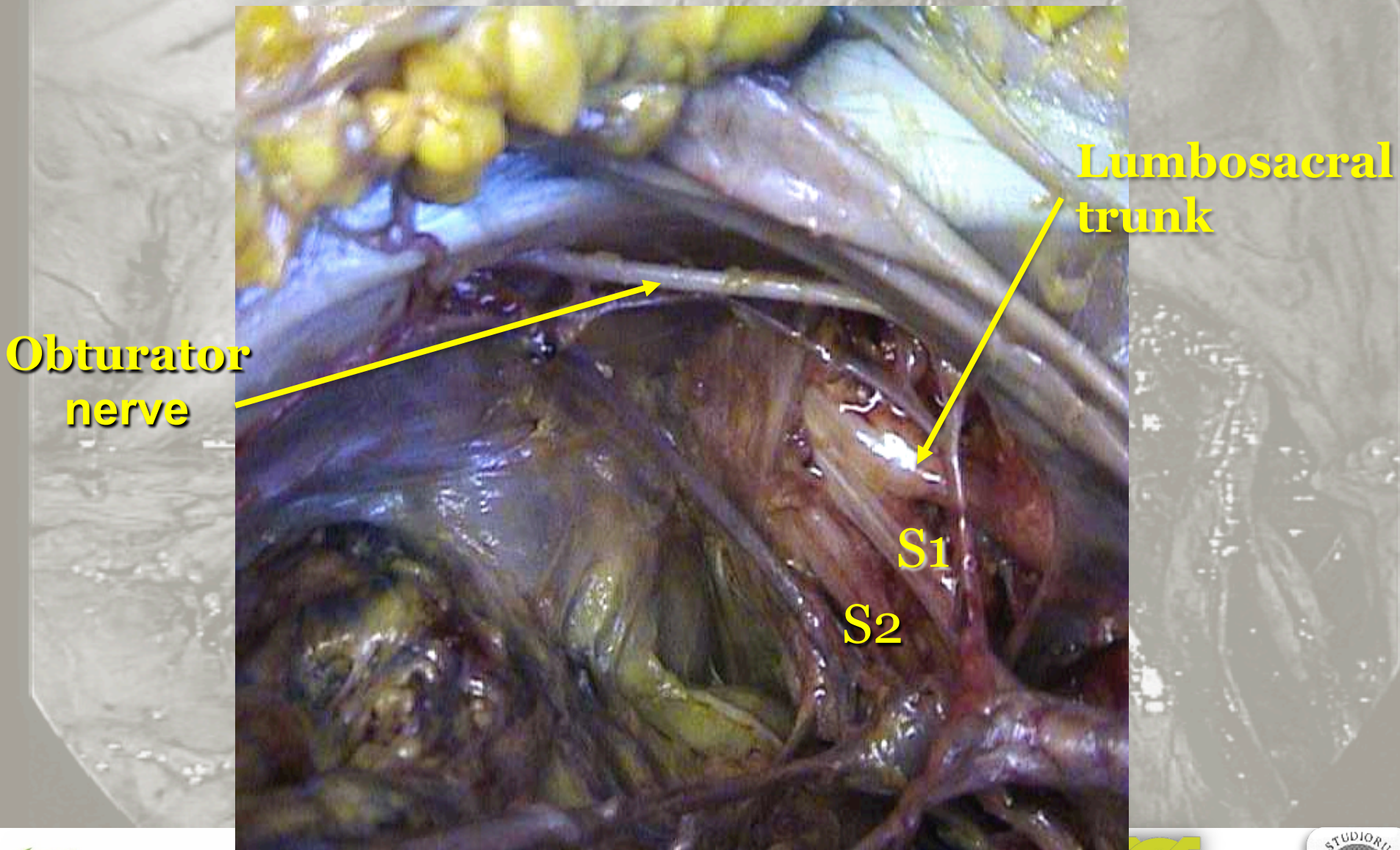
FUJII, Gynecol Oncol, 2008



**Obturator
nerve
(L2-L4)**

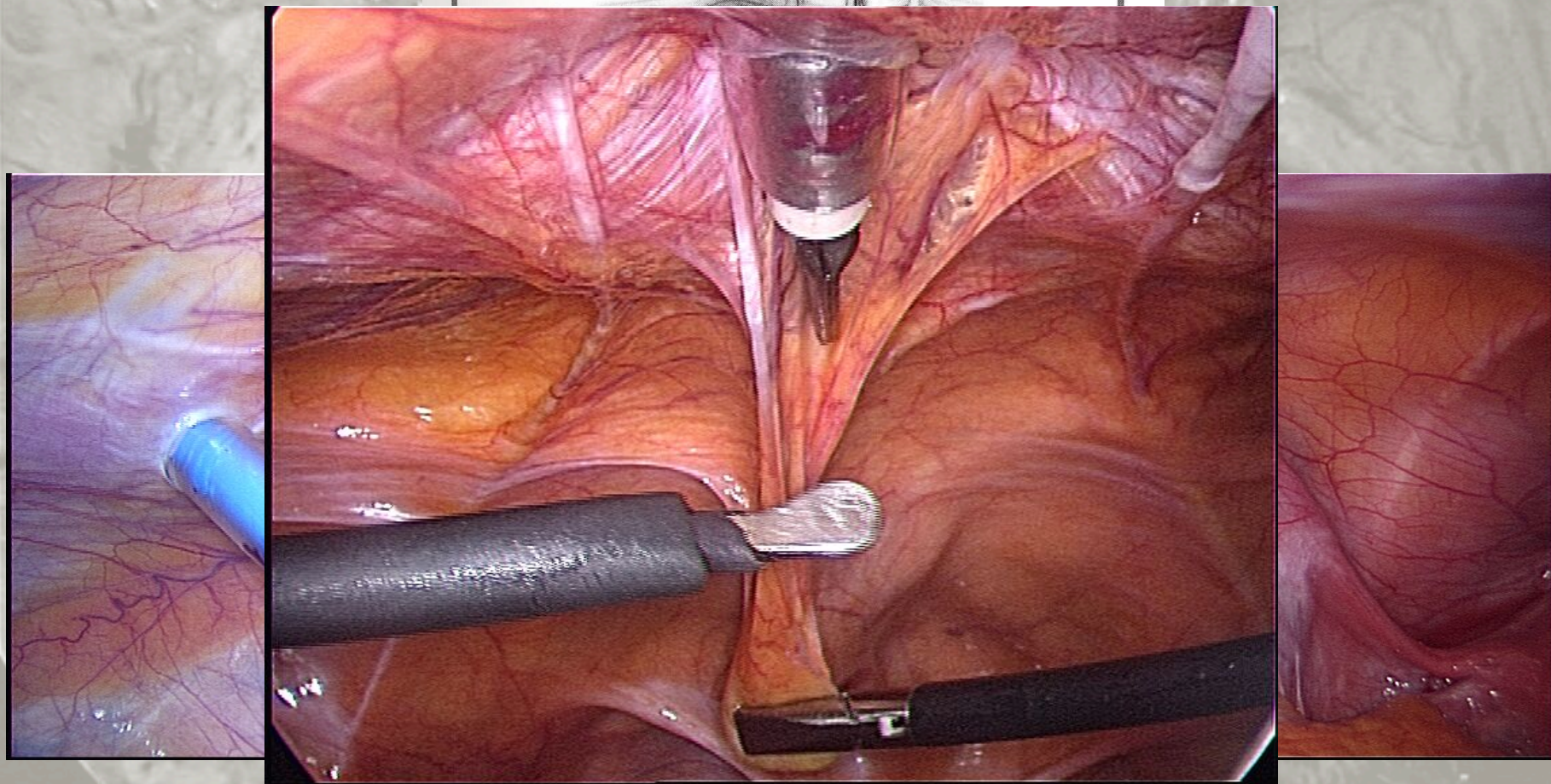


Sacral roots



Operative Anatomy *anterior abdominal wall*

Courtesy Abri de Bruin



Pelvic Retroperitoneum

Between the parietal peritoneum and the parietal pelvic fascia

Connective space crossed by:

pelvic ureter, visceral vessels and nerves

Space organized in three kind of functional structures:

visceral ligaments, collagen free visceral surfaces, visceral pelvic fascia

Great surgical and functional importance

endometriosis surgery, oncology, uro-gynaecology

Right Paravesical Fossa

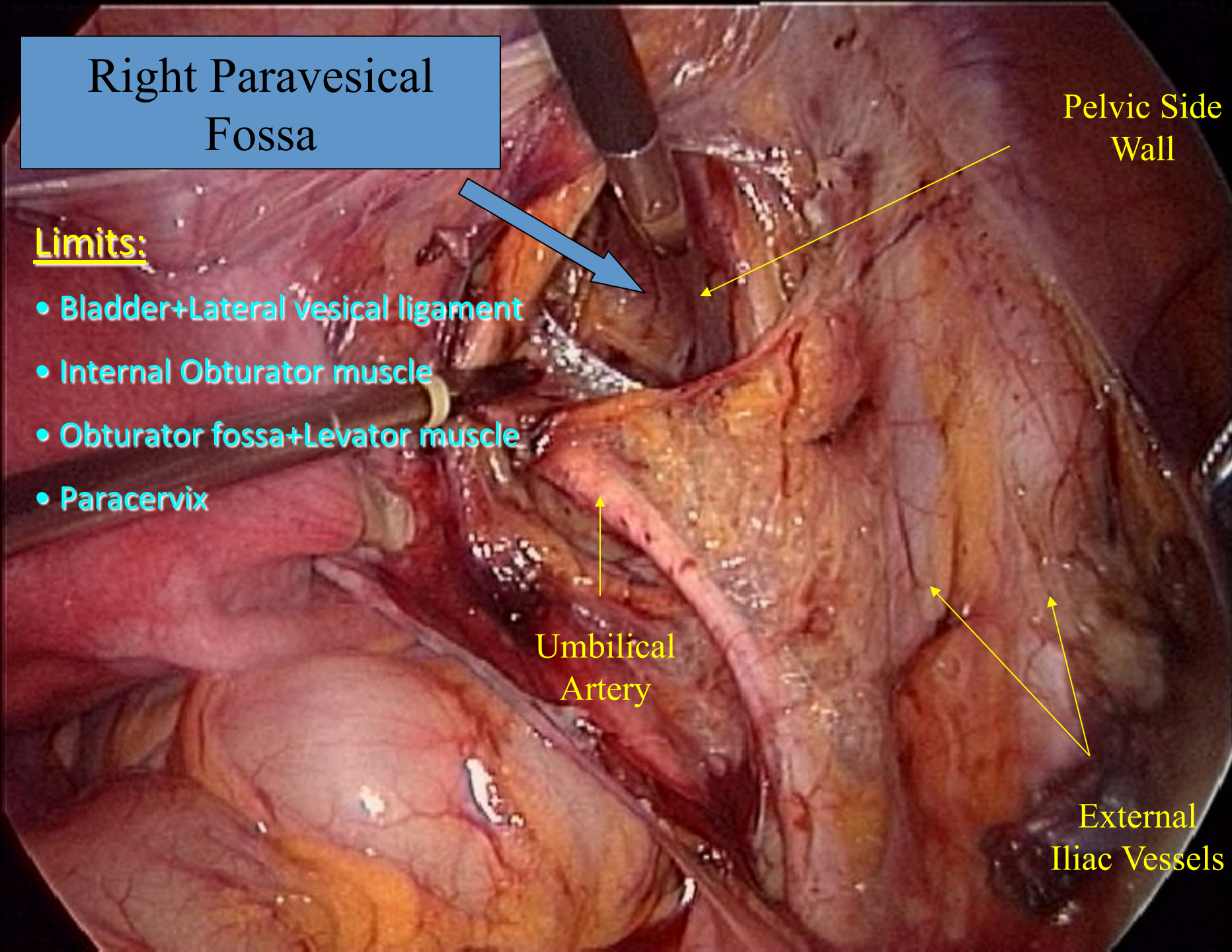
Limits:

- Bladder+Lateral vesical ligament
- Internal Obturator muscle
- Obturator fossa+Levator muscle
- Paracervix

Pelvic Side Wall

Umbilical Artery

External Iliac Vessels



Pelvic Lymphadenectomy
right side

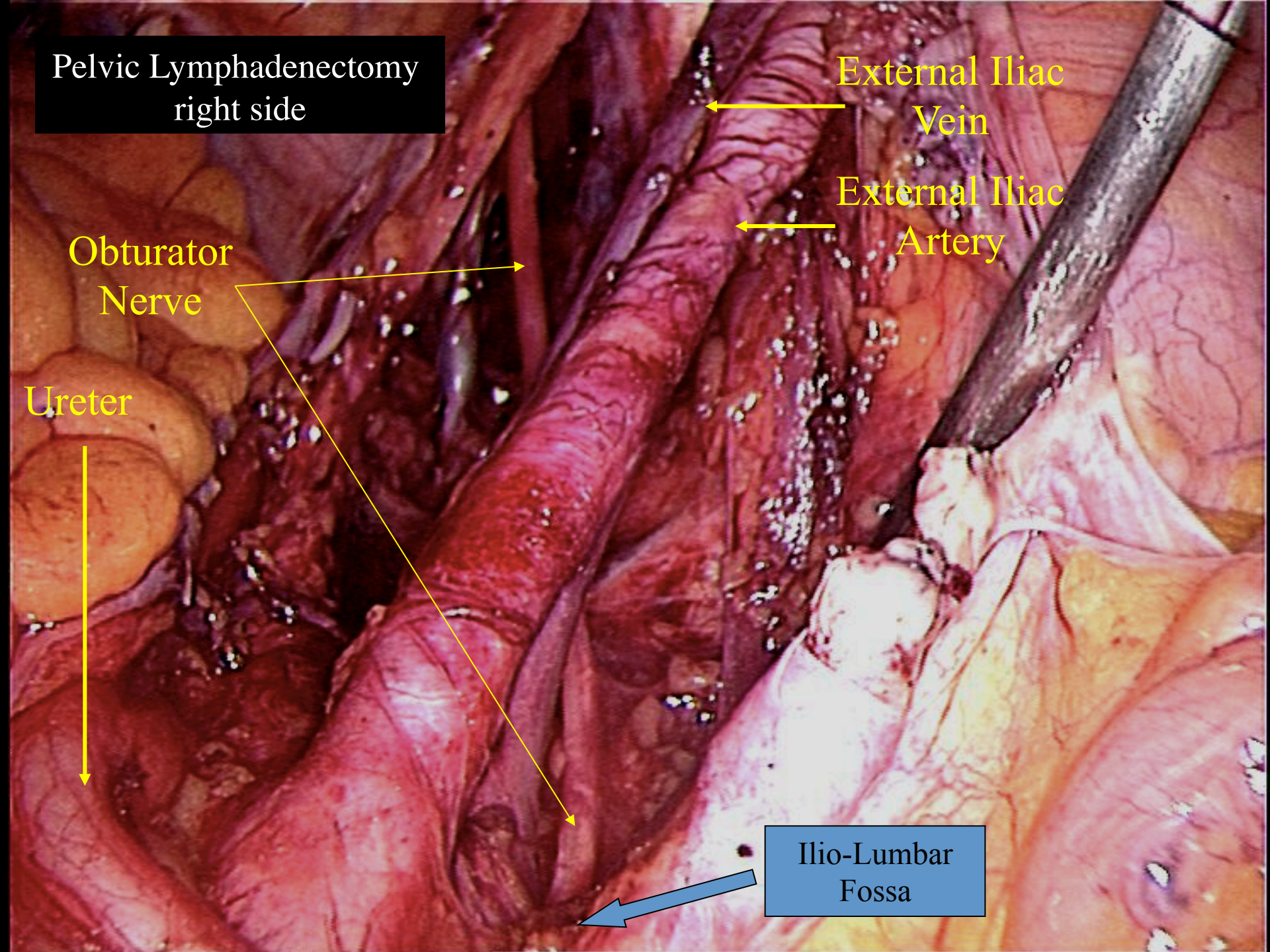
External Iliac
Vein

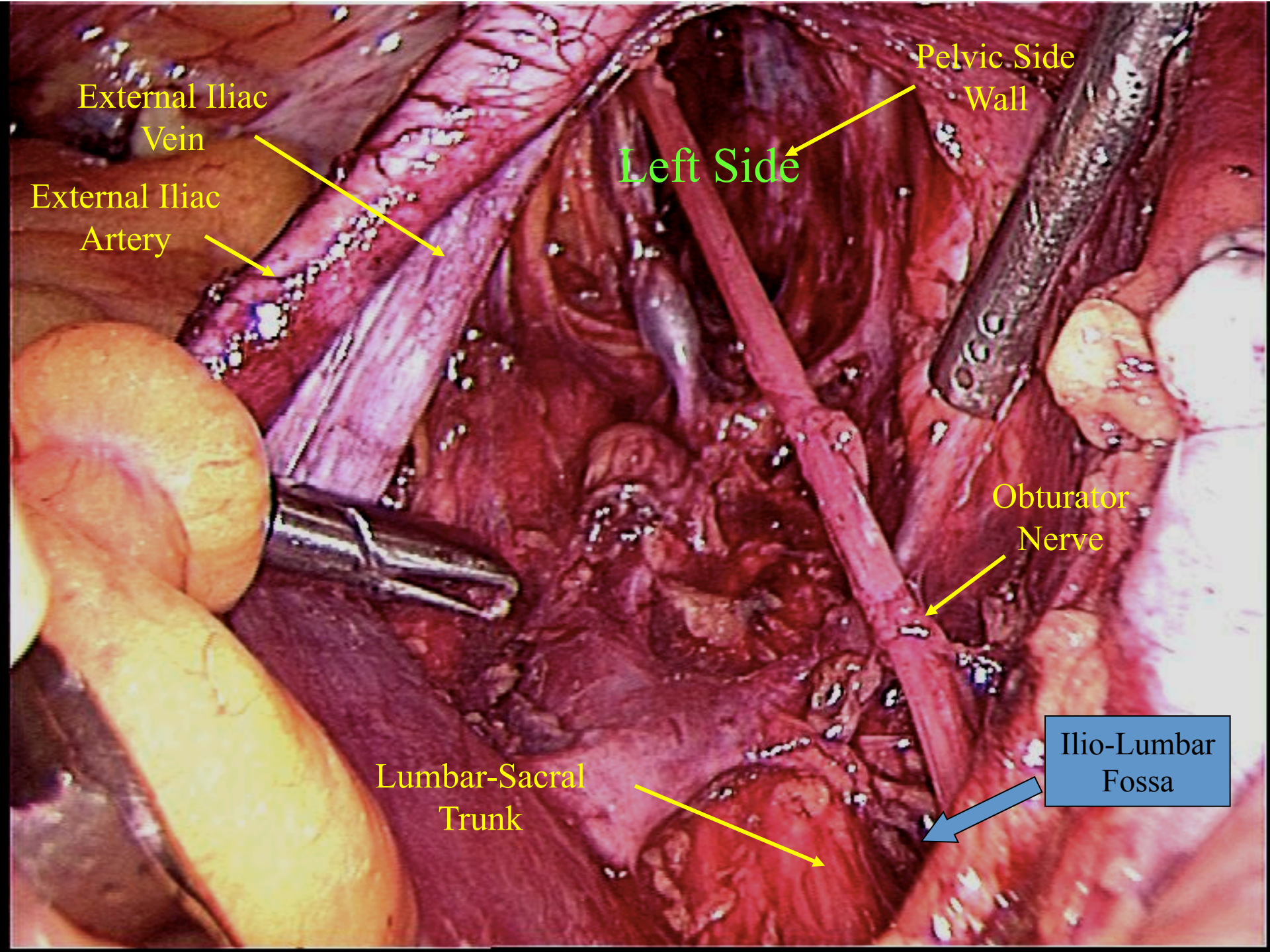
External Iliac
Artery

Obturator
Nerve

Ureter

Ilio-Lumbar
Fossa





External Iiac
Vein

External Iiac
Artery

Pelvic Side
Wall

Left Side

Obturator
Nerve

Lumbar-Sacral
Trunk

Ilio-Lumbar
Fossa

Right Pararectal Fossa

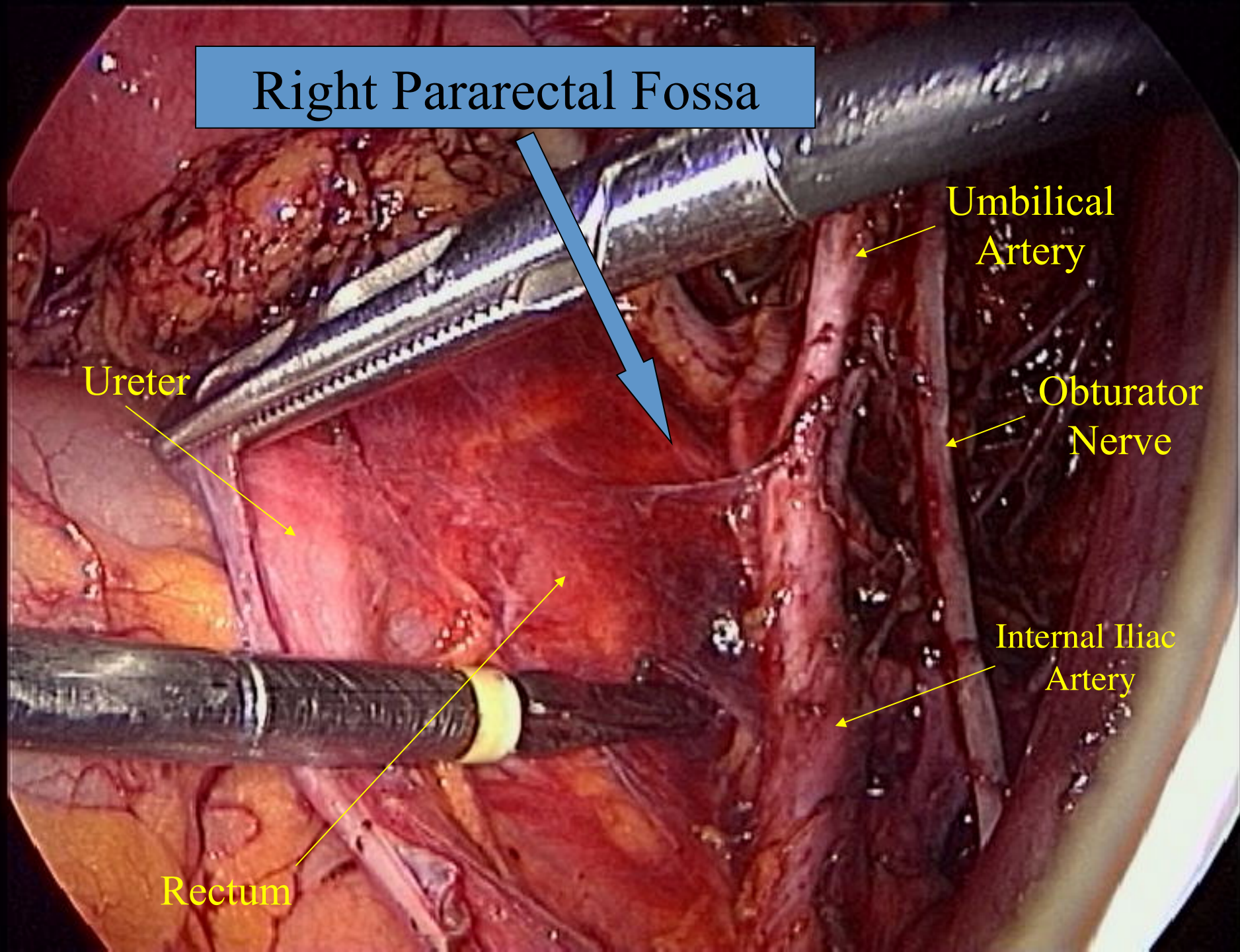
Umbilical
Artery

Ureter

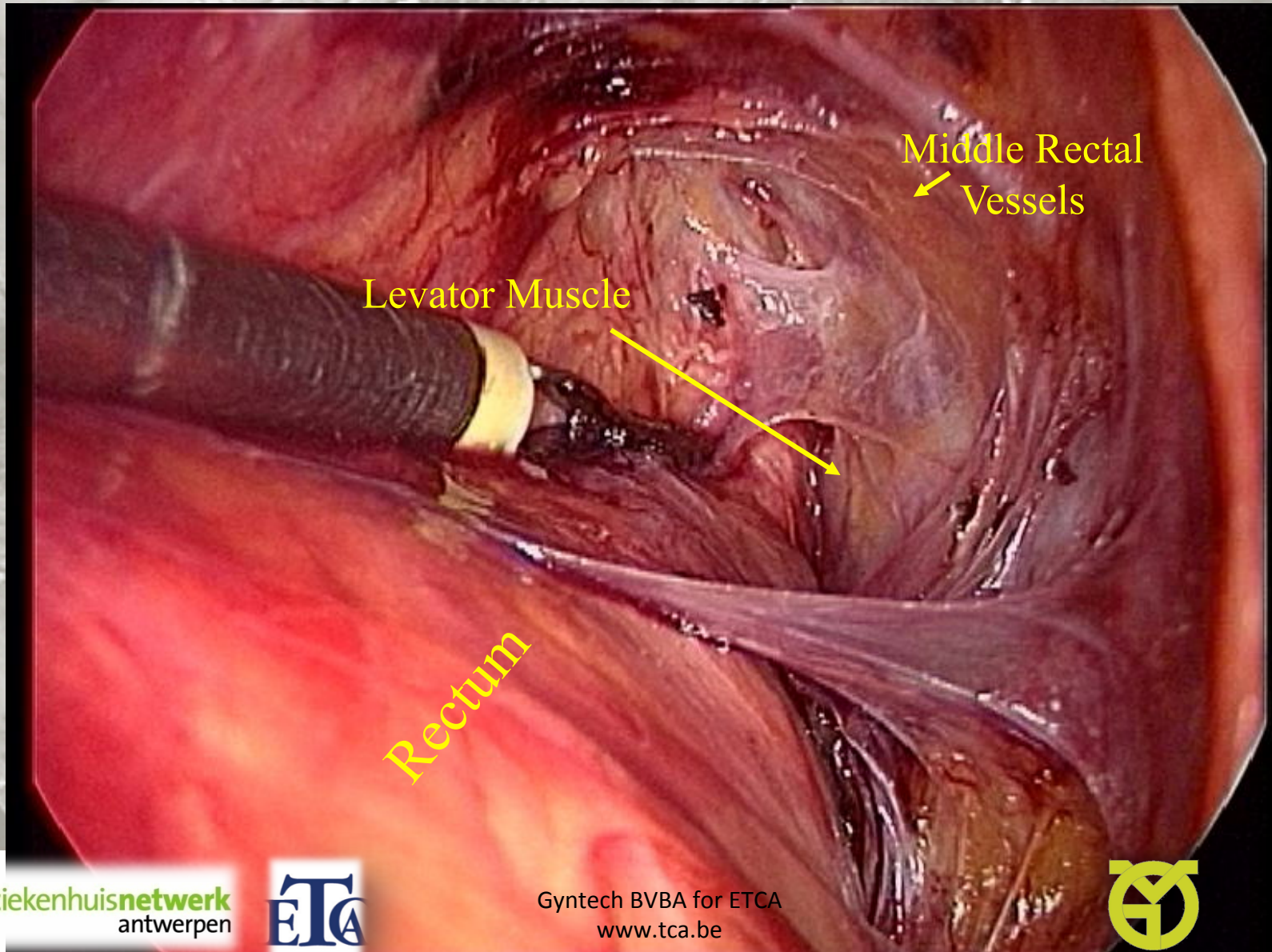
Obturator
Nerve

Internal Iliac
Artery

Rectum



Opening the pararectal fossa



Middle Rectal Vessels



Limits:

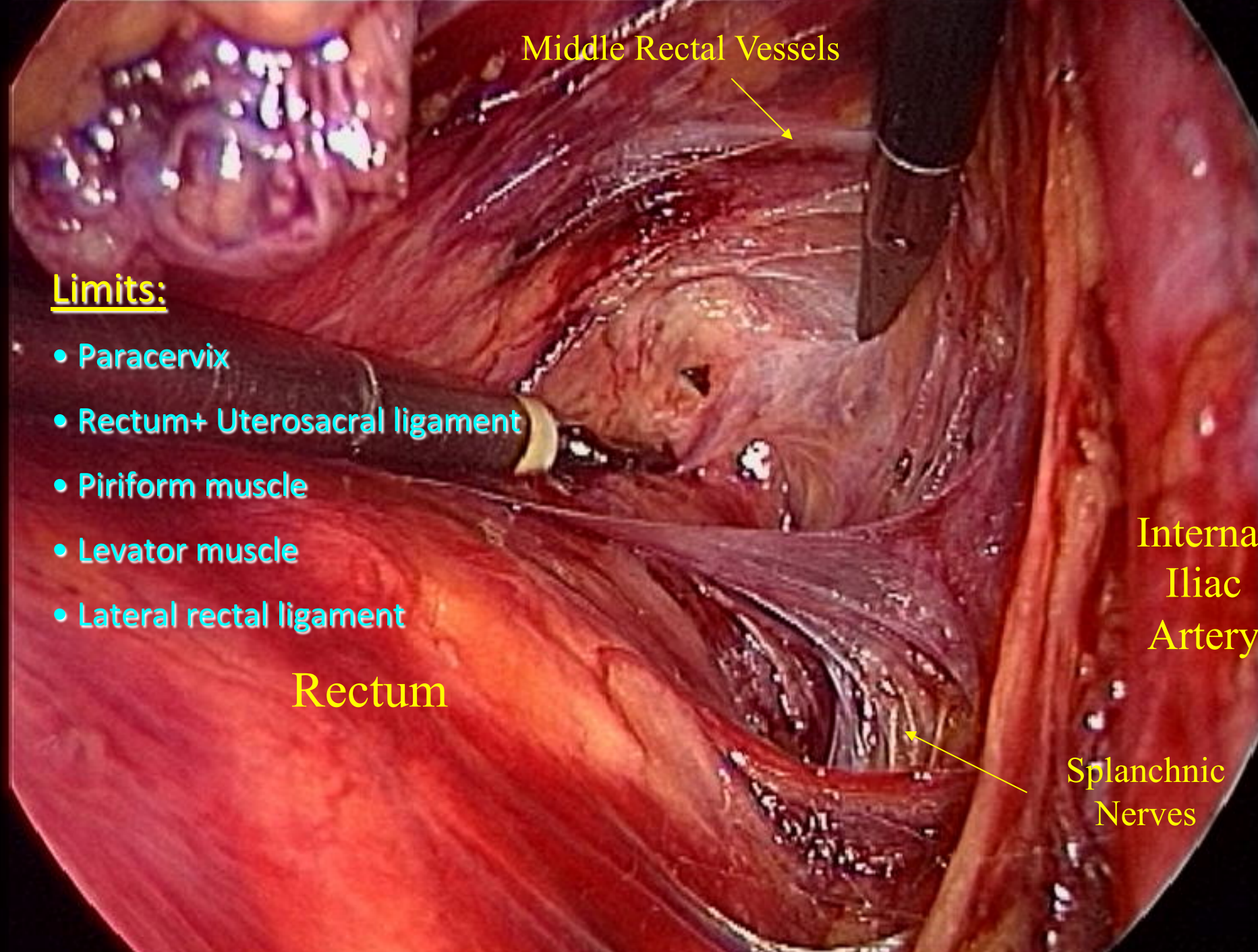
- Paracervix
- Rectum+ Uterosacral ligament
- Piriform muscle
- Levator muscle
- Lateral rectal ligament

Rectum

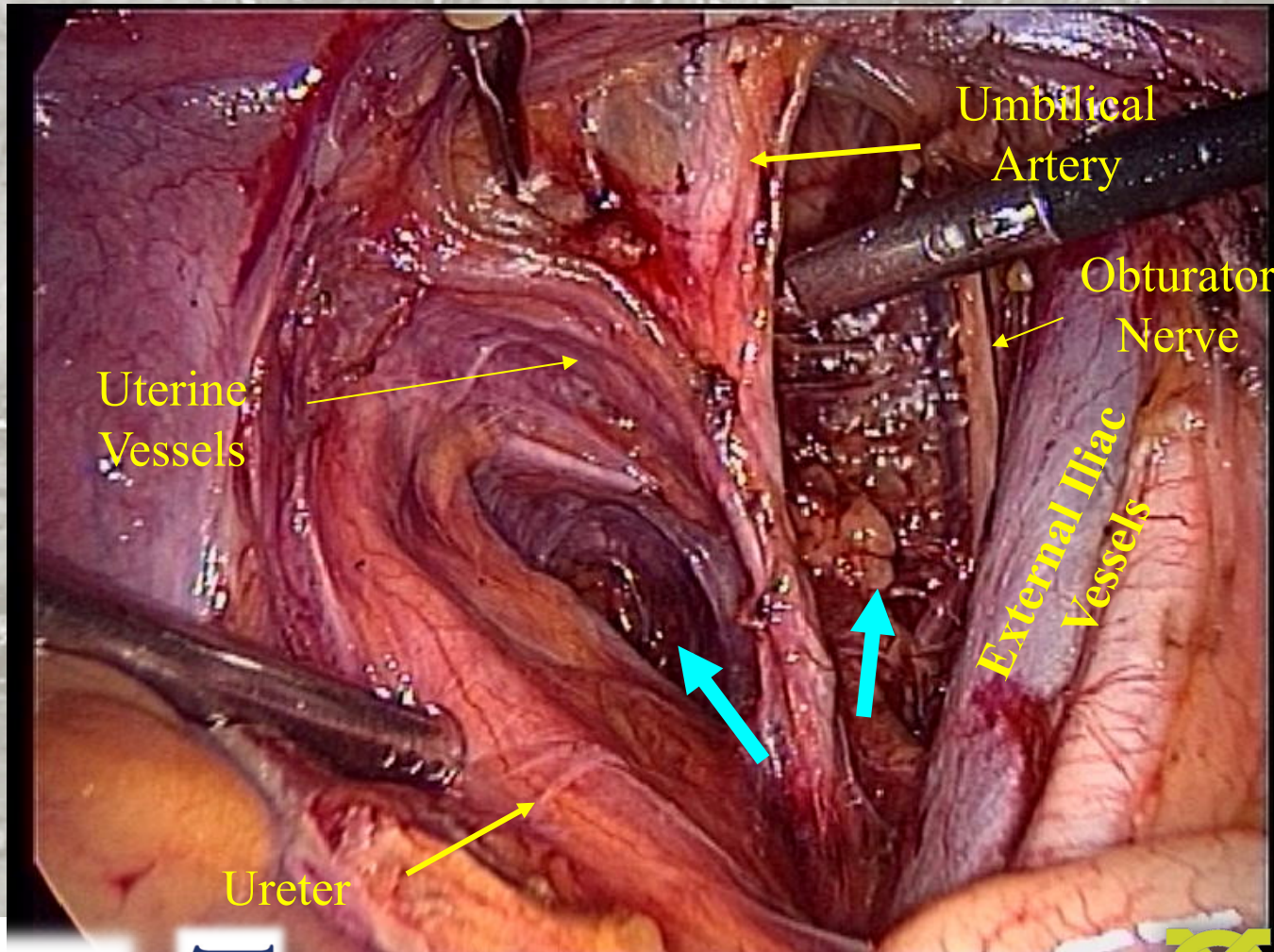
Internal Iliac Artery

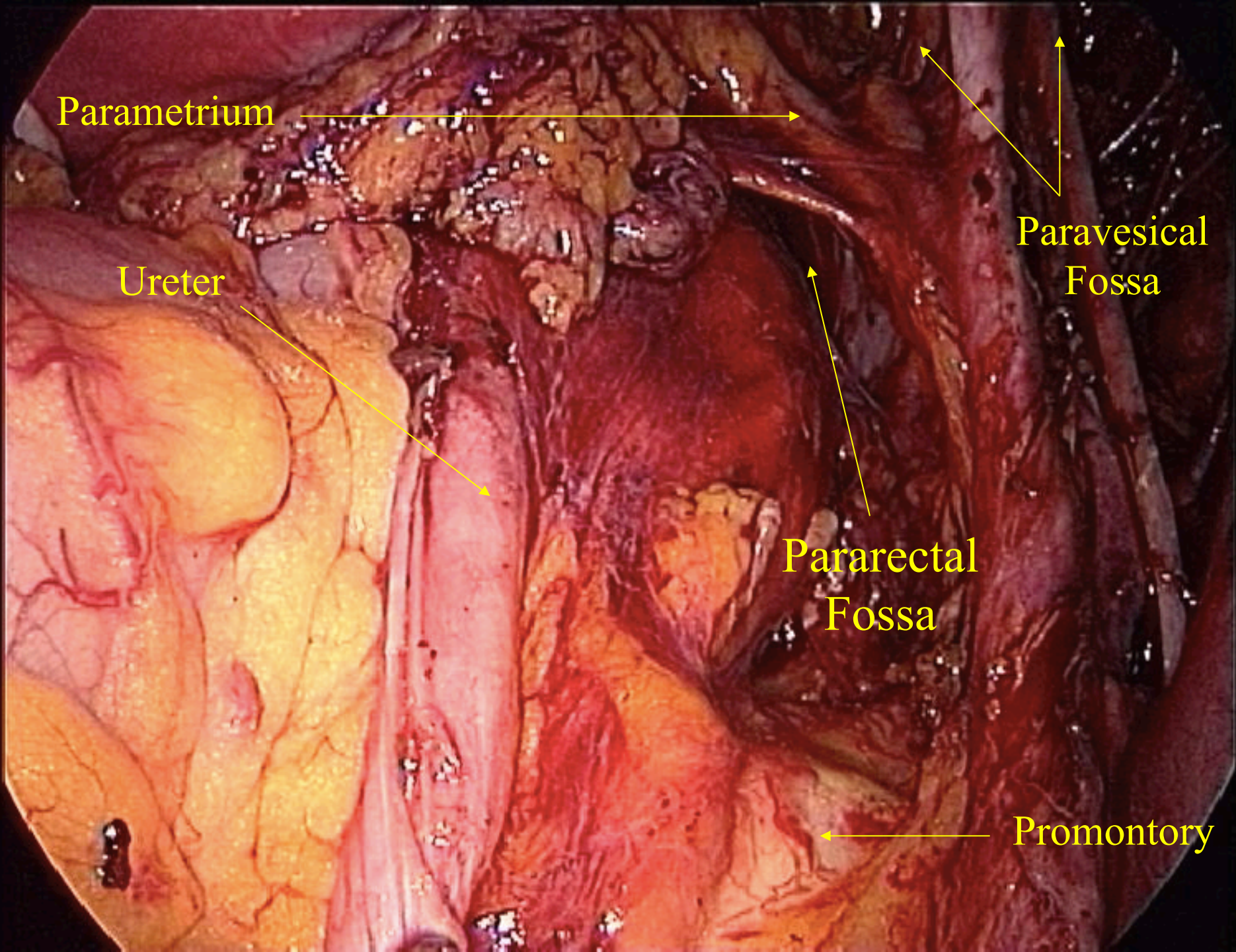


Splanchnic Nerves



Paravesical, pararectal spaces right side





Parametrium

Ureter

Paravesical
Fossa

Pararectal
Fossa

Promontory

R. Paravesical Fossa

Right Ureter

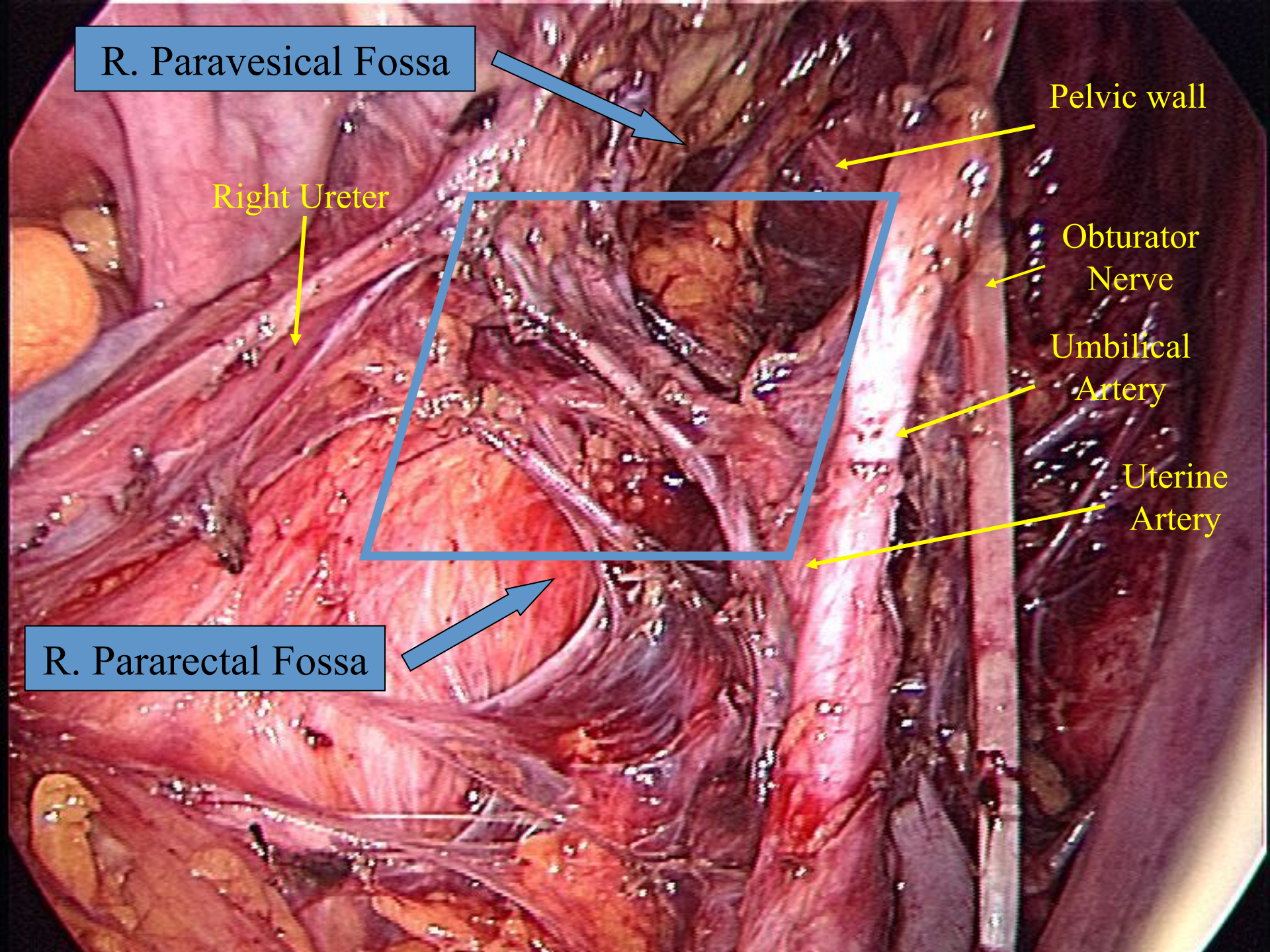
Pelvic wall

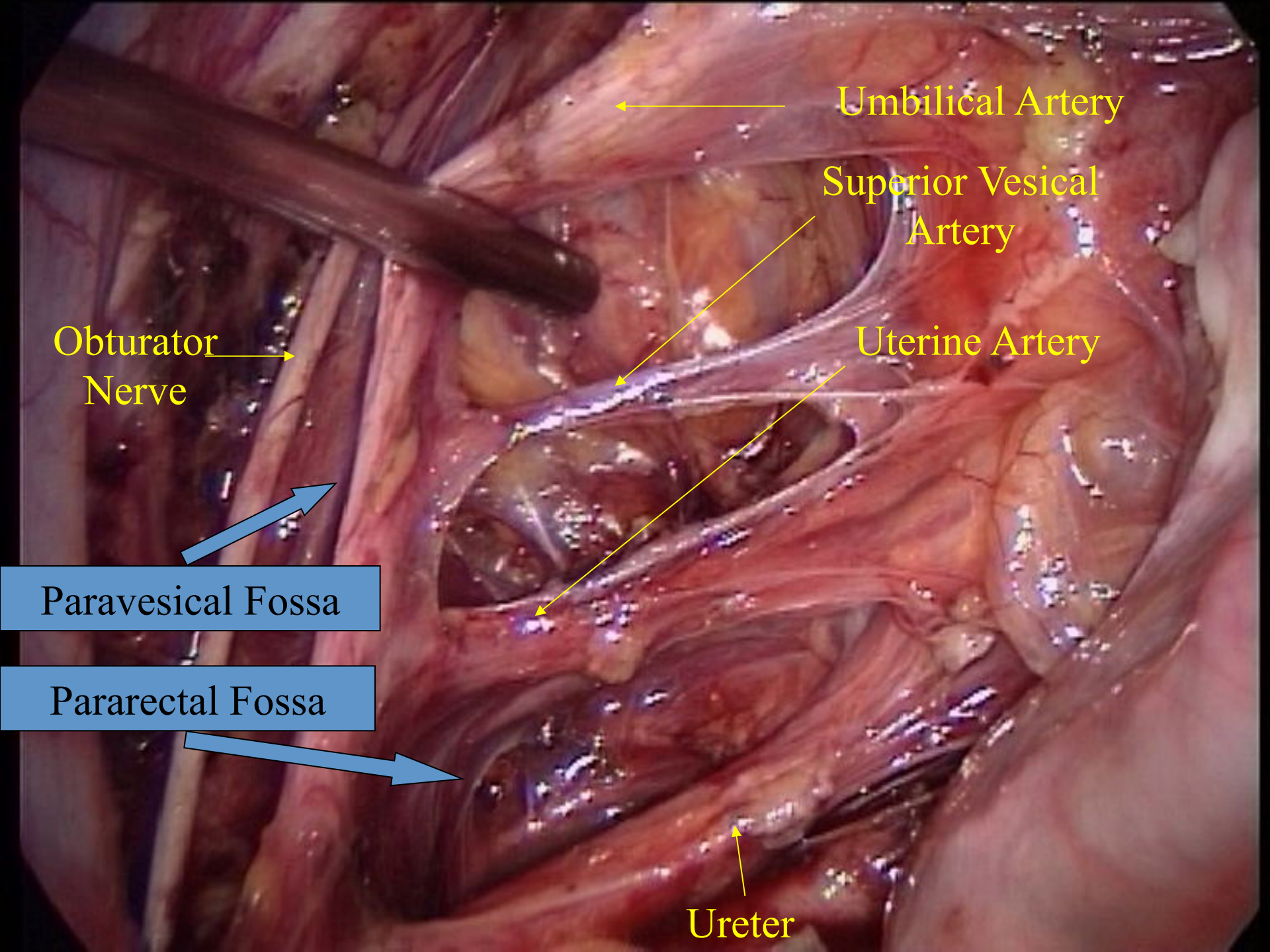
Obturator
Nerve

Umbilical
Artery

Uterine
Artery

R. Pararectal Fossa





Umbilical Artery

Superior Vesical Artery

Uterine Artery

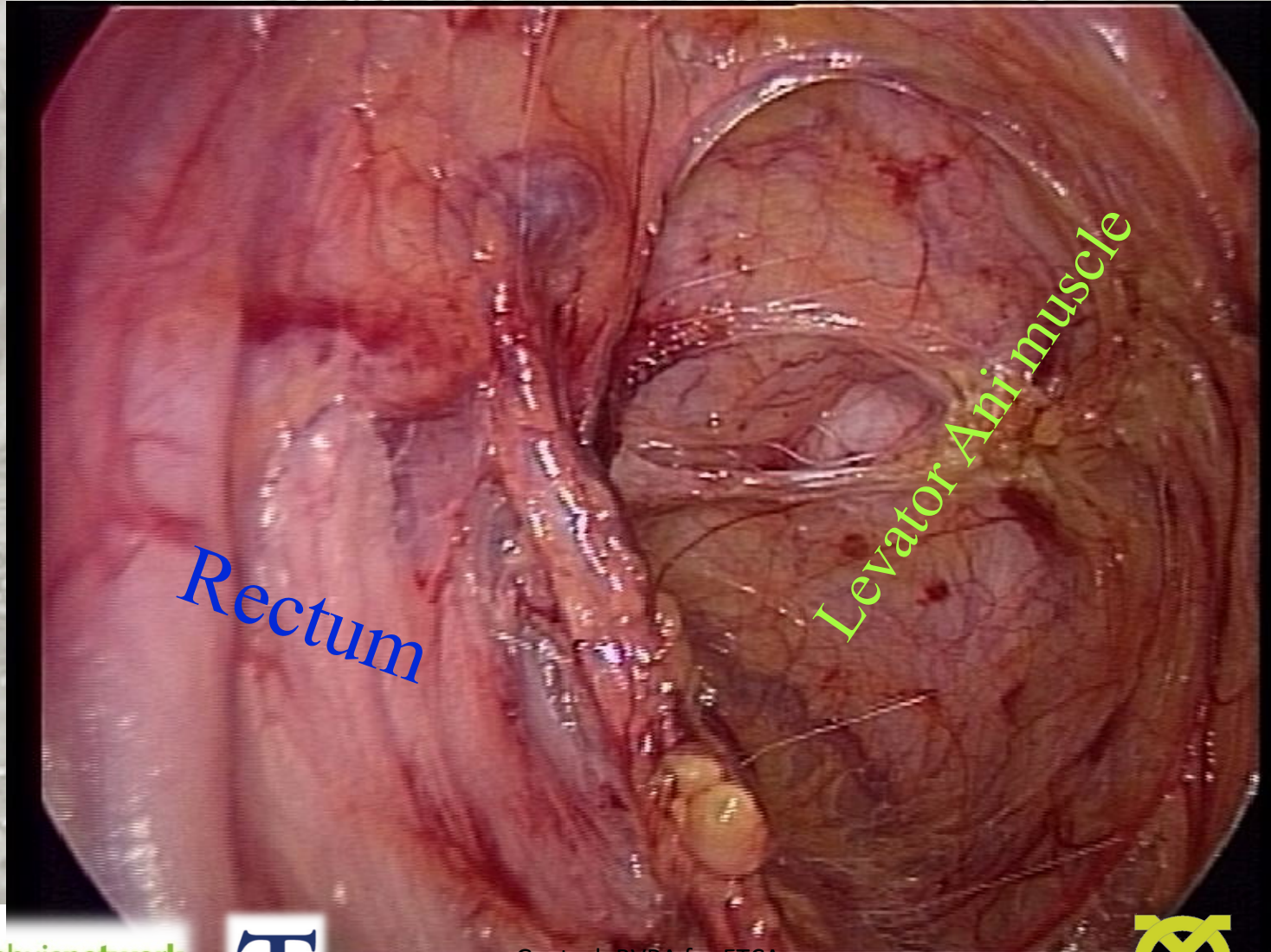
Obturator Nerve

Paravesical Fossa

Pararectal Fossa

Ureter

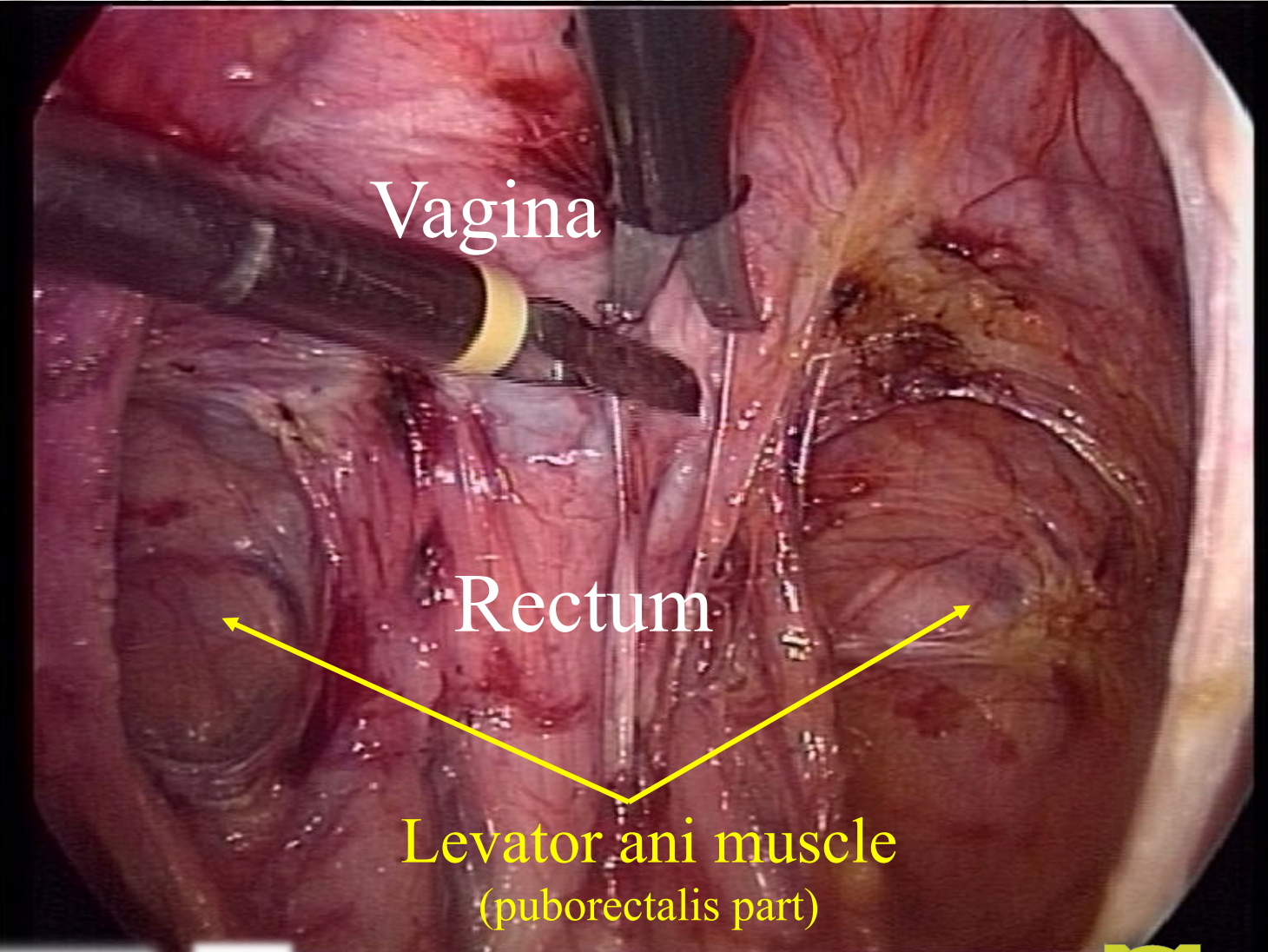
Rectovaginal space



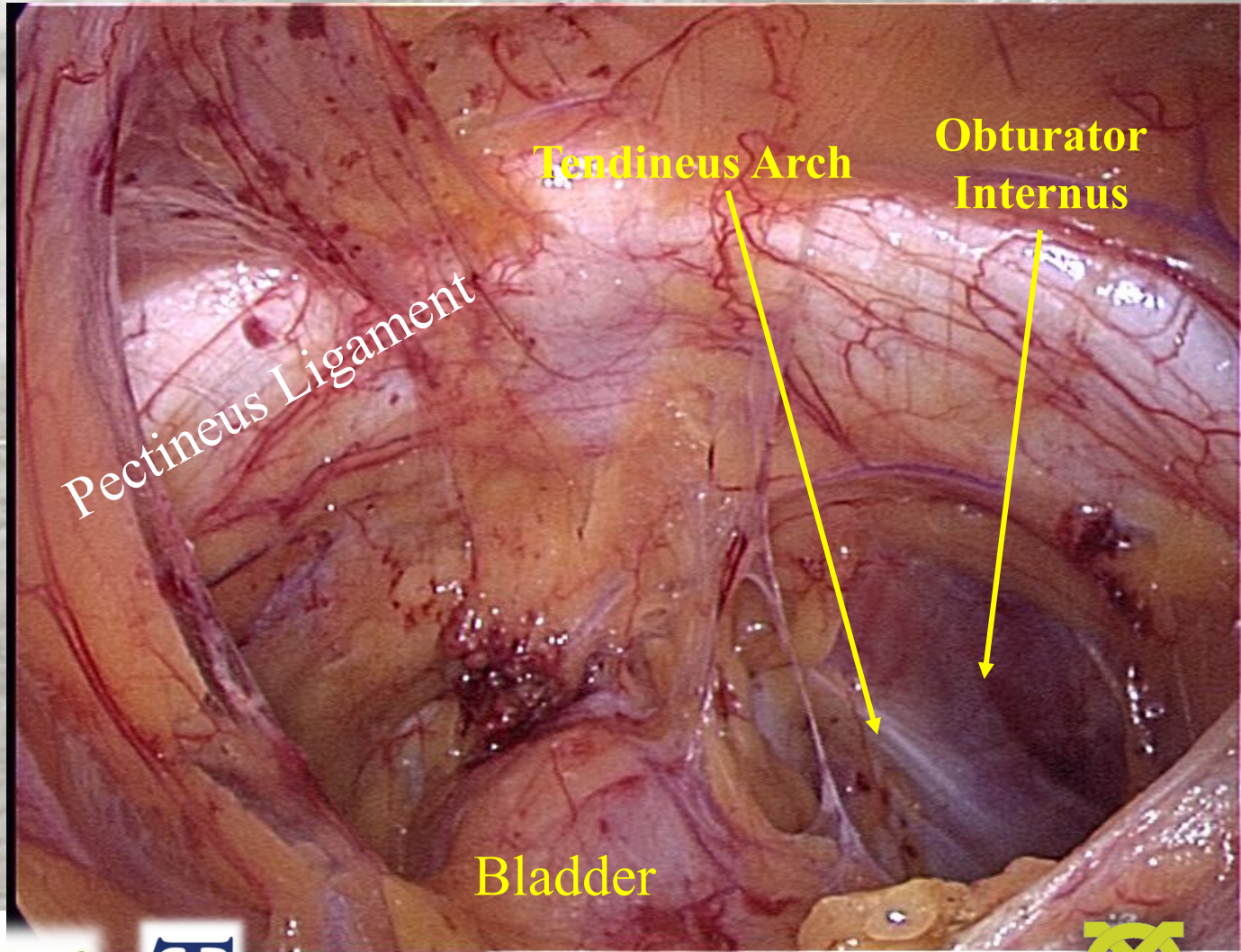
Rectum

Levator Ani muscle

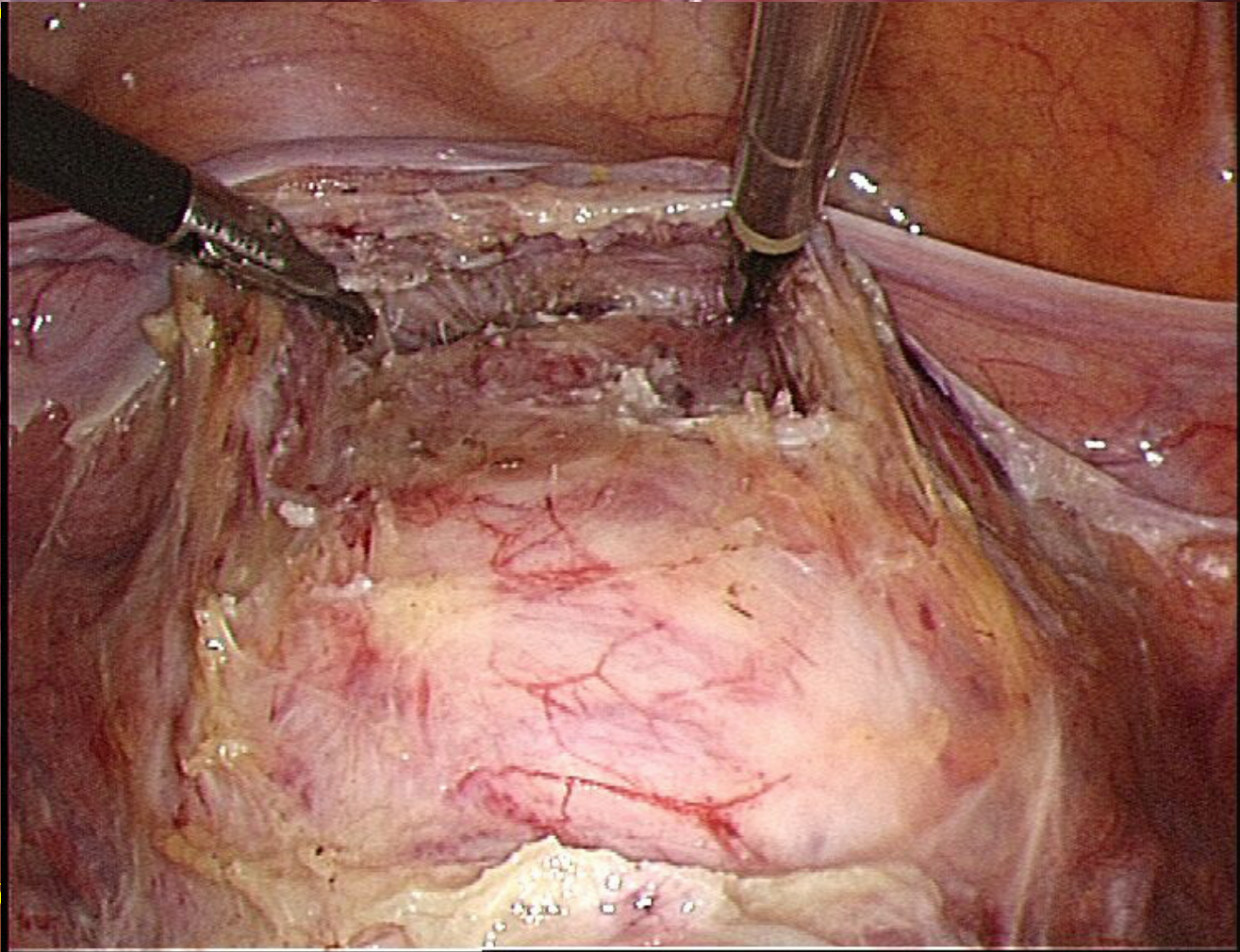
Rectovaginal space



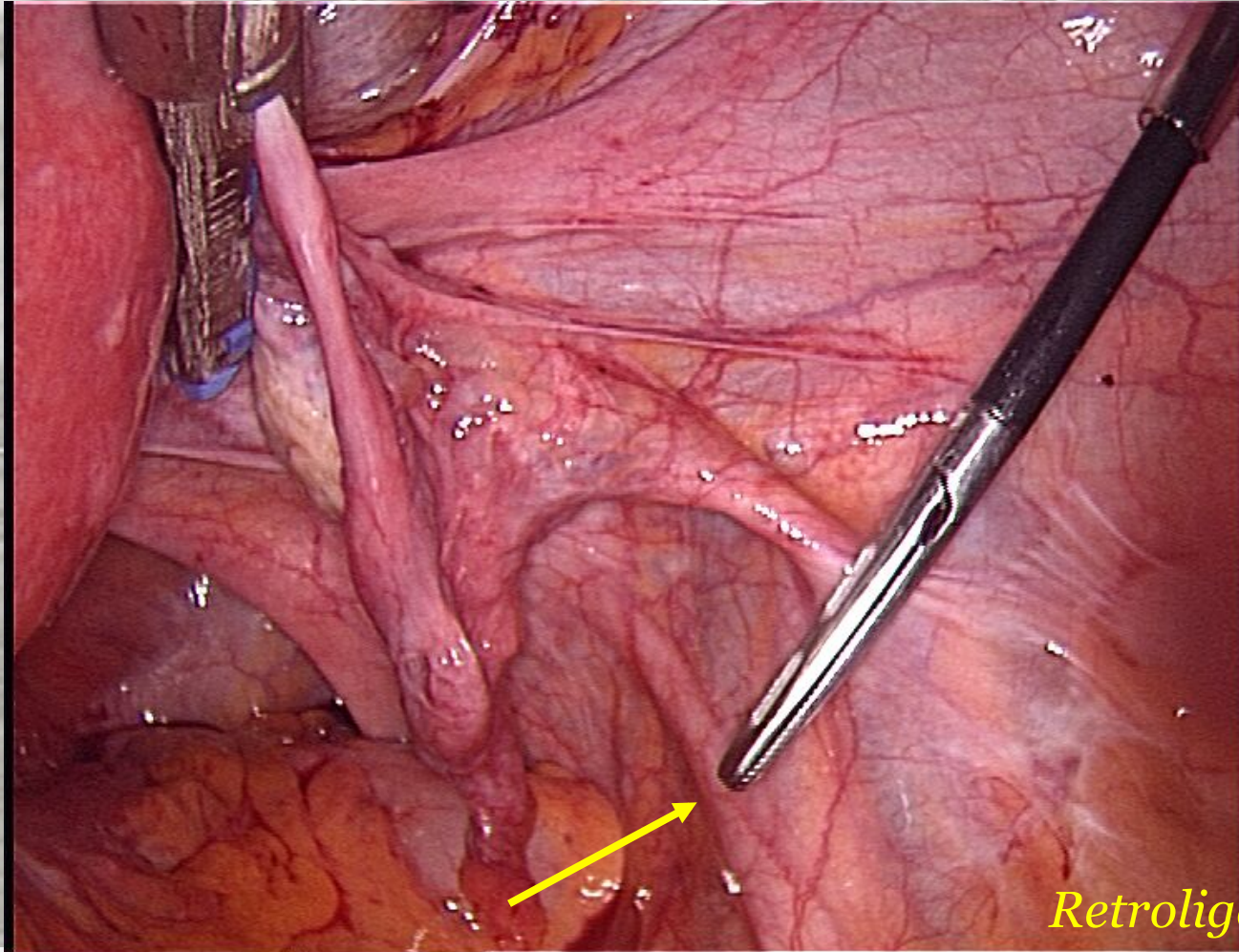
Retropubic space



Bladder



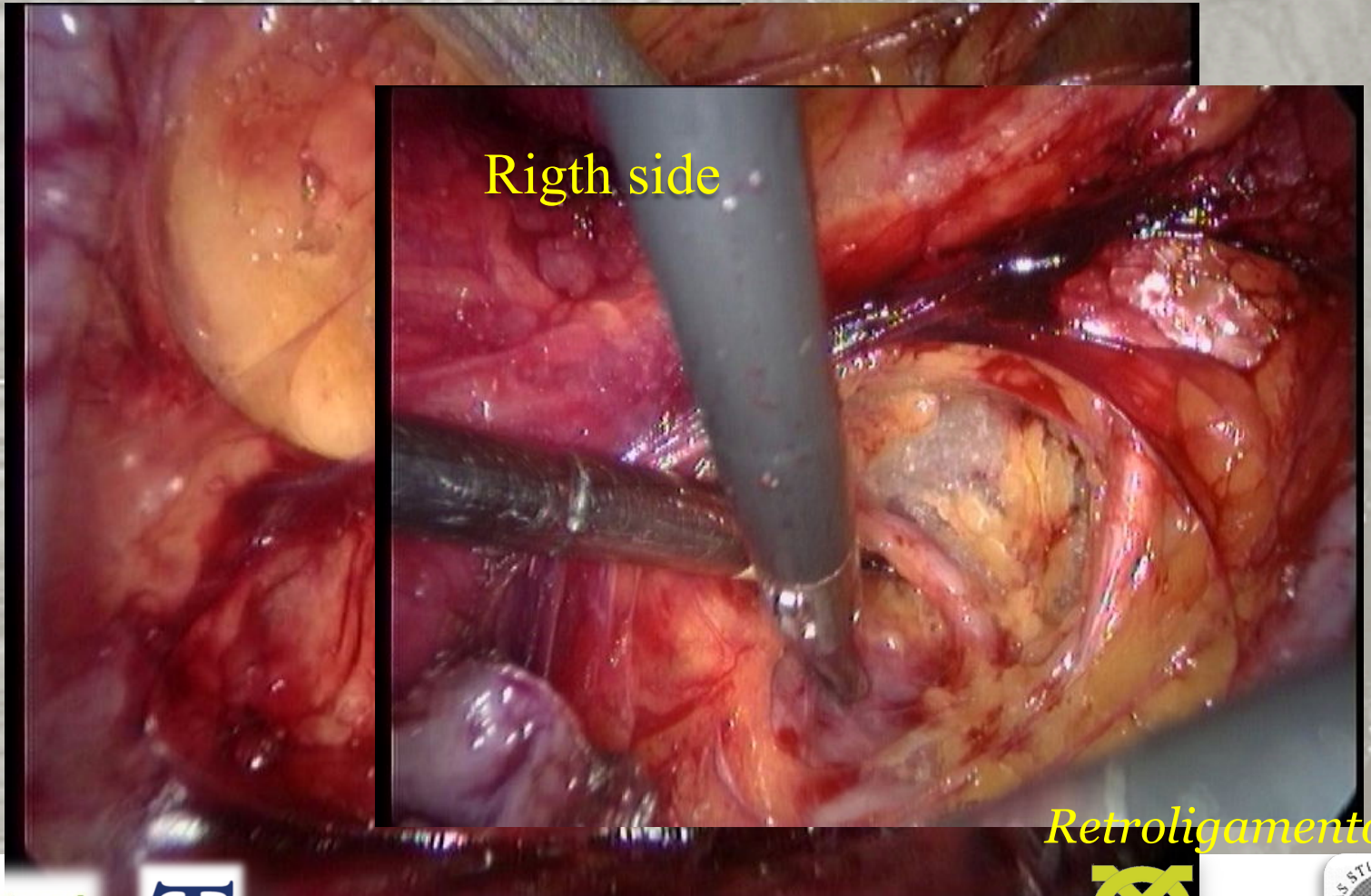
Pelvic ureter dissection *retroligamentary, intraligamentary, retrovesical*



Retroligamentary

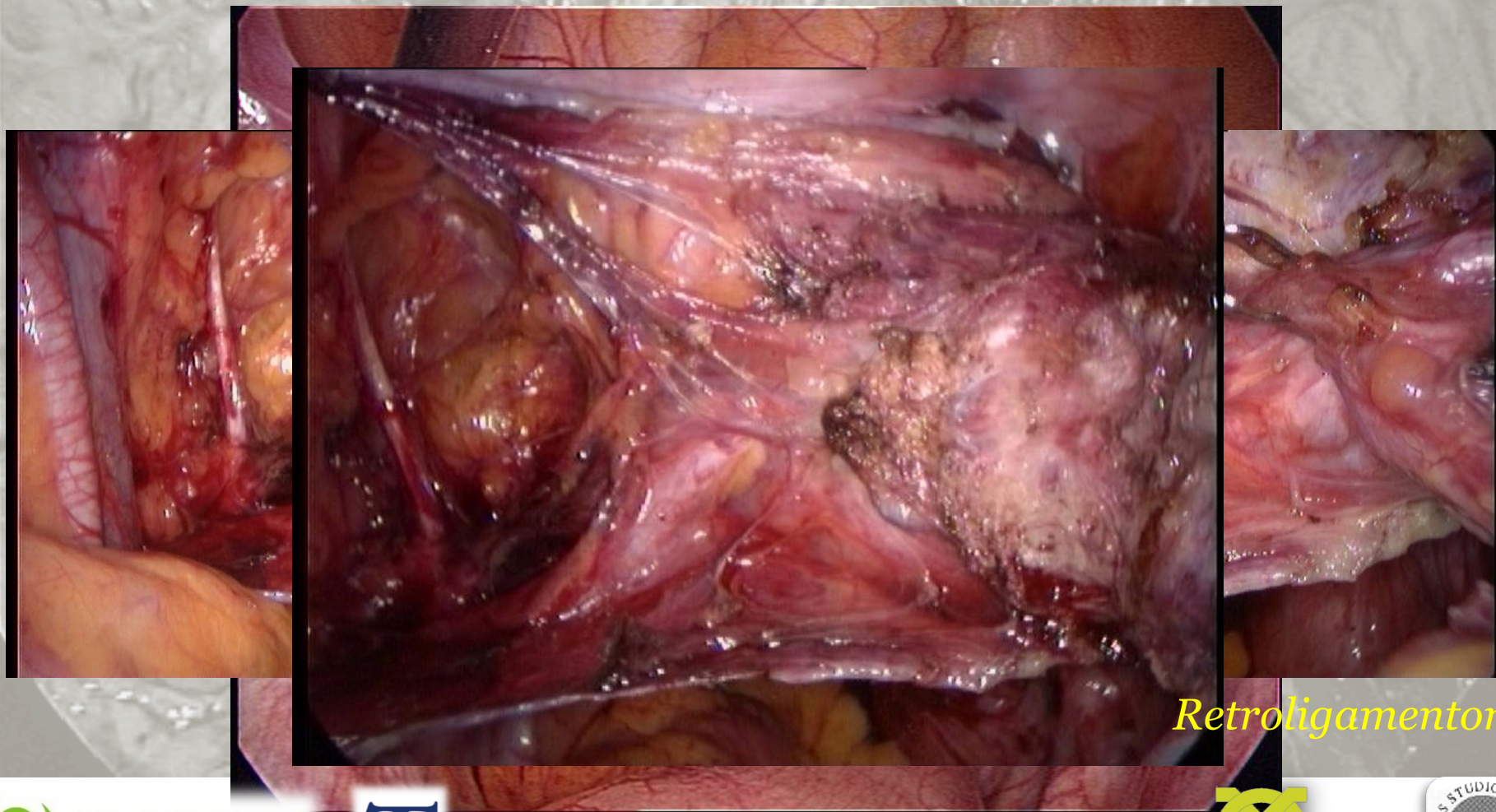
Pelvic ureter dissection

left side



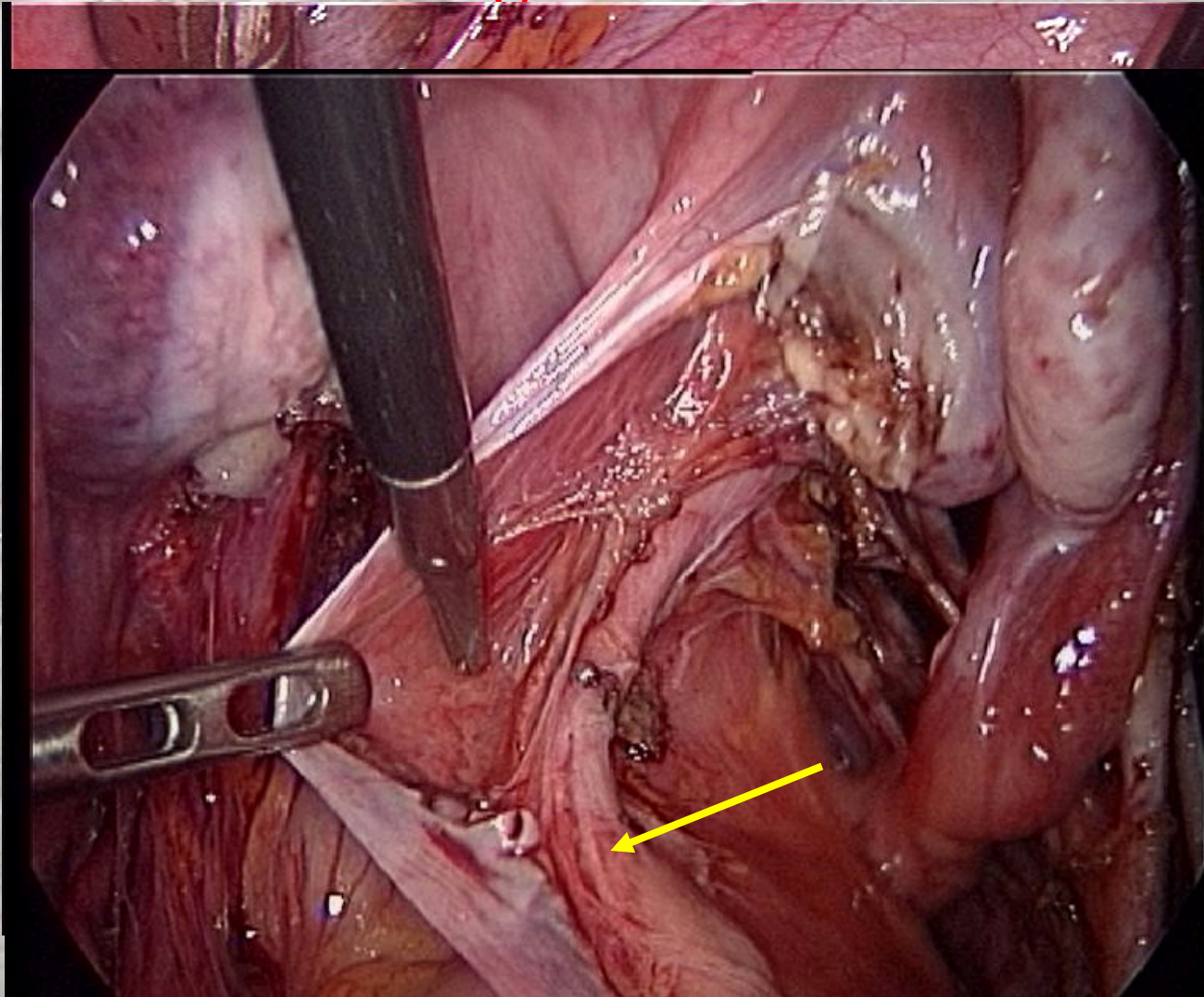
Retroligamentory

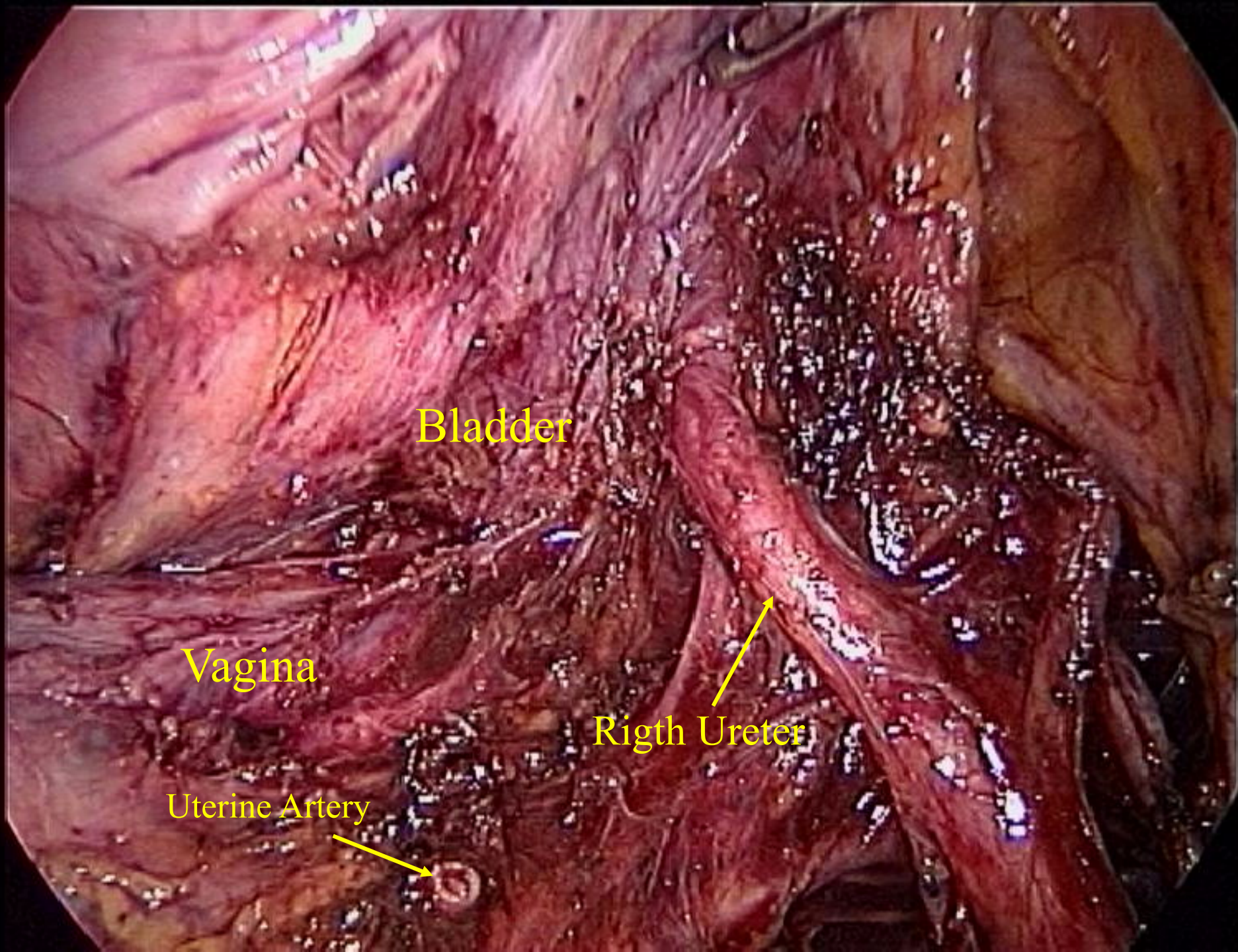
Pelvic ureter and laparoscopic hysterectomy left side



Retroligamentary

Pelvic ureter dissection right side





Bladder

Vagina

Rigth Ureter

Uterine Artery

Thank
You
for
Your Attention

