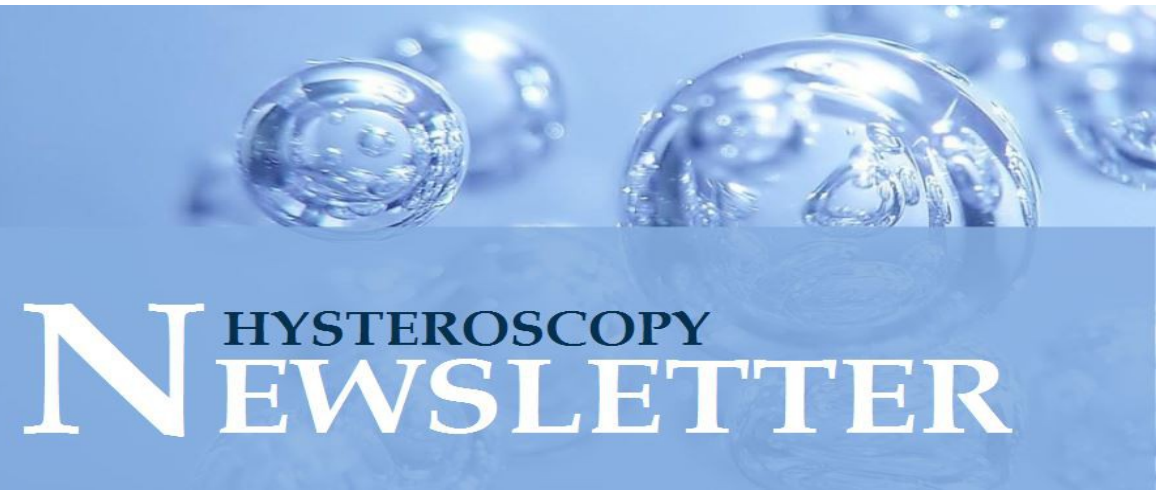



NHYSTEROSCOPY NEWSLETTER

During the last couple of decades, we can say that the field of hysteroscopy has been “reborn”, with the renowned scientists who made it a dedicated subspeciality and the emerging of new amazing technologies. But, as a gynecologist working in the area of Middle East and Africa, there is a significant delay in adopting such major medical changes.

Despite the relatively small percentage of gynecologists practicing hysteroscope professionally, hand skills are not the main obstacle against spreading the hysteroscopy practice in the Middle east / Africa. The major obstacle is the “culture” among gynecologists that underestimate the value of “intrauterine see and treat” concept in their practice, and a common attitude towards hysteroscopy as a “last option” of management rather than a routine handy procedure. This is further augmented by old-school teachers whose main evidence is “we have been always doing it without a hysteroscope” .

The second obstacle is the high initial cost of setting up a hysteroscopy unit, along with different devices and instruments. A cost-effective equation will only be positive by raising the procedure cost, an act that will increase the gap we are trying to fill. Fortunately, newer generations of gynecologists are eager to learn and practice new delicate procedures, and are more flexible to adopt the evidence based practices and their always-changing updates.

Since my early beginnings in this field, my view to spread hysteroscopy was to emphasize its “simple, safe and smart” characteristics of practice. At a certain level of simplicity and safety, hysteroscopy will overcome the challenges of culture and depates, and acquire an attitude similar to the ultrasound machines in our clinics, which we literally start to use before thinking of a real indication. With assistance of interested colleagues, we developed a basic training program (independent from laparoscopic training) oriented mainly towards role of hysteroscopy, widening its indications, office practice, from setting up a unit up to different hand-skills. We then started to look for “and develop” affordable devices that are suitable for office use. Few companies showed an interest in investing in this area, and today affordable hysteroscopic systems are available for the first time.

This work gained an excellent feedback, and now supporting tens of hysteroscopy units in many countries in the area. Many challenges are today overcome, now patients are aware of procedure, its importance and simplicity. Gynecologists feel more relaxed to refer patients for hysteroscopy if they donot have facilities to perform it on their own. The procedure costs are now reasonable too. More sales for advanced resectoscopes and shavers are being recorded, more researches are being carried out and published, dedicated hysteroscopy units are now not rare and far. We are catching up.

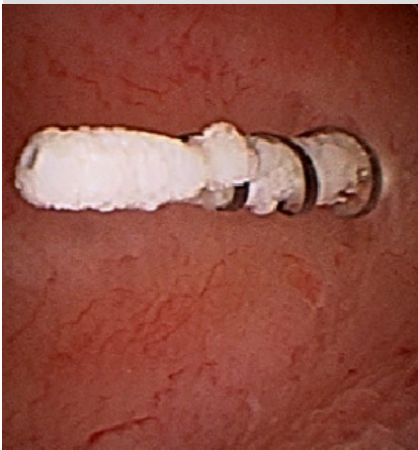Finally, I appreciate all help I am getting from the international community of scientists in this field and proud to be accepted as a junior member among you all. Much thanks goes to the great heroes behind connecting all interested gynecologists with each other.

Mounir M Khalil

Endoscopy trainer, Arab Society of Fetal Medicine & Surgery



INSIDE THIS ISSUE



<i>Welcome</i>	1
<i>Hysteroscopy Pictures</i> <i>Calcium deposits</i>	2
<i>Interview of the month</i> <i>Andreas Thurkow</i>	3
<i>HysteroProject</i>	5
<i>Original Article</i> <i>Pain during Myomectomy by</i> <i>Mechanical Morcellation</i>	6
<i>Talking About</i> <i>Surgical correction of the</i> <i>Septate Uterus</i>	9
<i>Basic Hysteroscopy</i> <i>Isthmocele</i>	11
<i>Original Article</i> <i>The “mini-resectoscope”</i> <i>In daily use</i>	15

TEAM COODINATOR
SPAIN
L. Alonso

EDITORIAL COMMITTEE

SPAIN
E. Cayuela
L. Nieto

ITALY
G. Gubbini
A. S. Laganà

USA
J. Carugno
L. Bradley

MEXICO
J. Alanis-Fuentes

PORTUGAL
J. Metello

ARGENTINA
A. M. Gonzalez

VENEZUELA
J. Jimenez

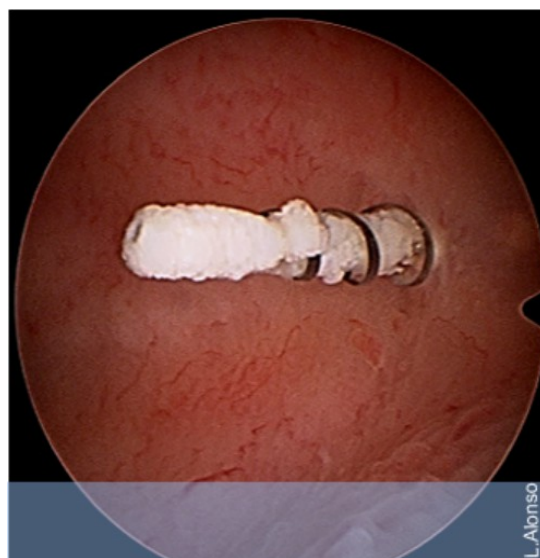SCIENTIFIC COMMITTEE

A. Tinelli (Ita)
O. Shawki (Egy)
A. Úbeda (Spa)
A. Arias (Ven)
M. Rodrigo (Spa)
A. Di Spiezio Sardo (Ita)
E. de la Blanca (Spa)
A. Favilli (Ita)
M. Bigozzi (Arg)
S. Haimovich (Spa)
E. Xia (Cn)
R. Lasmar (Bra)
A. Garcia (USA)
N. Malhotra (Ind)
J. Dotto (Arg)
R. Manchanda (Ind)
M. Medvediev (Ukr)
M. Elessawy (Ger)
E. Boschetti Grützmacher (Ita)
X. Xiang (Cn)
G. Stamenov (Bul)
Thiago Guazzelli (Bra)

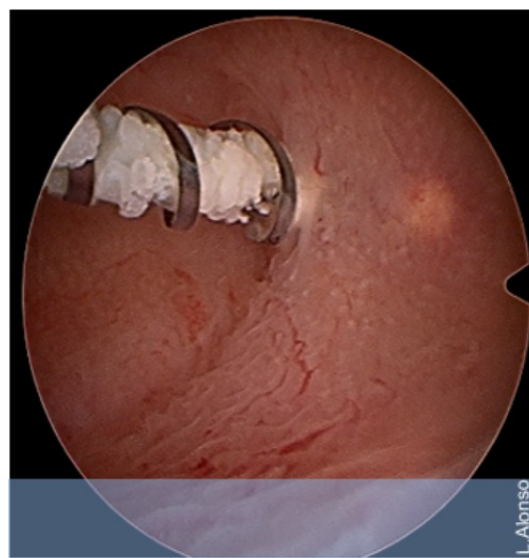
All rights reserved.

The responsibility of the signed contributions is primarily of the authors and does not necessarily reflect the views of the editorial or scientific committees.

HYSTEROSCOPY PICTURES



Calcium deposits in the intracavitary portion of the essure



Detailed view of the calcium carbonate deposits

The appearance of calcium deposits on the copper portion of intrauterine devices (Copper IUD) is a well-known and documented fact. Published studies trying to explain the etiology of this condition, have found a correlation between the length of time that the IUD has been inside the uterine cavity and the presence of calcium deposits, although there is large variation. Moreover, it has been reported that the presence of calcium deposits is greater if there is inflammation.

The presence of calcium deposits in the intracavitary portion of the essure devices is also documented (Maassen, LW, van Gastel, DM, Lentjes, EGWM, Bongers, MY, & Veersema, S. (2017) .Intracavitary deposits on Essure® hysteroscopic sterilization devices: A case report, Case Reports in Women's Health, 15, 3-5.). In this study, the authors determined the composition of the calcium deposits by infrared spectroscopy (Calcium carbonate). The determination of the same deposits in the copper portion of IUDs, have given the same component, which seems to suggest a predisposition of the uterus to form calcium ions that deposit on metals when present inside the uterine cavity.

If you are interested in sharing your cases or have a hysteroscopy image that you consider unique and want to share, send it to hysteronews@gmail.com

INTERVIEW WITH..

Dr. Andreas Thurkow is a man ahead of his time and one of the pioneering hysteroscopy in the Netherlands. At the beginning he was a “misunderstood genius”.

Is there a growing interest in hysteroscopy? What are the causes?

Yes, I see a definitive growing interest in hysteroscopy. We are far from the situation when I started hysteroscopy in the beginning of the 80's and colleagues considered me to be an (albeit harmless) idiot performing a useless procedure without any scientific proof of the benefits. But even since hysteroscopy has been accepted as a routine procedure I can see more and more interest in both diagnostic and operative hysteroscopy, especially since both can increasingly be performed in office setting. Now of course experts have always been able to do this, but techniques and instruments have lowered the threshold even in less experienced hands and more colleagues now realize this and in many countries education on hysteroscopy is now offered in residency training programs.

Having said this, I am still amazed to see that in some countries, like the US, the implementation of hysteroscopy is still so much lower than in other industrialized nations. I am very motivated to be of help in educational activities to change this situation and for this reason I am most honored to be able to participate in the global steering committee OEI (Office Education Initiative) of Hologic which will focus exactly on this topic.

In your opinion, Whats the future of the hysteroscopic sterilization?

Ah, the future of hysteroscopic sterilization! That is really an important topic for me. Off course now all of us (patients, care givers, insurance companies, authorities, etc.) are extremely fearful of a repetition of the Essure debacle. But I sincerely hope that we shall ultimately be able to find a system that does not cause the late effects that we have seen with Essure and that we shall be capable of discussing the procedure in an honest way with our patients. Although in most cases we still have no clue what causes the problems many women are seeming to have with Essure, it seems logical to leave out as many components as possible, ideally not leave any implant in the body. The sad thing is that there still definitively remains to be a significant difference in invasiveness between a laparoscopic and a hysteroscopic approach with scientific proof of corresponding complication rates. And this applies especially for those patients who have a contraindication for laparoscopy (e.g. prior surgery, clotting disorders).

I know there are several systems and devices that potentially could become an alternative for Essure. Of these (I am aware of at least 4 systems) Altaseal® probably has the best odds for the future because it has the largest number of data in terms of clinical results, most of which I have collected as investigator.

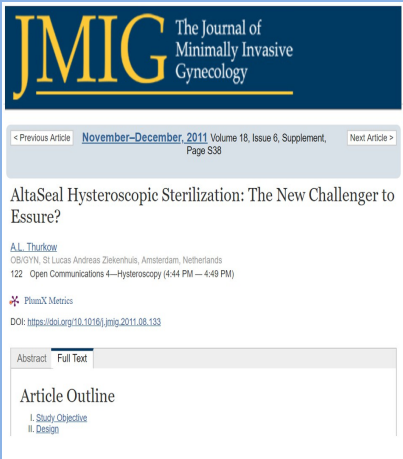

Andreas Thurkow

Consultant Gynaecology

Academic Medical Centre
Amsterdam

Netherlands



The novel AltaSeal® implant was developed to close the fallopian tubes and prevent pregnancy. AltaSeal® is a 300 series medical grade stainless steel implant (similar to a coronary stent). It is placed in the portion of the fallopian tubes in the uterus wall by a gynaecologist without the need for open surgery or general anaesthetic.

Training courses and hands on are really important for beginners. Do you agree?

I absolutely agree with this statement! In my opinion it is mandatory to learn the eye-hand coordination needed for hysteroscopy as well as the instruments involved in surgery on models before starting to use the technique on actual patients. I have tried to implement this in vain for a very long time. Unfortunately, it took a serious complication years ago in my centre to convince others of the necessity of this condition, after which it indeed became a prerequisite without which residents in all affiliated hospitals of both Amsterdam University Centres were no longer allowed to perform any type of hysteroscopy.

According to your experience, what is the most difficult hysteroscopic surgery to perform?

The most difficult hysteroscopic surgery to perform is probably hysteroscopic adhaesiolysis, especially when the uterine cavity is entirely obliterated. The relative rareness of these Asherman cases obviously adds to the need to centralize this type of surgery. I started this type of procedures during my training in 1982 and by the end of my training I had already performed 50 cases, since nobody in a very wide area around the University Hospital of Groningen (more than 1 million inhabitants) where I trained had any experience in hysteroscopy at all.

“...be motivated, stay focused and have patience, even if you may encounter obstacles on your way once in a while”

Probably the second most difficult hysteroscopic surgery is the resection of large (4 cm or more) type 2 fibroids with deep involvement of the myometrium. To prevent intravasation and perforation a combination of skills is needed: a perfect 3D assessment of the uterus together with absolute control over the eye-hand coordination, combined with sufficient speed to end the surgery before the maximum deficit is reached. I have adopted a new technique for more speed, in which I cut the fibroid in several portions and enucleate these as much as possible, that can be removed under transrectal ultrasound guidance as soon as the maximum deficit is (about to be) reached. The ultrasound guidance also allows for control of the overlying normal myometrium between the fibroid and the serosa.

Interestingly, I had used this enucleation technique for several years before I became aware of others using a similar approach (e.g. Dr Ivan Mazzon). Apparently good ideas tend to emerge almost simultaneously and independently of each other, another example of this being the adaption of orthopedic shavers for hysteroscopy by both Dr Mark Hans Emanuel and Dr Guiseppe Bigatti, which also seem to have been independent developments.

Do you have any advice for the young physician who is starting out in the world of minimally invasive gynecological surgery?

My advice for young doctors at the beginning of their career is to do the same as I have done: be motivated, stay focused and have patience, even if you may encounter obstacles on your way once in a while. As I said before, in the 80's I have often been looked upon as being a bit crazy to “play around” with a technique that has no scientific proof of being of any use what so ever. I have specifically mentioned these motivational words as an inspiration for young colleagues in my Thank You speech after I received the COBRA award in 2014, which is a prize presented once in every 2 years to the doctor who has made an exceptional contribution to the development of surgery within the field of gynaecology in the Netherlands.

HYSTERO P rojects

Hysteroscopy Newsletter & OBG Project

[About Us](#) [Contact Us](#) [Login](#) [CME@ObG](#)

ACOG Guidance on Thrombophilia in Pregnancy

Neural Tube Defects: Definitions, Key Clinical Findings and Management

Learn more about THE OBG PROJECT

[Site Map](#) / [© OBG Project](#) / [Terms and Conditions](#) / [Privacy](#) / [Contact Us](#)

Original Article

Hysteroscopy Newsletter Vol 4 Issue 6

Pain during myomectomy by mechanical hysteroscopic morcellation: Impact of myoma characteristics and other factors that influence pain and patient satisfaction.

Galan Gutierrez,MJ; Forero Diaz,C; Martinez Cortes,FJ; Vidal Mazo,C.

Hospital Juan Ramon Jimenez. Huelva

ABSTRACT

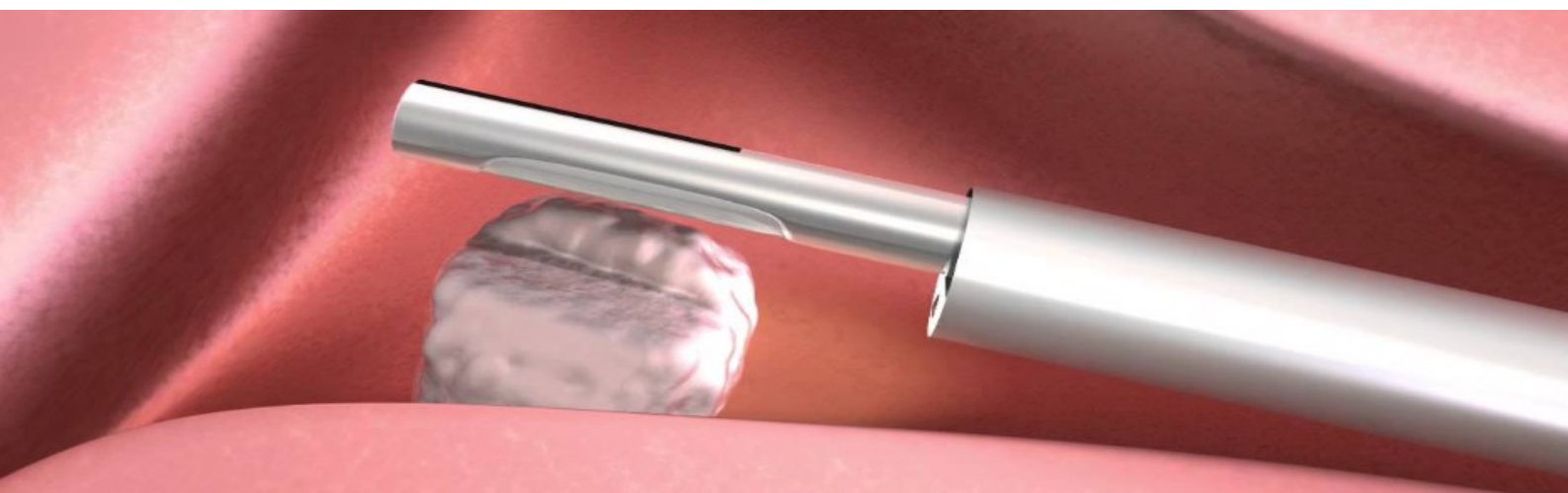
Mechanical myomectomy hysteroscopy with Myosure® is a procedure that allows the treatment of submucosal myomas on an outpatient basis. One of the challenges facing in-office hysteroscopic myomectomy is to reduce pain and anxiety.

In the evaluation of different pain predictors, multiple studies have reported controversial results on the importance of different clinical variables, but there are no studies on the factors inherent to the pathology to be treated and the surgeon. To investigate the correlation between different variables and pain levels during hysteroscopic myomectomy, considering that there are several variables, a multivariate approach is required.

As a second objective, we wanted to evaluate subjective factors perceived by the patients, which are going to play a very important role in pain tolerance and the degree of patient satisfaction during mechanical morcellation of fibroids and large polyps

Keywords:

Mechanical myomectomy,
Myosure, pain predictors,
satisfaction



FIRST OBJECTIVE

In the first phase of the study, we aim to evaluate the correlation between pain and factors inherent to the myoma: type and number of myomas, size of the myoma base, morcellation time and operator.

METHODS

We performed a retrospective analysis of 190 hysteroscopic myomectomies between 2013 and 2017 performed at the Endoscopy Unit of the Juan Ramón Jiménez Hospital in Huelva. All the mechanical morcellations were performed with Myosure®. The data have been collected through the database, studying the following variables related to pain: myoma type, number, size, extension of the base, morcellation time and the surgeon.

The statistical analysis was performed with the SPSS v22 program. For the determination of correlation between qualitative variables, the Kruskal Wallis test was calculated ($p < 0.05$).

RESULTS

190 procedures were reviewed. The average age was 43.65 years.

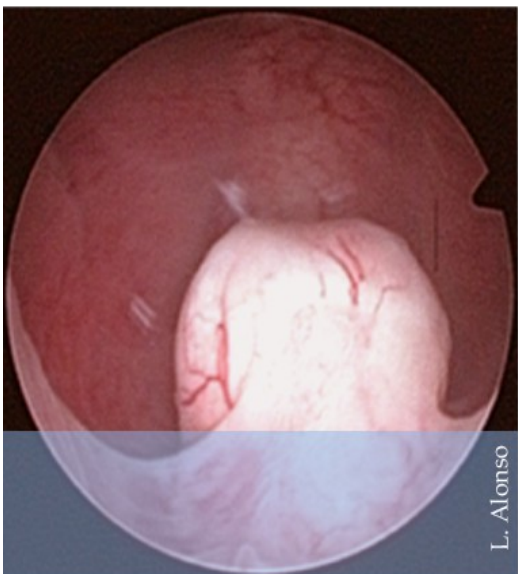
The correlation between pain and the following variables is evaluated: parity, type and number of myomas, extension of the base, morcellation time and type of operator with the Chi square test, including the contingency coefficient to determine the magnitude of said dependency in the event that it is significant.

CONCLUSIONS

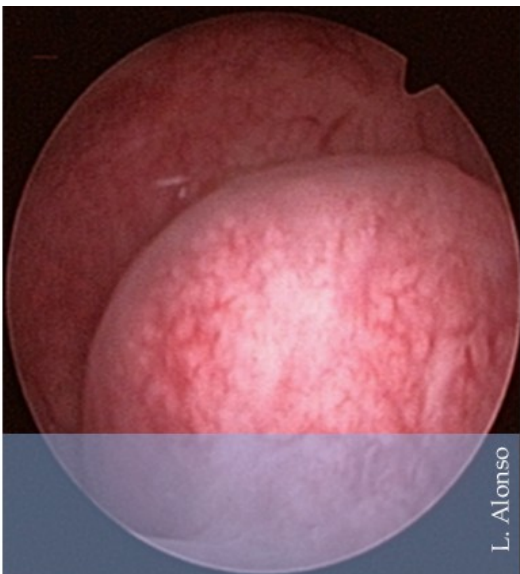
It has not been shown in our study that the characteristics inherent to the myoma or the operator influence the perceived pain. It is the patient's own conditions that will allow the technique to be successfully developed on an outpatient basis

Based on these conclusions, we try to determine the influence of factors outside the hysteroscopic mechanical morcellation technique that influence the pain and degree of satisfaction perceived by the patients and that will allow to perform this technique in an outpatient setting.

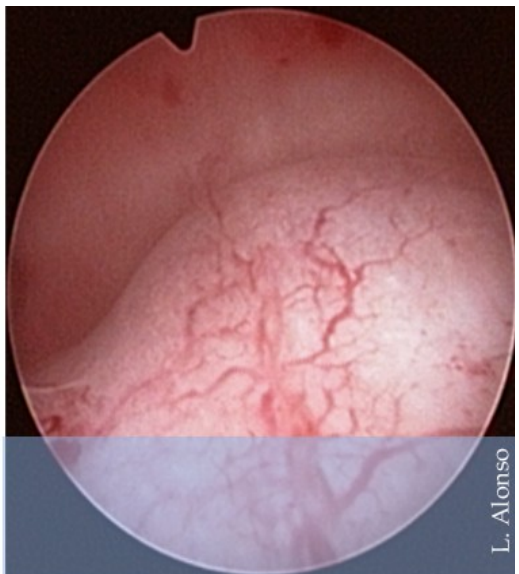
Evaluate the sociocultural, labor and other factors to take in consideration during the performance of the technique when the procedure is performed in-office.



Type 0 leiomyomas are entirely (90 - 100%) within the uterine cavity



Type 1 leiomyomas are between 50 and 90% within the cavity



Type 2 leiomyomas are between 0 and 49% within the uterine cavity

SECOND OBJECTIVE

In a second phase and after not obtaining statistically significant correlation between the variables inherent to the myoma and the surgeon, we decided to: Identify and determine the influence of factors outside the hysteroscopic mechanical morcellation technique that influence pain and degree of satisfaction perceived by the patients and that will allow to perform this technique in an outpatient setting

METHOD

We performed a retrospective descriptive analysis of 375 patients (including mechanical hysteroscopic polypectomies) using hysteroscopic mechanical morcellation performed between 2013 and 2017 in the Endoscopy Unit of the Juan Ramón Jiménez Hospital in Huelva.

All mechanical morcellations were performed with Myosure® device. At the end of the procedure, the patient was given an anonymous survey inquiring the following aspects: overall time dedicated to the patient (explaining the procedure), performance of the doctor and the staff and privacy and comfort during the procedure in the office.

We performed a linear regression analysis of the influence of all the factors mentioned in the degree of satisfaction and pain perceived by the patients.

The statistical analysis was performed with the SPSS v22 program. For the determination of correlation between qualitative variables, the ANOVA test was calculated.

RESULTS

375 procedures were recruited. The average age was 48 years. Regarding the level of education:

39% of the patients had basic level of education only, 32% secondary, 18% university. 44% of the patients were unemployed, housewives or retired, 29% were employees.

By means of the analysis with ANOVA test, we can conclude that pain correlates in an inversely proportional way to the total time dedicated to the patient and by privacy during the procedure, following the following equation: $\text{Pain} = 11.202 + (-1.106) \cdot \text{Intimacy} + (-.654) \cdot \text{Dedicated time}$. This model is significant ($p < .01$).

By means of the analysis with the ANOVA test, we can conclude that the degree of satisfaction of the patients is determined in a directly proportional way by the treatment by the nursing staff during the procedure and by the comfort during the procedure, as per the following equation: $\text{Satisfaction} = 3.213 + (.311) \cdot \text{Nursing treatment} + .144 \cdot \text{Comfort}$. This model is significant ($p < .01$).

CONCLUSIONS

One of the challenges facing this procedure is to reduce pain and anxiety, maintaining optimal communication with patients to maximize satisfaction. According to the results of our study, in order to reduce pain, we should ensure privacy during the procedure and optimize the overall time dedicated to the patient, referring above all to the previous explanation of how the procedure will be performed and how she will perceive it.

To increase patient satisfaction with this in office procedure, we must maximize the comfort in the office taking into account comfort and ergonomics of the patient and nursing staff care since generally the nursing staff is responsible for monitoring and counsel the patient, helping to reduce pain and anxiety.



Talking About

Hysteroscopy Newsletter Vol 4 Issue 6

Surgical Correction of the Septate Uterus

The need for a surgical treatment in a patient with septate uterus depends on the obstetric history rather than the septum and the main indication for treatment is a history of reproductive failure. There is still controversy about the indication for metroplasty and while some authors recommend the surgery only in cases of bad obstetrics outcomes, others recommend a prophylactic metroplasty in particular cases.

It is well accepted that the main indication for metroplasty is recurrent pregnancy loss and that the metroplasty significantly improves the reproductive outcomes in patients with septate uterus. The situation remains controversial in women with only one miscarriage and a conservative approach is recommended.

Regarding patients with primary infertility, the role of metroplasty is a matter of debate and other concomitant causes of infertility have to be ruled out. The prospective controlled trial by Molloy found a higher probability of conceiving after removal of the septum compared with patients affected by unexplained infertility.

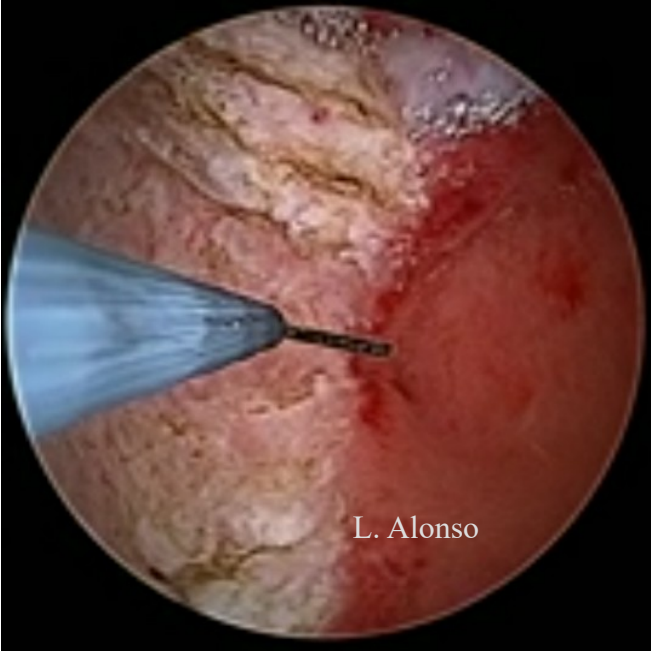
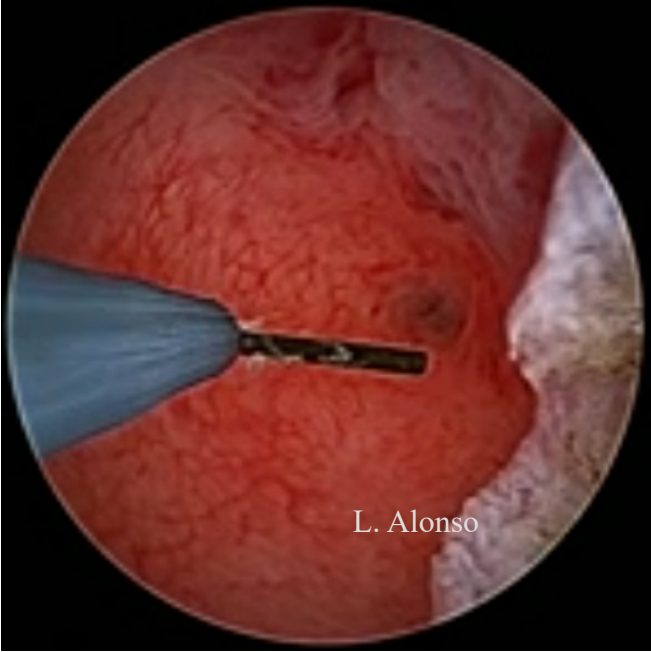
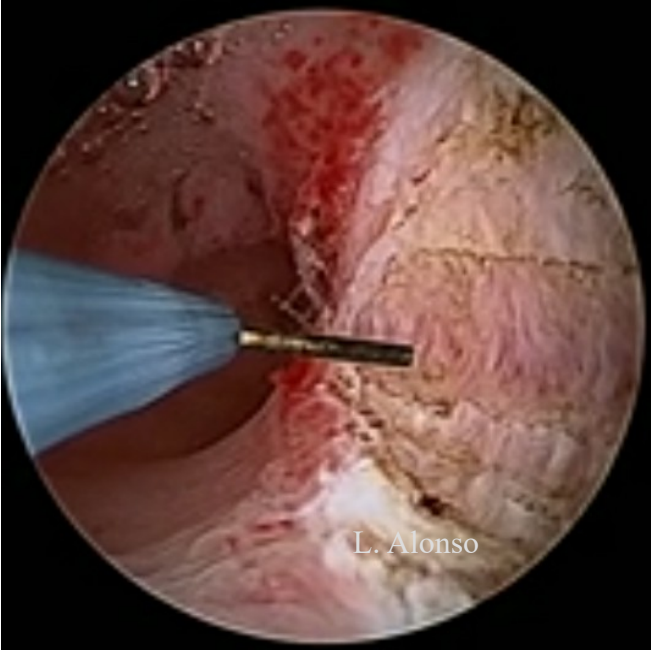
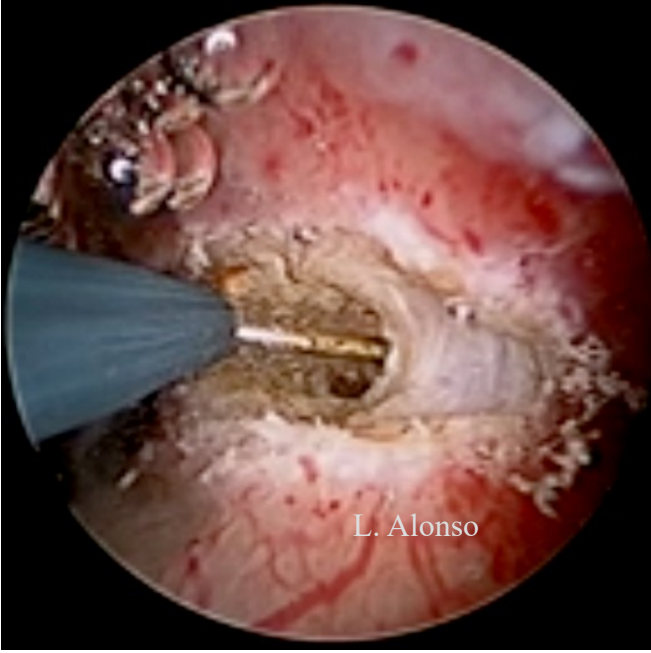
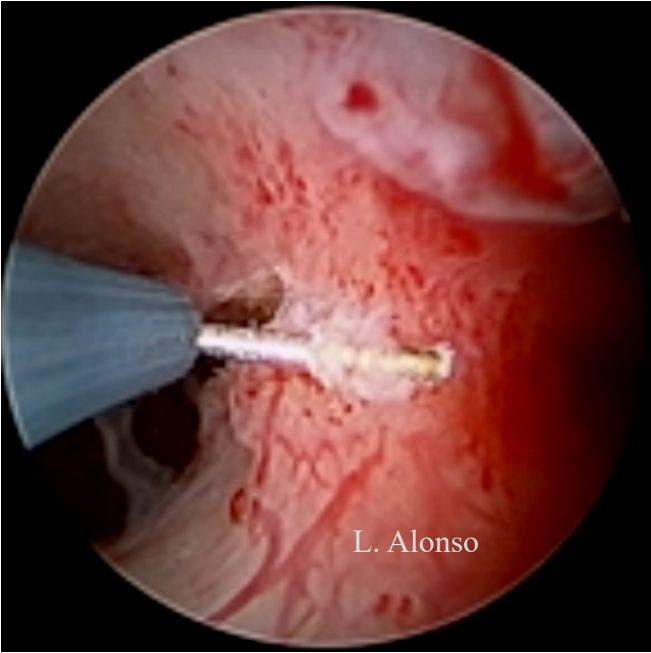
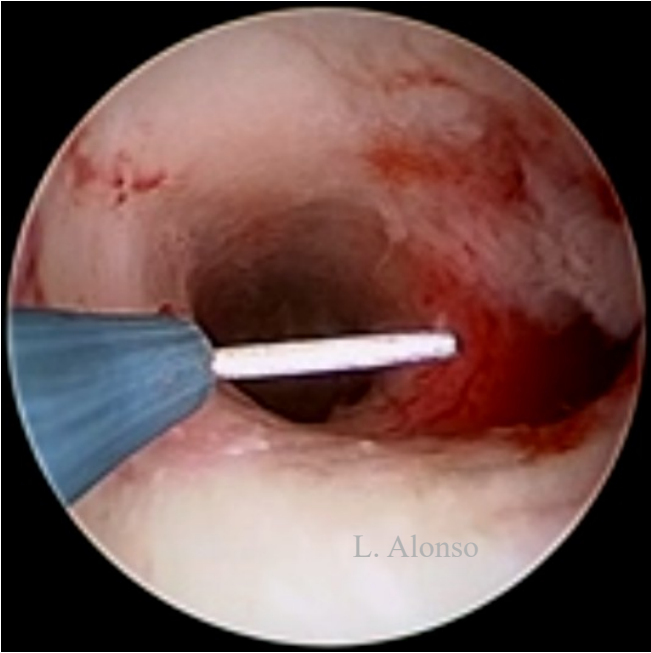
The role of the hysteroscopy metroplasty in patients that require an assisted reproduction technique is a matter of debate. In a prospective randomized trial on hysteroscopic metroplasty in patients with previous in vitro fertilization (IVF) cycles failure, De Angelis demonstrated the beneficial effects of metroplasty prior to a new IVF cycle in terms of pregnancy rates and in the incidence of miscarriage, concluding that the hysteroscopic metroplasty should be advisable before an IVF cycle to improve the pregnancy rates and to reduce the incidence of spontaneous abortion.

In 1974, Edstrom first described the resection of a uterine septum guided by hysteroscopy. This first endoscopic approach was the starting point for the actual metroplasty. Currently, hysteroscopy approach has replaced transabdominal techniques.

Hysteroscopy metroplasty is, in fact, a transversal incision of the uterine septum instead a resection. This incision has to be made in the middle of the septum, equidistant to the anterior and posterior uterine walls. Tubal ostia are helpful to maintain the right plane avoiding the lesion of the normal myometrium. The determination of the correct incision line is one of the most important parts of the hysteroscopic metroplasty, but this imaginary line is not always easy to determine. Levent Yasar and Ali Süha Sönmez described the "Süha-Levent sign". After methylene blue injection, they found a well-defined blue line of 2–3 mm, over the septum between the tubal ostia and equidistant to the anterior and the posterior walls. This blue guide helped them to identify the correct incision line.

Two different surgical approaches for the septum have been described, the thinning technique and the shortening one. In the thinning technique, longitudinal incisions are performed over each side of the uterus from the base to the apex of the septum. The objective is to reduce the width of the septum and to transform the initial septum in a fundal remnant of tissue that can be incised from one cornual recess to the other. In the "shortening" technique, the septum is incised transversely, starting from the apex towards the fundus. This incision in the midline of the septum, retracts the remaining tissue towards the anterior and posterior uterine walls.

The selection of one of the above techniques depends on the width and the length of the septum. As a general recommendation, for a broad septum it is better to use the thinner technique while for a thin septum, the "shortening" is the most appropriate.



Basic Hysteroscopy

Hysteroscopy Newsletter Vol 4 Issue 6

Isthmocele

Luis Alonso. Centro Gutenberg. Spain

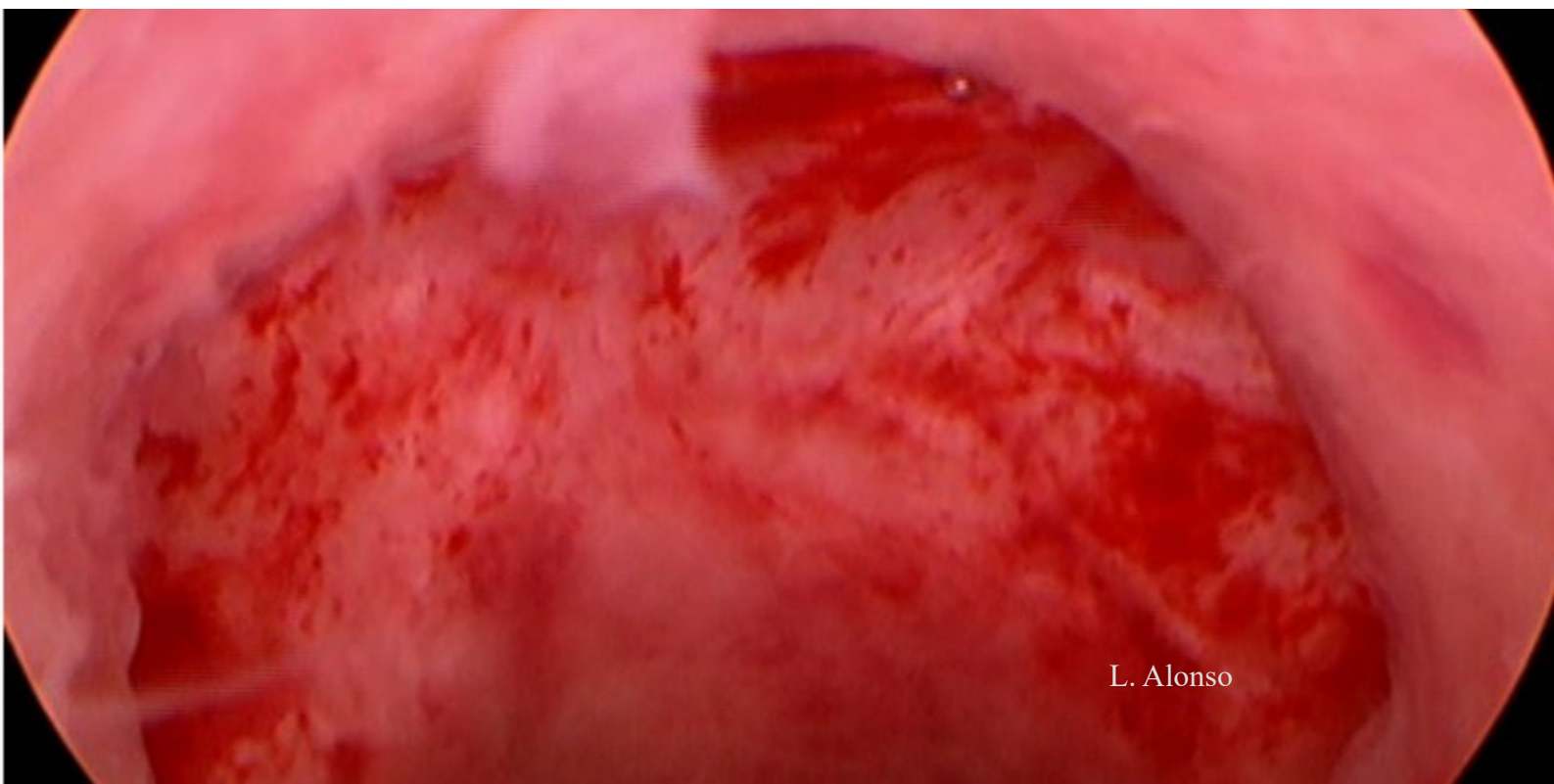
The cesarean section rate is alarmingly increasing in recent years in developed countries, this has been associated with an increase in the economic expense derived from the surgical intervention and on the other hand the appearance of new problems derived from the cesarean section itself, which may be both obstetric and gynecological in nature.

The most frequently documented in the literature are poor obstetric consequences in subsequent pregnancies after cesarean section, being well recognized the correlation between a previous cesarean section and the risk of developing placenta previa, placental accreta, implantation of pregnancy at the level of the cesarean scar and uterine rupture. Among future gynecological problems described in patients undergoing cesarean section are abnormal uterine bleeding, dyspareunia and abdominal pain.

When performing a pelvic ultrasound in patients with history of cesarean section, it is frequent to

find a hypoechogenic area, generally triangular with the vertex directed towards the bladder of different sizes, at the level of the previous caesarean section scar. This ultrasound image, defined as an "Isthmocele". It is a uterine wall sac-like structure located in the lower uterine wall, just in the area of the scar of a previous cesarean section.

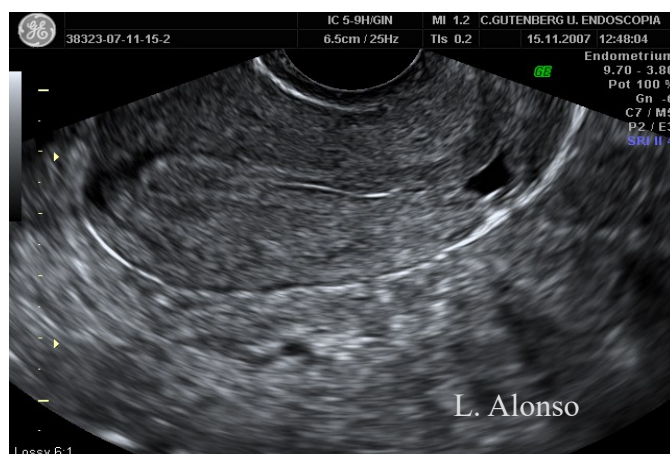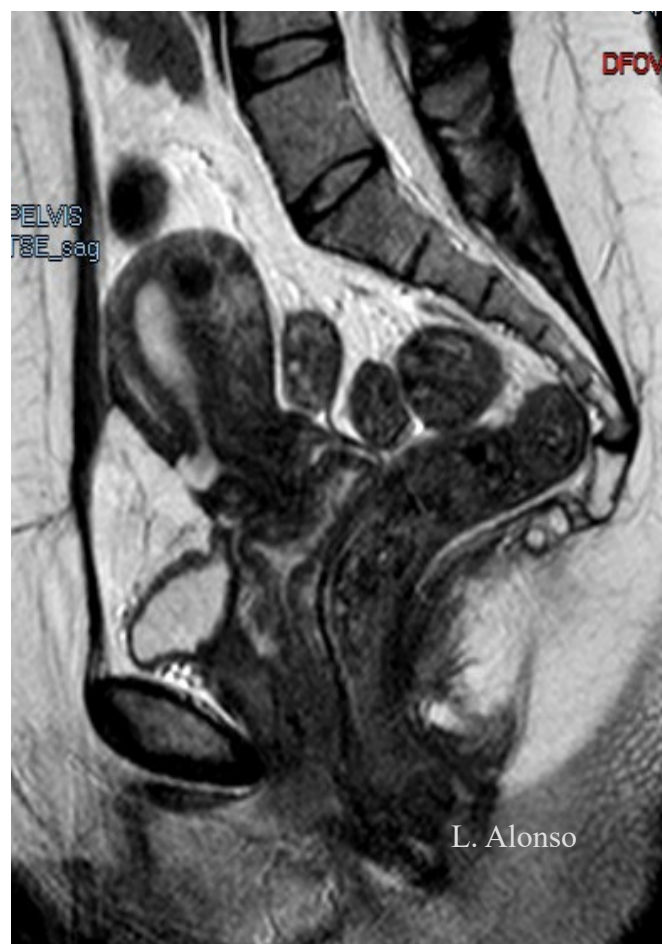
The importance of the isthmocele lies, on the one hand, in its correlation to abnormal uterine bleeding that is usually post-menstrual, and on the other hand in its relationship with secondary infertility. Regarding to the abnormal bleeding, the main cause is that the isthmocele acts as a reservoir that hinders the flow of the menstrual blood; In addition, there is minimal "in situ" blood production derived from the increase in local vascularization at the level of the base of the isthmocele and local alteration of uterine contractility. Regarding the correlation with secondary infertility, the persistence of menstrual flow at the cervical level has a negative impact on sperm transport as well as implantation.



L. Alonso

Several mechanisms to explain the isthmocele formation are considered. One is the difference in thickness between the anterior and posterior segments of the hysterotomy, another the different types of suture material used to close the hysterotomy. It seems that the more ischemic areas are created, the greater the possibility of developing an isthmocele, this leads to consider whether the use of 2 layers closure technique of the hysterotomy increases the risk of isthmocele formation.

The diagnosis of isthmocele is based on clinical signs and complementary tests such as ultrasound, hysterosonography and/or hysteroscopy. The ultrasound shows the presence of an hypoechogenic area, generally of triangular shape, located at the isthmic level with the vertex of it directed towards the bladder (3). This isthmocele is echographically more evident if ultrasound is performed during the postmenstrual phase, since blood accumulation facilitates the visualization as an ecogenic area. The measures that are usually carried out in this ecogenic area, are the ones to measure their area, following the formula (base x height / 2), classifying the



isthmoceles according to the result in 3 degrees, grade 1 when the area is less than 15 mm², Grade 2 between 16 and 24 mm² and grade 3 when it is greater than 25 mm².

Hysterosonography enhance visualization of the isthmocele even when there is no blood accumulation inside of it. Hysteroscopy is the "Gold Standard" technique for the diagnosis of isthmocele. Hysteroscopy allows direct visualization of the anterior and posterior borders of the isthmocele that some authors define as an anterior and a posterior arch, the isthmocele is actually the area contained between these two arches.

There are several proposed treatments aimed at resolving the symptomatology associated with the isthmocele, especially bleeding and secondary infertility. The use of hormonal treatment has shown a decrease in the duration of postmenstrual bleeding and an improvement with respect to the associated symptomatology, although they do not eliminate the symptoms and have been less effective than surgical treatment. Some experts prefer to the laparoscopic (4) and even transvaginal route for the surgical treatment of the scar dehiscence of a previous cesarean section.

The hysteroscopic repair of a cesarean scar is frequently referred as Isthmoplasty. The surgical technique first described by Fernandez in 1996 at the 25th annual meeting of the AAGL (5), consists of remodeling the sac "flattening" the area of the isthmocele from the lower arch to the external cervical os. The surgical procedure must be performed extremely carefully and very superficially, taking into account that the dome of the isthmocele is in close contact with the bladder

and the lateral areas of the defect with the uterine arteries (1). In addition to carrying out the resection of the fibrotic tissue, Fabres favors the treatment of the tissue at the base of the defect by means of the local fulguration of the dilated vessels as well as the inflammatory tissue, responsible for the "in situ" blood production.

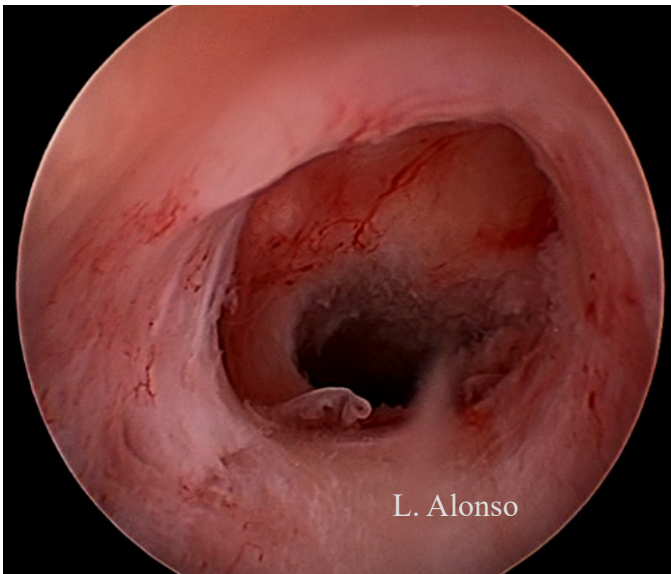
The latest studies show that the surgical treatment of the isthmocele eliminates the symptoms of postmenstrual spotting in the vast majority of patients, it is also important to note that after surgery, some patients restore their fertility, obtaining in these patients pregnancy in the first 6-12 months after surgical correction (6).

CONCLUSIONS

The surgical treatment of isthmocele aims to avoid retention of menstrual blood at the level of the defect, eliminating post-menstrual spotting pattern and its consequences. The hysteroscopic approach is a symptomatic treatment, while laparoscopic or vaginal treatment aims to repair the defect, so are considered a restorative treatment. As a general rule, it is accepted that in cases in which the residual myometrium thickness at the level of the isthmocele is greater than 3 mm, the hysteroscopic approach is an adequate and safe option. However, if the endometrial thickness at this level is less than 3 mm, the laparoscopic approach should be preferred because of the risk of uterine perforation and allows to restore the uterine wall at that level. (7)

After surgical treatment, a new questions arise, such as whether a spontaneous vaginal delivery is safe after the completion of the isthmoplasty. The recommendation of the Global Congress of Hysteroscopy Research Committee is the to perform an elective cesarean section no later than week 38 of gestation due to the risk of uterine rupture (7)

It is important to bear in mind that post-menstrual bleeding in patients with a previous caesarean section may be related to the presence of an isthmocele and that they can also cause secondary infertility. It is also important to remember that the only treatment of this condition is surgical and that hormonal treatments do not solve the problem.



REFERENCES

1- Gubbini G, Casadio P, , Marra E. Resectoscopic correction of the isthmocele in women with postmenstrual abnormal uterine bleeding and secondary infertility. *J. Minim Invasive Gynecol.* 2008; 15: 172-175

2- Morris H. Surgycal pathology of the lower uterine segment cesarean section scar: is the scar a source of clinical symptoms? *Int J Gynecol Pathol* 1995; 14(1): 16-20

3- Fabre C, Aviles G, de la Jara C et al. The cesarean delivery scar pouch: Clinical implications and diagnostic correlation between sonography and hysteroscopy. *J Ultrasound Med.* 2003; 22:695-700

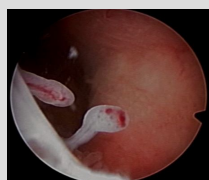
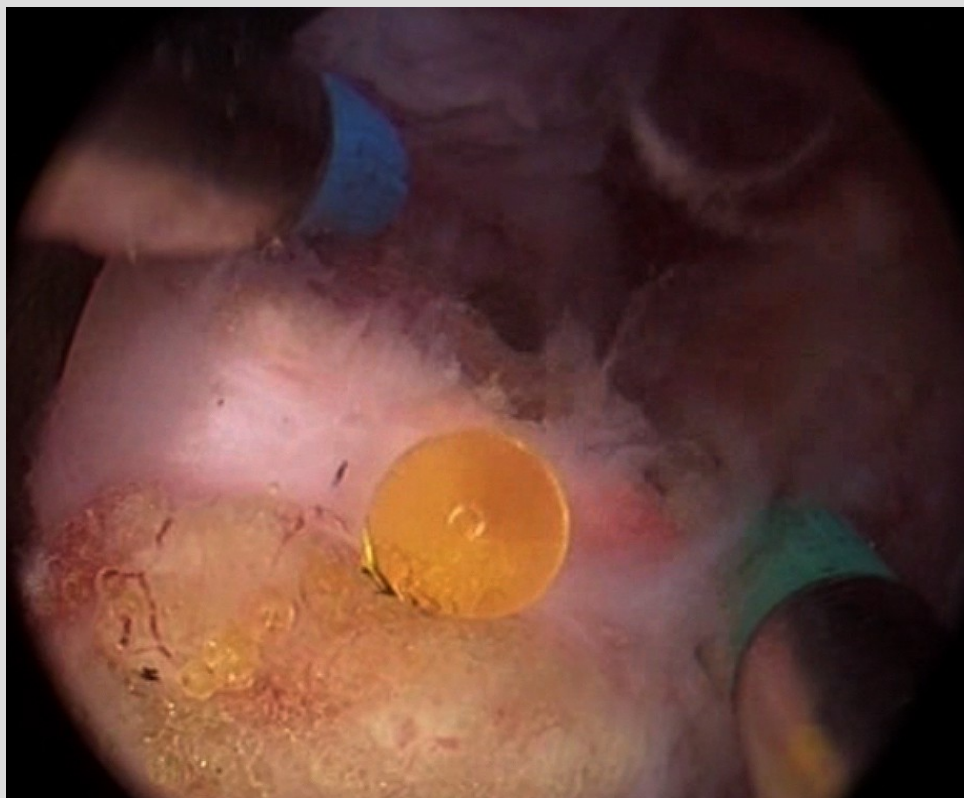
4- Donnez O, Jadoul P, SquiffletJ, Donnez J. Laparoscopic repair of wide and deep uterine scar dehiscence after cesarean section. *Fertil Steril* 2008; 89: 974-80

5- Fernandez E, Fernandez C, Fabres C, Alam VV: Hysteroscopic correction of cesarean section scars in women with abnormal uterine bleeding. *J Am Assoc Gynecol Laparosc.* 1996; 3-s13


6- Gubbini G, Centini G, Nascetti D, Marra E, Moncini I, Bruni L, Petraglia F, Florio P. Surgical Hysteroscopic treatment of cesarean-induced isthmocele in restoring fertility: prospective study *J. Minim Invasive Gynecol* 2011; 18: 234-237

7- Lagana, A. S., Pacheco, L. A., Tinelli, A., Haimovich, S., Carugno, J., Ghezzi, F. Optimal Timing and Recommended Route of Delivery after Hysteroscopic Management of Isthmocele? A Consensus Statement From the Global Congress on Hysteroscopy Scientific Committee. *J. Minim Invasive Gynecol* 2018; 25:558

What's your diagnosis?



*Answer to past edition:
Close view of micropolyps*



ISARCON 2017 Manual of Operative Hysteroscopy M. Ahuja, N. Malhotra, P. Loomba Jaypee Brothers 2017

ISAR workshop manuals were released at the workshops of ISARCON 2017 at the Annual Congress, Gurugram, Haryana, India.

- A complete A-Z of hands on of all infertility diagnosis, management for both male and female.
- Manuals cover male factor infertility in the manual of March to Perfection from simple examination of sample to all washing techniques and detection of ROS (Reactive Oxygen Species).
- For females covers from role of USG in infertility (Ultrasound) to all the endoscopy procedures from diagnosis to treatment in both hysteroscopy and endoscopy.
- In IVF authors are demonstrating even gamete handling and ovum pick up and embryo transfer in the actual lab settings. Also discusses embryo and prenatal genetic diagnosis and prenatal genetic study techniques.
- All these manuals are well written point-wise, have flow charts, diagrams and good-quality photographs for ease of reading and understanding.

Original Article

Hysteroscopy Newsletter Vol 4 Issue 6

The 18,5 Fr. "mini-resectoscope" in daily use

Antonio Accardi
Department of Gynecology and Obstetrics, ASP 6 Palermo

ABSTRACT

We aimed to evaluate the feasibility of a new 18,5 Fr. Hybrid mini-resectoscope to treat the most common intrauterine pathologies (AUB, Myomas, Polyps) in vaginoscopy and without prior cervical dilatation.

We performed a multicentric prospective observational pilot study, from 30 June 2016 to June 2017. We consecutively enrolled 230 the patients (both in reproductive age and post-menopausal) scheduled for resectoscopy due to different types of intrauterine pathologies.

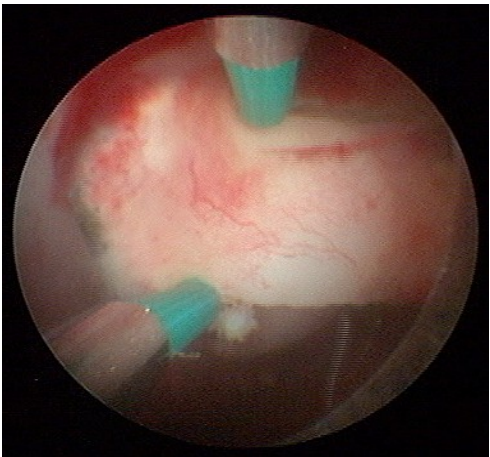
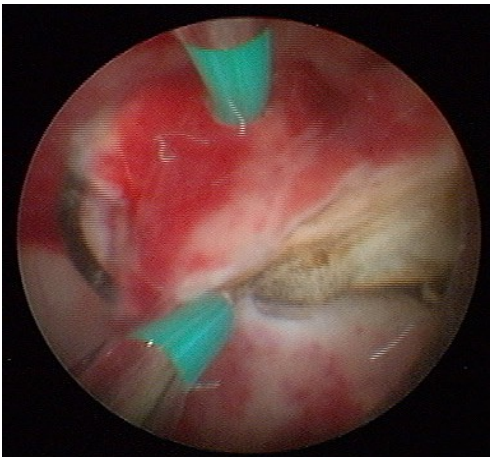
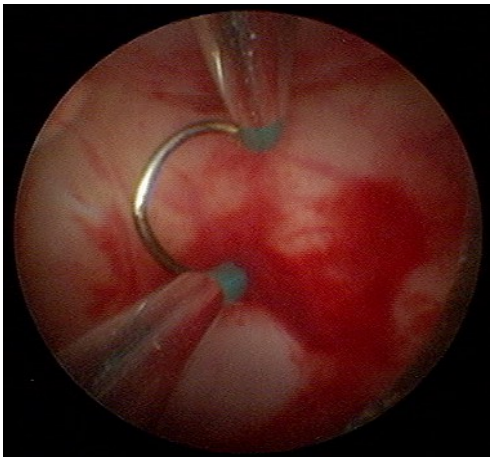
Mean age of enrolled patients was 45,82 years (22 – 78), mean parity was 1.5; 4 patients were virgo. All the operations were successfully completed and in one step.

We had direct access to the uterine cavity in 86.8 % of the cases, sometimes using loop or cold knife as probe to perform cervical adhesiolysis; in the remaining cases, we had to perform cervical dilatation with hegars until 6,5 (5.5% of the cases) or use a 5.5 mm hysteroscope.

Keywords:

Resectoscopy, AUB,
Histmocele, vaginoscopy,
18 Fr. Resectoscope

Summarizing our data analysis, the use of 18,5 Fr miniresectoscope allows to perform vaginoscopy, direct uterine access without cervical dilatation and management of the most common intrauterine pathologies in most of the cases (86.8%).



INTRODUCTION

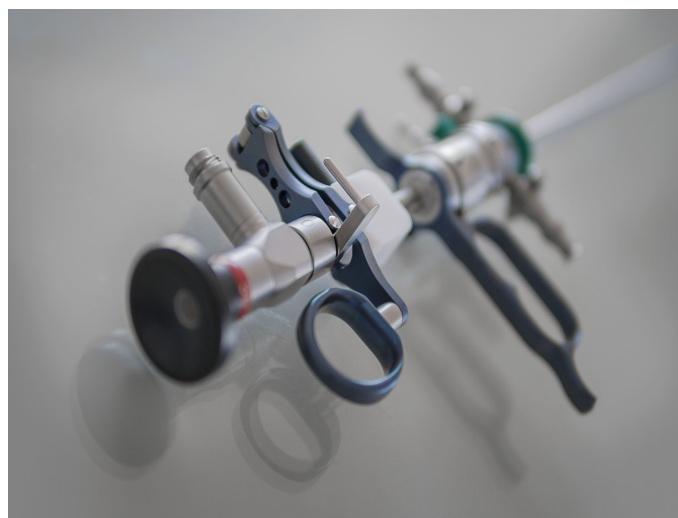In the last 30 years, the advent of urological derived resectoscope in gynecological practice, has allowed endoscopic treatment of endouterine pathologies. Thanks to these instruments associated with electrosurgery we managed to treat what previously seemed unthinkable and above all cause a high number of hysterectomies: endocavitary myomas and abnormal uterine bleeding; moreover, the introduction of the new method allowed the conversion of the uterine septa from laparotomy to hysteroscopic treatment.

Until the years 2000, the caliber of the most used gynecological resectoscope ranged between 26 Fr. and 22 Fr, with the use of a speculum, neck forcep and consequent instrumental dilation of the uterine neck, all naturally under general anesthesia.

Undoubtedly the step forward compared to the classic, obsolete and inadequate D & C has been huge, but perhaps nowadays also the use of 26 Fr. Resectoscope it is almost anachronistic especially for small dimension endocavitary diseases. For this reason, in the last decade, a new "mini-resectoscope" of 16 Fr. has been introduced on the market, which has further changed our modus operandi. This instrument has led to direct access to the uterine cavity without speculum, neck forceps and Hegar, using special loop (tear) we were able to offer the patient the office treatment and in the operating room for the endouterine pathologies.

Undoubtedly there are many advantages using of this instrument, but the real limit probably results in the difficulty to face bigger pathologies due to the reduced dimensions of the cutting loops, thus prolonging the operating times. For the past few years, a new "mini-resectoscope" 18.5 Fr. has been introduced, which being "halfway" between 15 Fr. and 26 Fr. promises to be an excellent compromise between the two well-established instruments.

This resectoscope, which we now use daily, is made of titanium, equipped with a rotating mechanism, equipped with cutting loop and cold knife with a size of about 6 mm and various shapes, from the most classic (Loop 90 °, Collins et al) to some with original shape; considering the electrosurgical point of view the instrument is hybrid and can use both monopolar and bipolar energy; with regard to the optics it is possible to use the classic 2.9 mm, 30 ° or 0 ° degrees optics.



PURPOSE

We aimed to evaluate the feasibility of a new 18,5 Fr. Hybrid Mono\Bipolar mini-resectoscope (Grazia mini-resectoscope, RZ Medizintechnik, Tuttlingen, Germany) to treat the most common intrauterine pathologies (endometrial polyps, intracavitary myoma, uterine septa, histmocele, endometrial ablation for abnormal uterine bleeding) in vaginoscopy and without prior cervical dilatation, medical or instrumental treatment. We wanted to demonstrate that with this instrument we can largely reduce the use of 26 Fr. resectoscope, using them only for larger pathologies, thus obtaining a further reduction in complication rates related to instrumental dilatation and trauma on the uterine neck caused by the neck forceps.

METHOD

We performed a multicentric prospective observational pilot study, from 30 June 2016 to June 2017. We consecutively enrolled 230 the patients (both in reproductive age and post-menopausal) scheduled for resectoscopy due to different types of intrauterine pathologies. The study design was approved by an independent Institutional Review Board and all the patients signed informed consent for operation, sedation and to allow data and video collection for research purpose. Among patients in reproductive age, 70% underwent surgery during proliferative and 30% during secretive of the menstrual cycle (pregnancy was excluded by negative β -hcg test the day before surgery). In all the cases, we did not use cervical priming. We recorded patients' age, parity, type of pathology, percentage of direct access to

uterine cavity or conversely the necessity to use other techniques (hysteroscopic mechanical adhesiolysis/or cervical dilation until 6.5), operative times and complications.

RESULTS

Mean age of enrolled patients was 45,82 years (22 – 78), mean parity was 1.5; 4 patients were virgo. All the operations were successfully completed and in one step. Among the enrolled patients, we performed 135 single polypectomies (dimension range: 0.5 – 32 mm), 18 multiple polypectomies (total number range: 4-2), 27 single myomectomies (19 G0/G1, 6 G2, 1 G3, 1 in partial vaginal expulsion) 4 G0 myomectomy with concurrent single polypectomy) and 12 of them with previous pharmacological therapy, 9 complete septa, 7 sub-septa; 13 hystmoplasty surgery (3 cases were performed with concurrent polypectomy), 21 endometrial ablation (5 cases were performed with concurrent single polypectomy, 8 cases were performed with concurrent G1\G0 myomectomy) with previous pharmacological therapy. We had


direct access to the uterine cavity in 86.8 % of the cases, sometimes using loop or cold knife as probe to perform cervical adhesiolysis; in the remaining cases, we had to perform cervical dilatation with Hegars until 6,5 (5.5% of the cases) or use a 5.5 mm hysteroscope with rotating 5 Fr. Instruments (Accardi's Microrotate Instruments, RZ, Medizintechnik, Tuttlingen) for mechanical dilatation (7.6% of the cases). Mean operative time for all the operations was 3,7 min (0,58 - 32,08). No differences in "direct access" between No major complications occurred during or after all the procedures. Minor complications occurred in less than 2% of the procedures.

CONCLUSIONS

Summarizing our data analysis, the use of 18,5 Fr miniresectoscope allows to perform vaginoscopy, direct uterine access without cervical dilatation and management of the most common intrauterine pathologies in most of the cases (86.8%). We can affirm that this resectoscope is strongly recommended for uterine septa, endometrial ablation, endometrial and cervical polyps, myoma G0\G1\G2, histiocele, and in general for all the intrauterine pathologies. Still now we are not sure about the limit of pathologies dimensions. We consider the use of 6 mm loop guarantees a major cutting edge respect to the 15 Fr. miniresectoscopes with a "tear loop", allowing the surgeon to perform surgery in a very short time.

During the development of the work we were not able to really understand what was the reason for the failure of direct access to the cavity, considering that we could not always plan the procedures as we use to do in first cycle phase; we have found this problem both in nulliparous and pluriparous patients or in menopause, but not in the virgo even if we did it all the procedures in the right phase and in menopausal patient we did not fail. Certainly our difficulty of not being able to perform all the procedures in the initial proliferative phase has not been of help and for this reason we recommend once again to perform the hysteroscopic surgery always in the first phase of the cycle as is already recommended by the literature.

Nevertheless, we solicit future studies on larger cohorts to clarify as the 18.5 Fr. miniresectoscope may improve outcomes during resectoscopy





47th AAGL Global Congress on MIGS
MGM Grand Hotel and Conference Center
Las Vegas, Nevada
November 11-15, 2018
Registration Now Open!



 The 26th World Congress on
Controversies in Obstetrics,
Gynecology & Infertility (COGI)
All About Women's Health
November 23-25, 2018 • London, UK

 Celebrating
40
years
of IVF



IHC 2018
Regional GCH Asia Pacific International Hysteroscopy Congress
Dates - 1st & 2nd December 2018
Venue - The Leela Ambience Gurugram Hotel & Residences, Gurugram, Haryana | New Delhi, India

Endorsed By -   



 **travel nexus.**
nature friendly

**GLOBAL CONGRESS
ON HYSTEROSCOPY**
BARCELONA 30 April - 3 May 2019

Hysteroscopy Newsletter is an opened forum to all professionals who want to contribute with their knowledge and even share their doubts with a word-wide gynecological community



FIND US ON

[hysteroscopy_newsletter](#)

[www.facebook.com/hysteronews](#)

[www.twitter.com/hysteronews](#)

[Hysteroscopy newsletter](#)

[HYSTEROscopy group](#)


[Hysteroscopy newsletter](#)

[www.medtube.net](#)

HYSTEROSCOPY Editorial team

The “unstoppable” Hysteroscopy Newsletter NET





hysteroscopy_newsletter

98 publicaciones 1.039 seguidores 21 seguidos


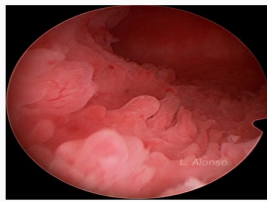

www.hysteroscopynewsletter.com

PUBLICACIONES

IGTV

GUARDADAS

ETIQUETADAS







HYSTEROSCOPY
NEWSLETTER

HysteroneWS 1K

@hysteroneWS

Tweets

3.831

Siguiendo

999

Seguidores

1.104





HYSTEROSCOPY
NEWSLETTER

Hysteroscopy Lap

Actualizar información

Registro de actividad

Biografía

Información

Amigos 2.443

Fotos

Archivo

Más