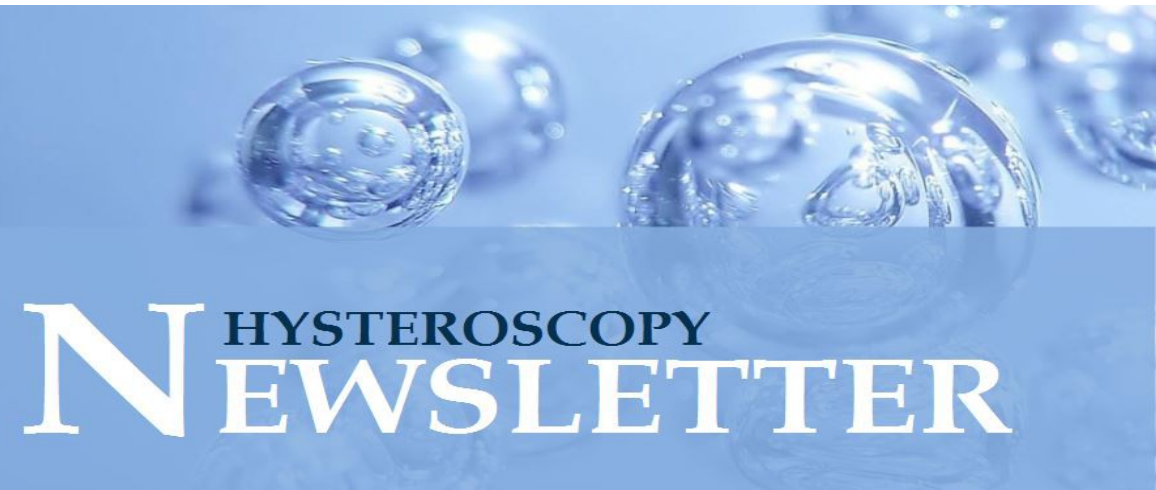



From the time of Commander Pantaleoni in 1869 when he hysteroscopically used silver nitrate to cauterize a uterine haemorrhagic polyp, to the invention of the Hopkins rod-lens system and light source, hysteroscopy has seen a quantum leap in its practice and widespread availability. Miniature telescopes are now readily available ensuring that hysteroscopy can safely be performed in an office setting without anaesthesia, thanks to the pioneering effort of Professor Stefano Bettocchi. The various recent devices for operative hysteroscopy have also made for a seamless practice.

Hysteroscopy is gradually finding “a voice” within the American Association of Gynecologic Laparoscopists (AAGL) and other professional gynaecological associations worldwide. In 2018 for example, the AAGL Board of Directors granted approval for its first Global Hysteroscopy Summit, which held in the city of Toronto, Canada, chaired by the energetic Professor Linda Bradley. Most of us had an unforgettable experience in Barcelona in 2017, where the “three musketeers” (Tinelli, Haimovich, and Alonso) brought together opinion leaders in the field of hysteroscopy for what was truly a remarkable meeting. It was the first of its kind and ultimately projected hysteroscopy to its rightful place in the scheme of things.

Africa is definitely not left behind in this great match towards placing hysteroscopy on a pedestal. I remember back in 2010 when I set up a private practice which I chose to call Gynoscope (Gynaecology and endoscopy) primarily because of my passion for minimal access surgery, especially hysteroscopy. It can even be argued that the bulk of the patients requiring hysteroscopy services reside in Africa. A cursory look at some of the indications might attest to this. One of the commonest indications for hysteroscopy is uterine synechiae. Most African countries have restrictive abortion laws, leading to an unacceptably high unsafe abortion rates and its sequelae which includes synechiae. Uterine fibroids, another common indication for hysteroscopy, is known to be commoner among the black population. For these reasons, the average gynaecologist in Africa is very much interested in developing his/her hysteroscopy skills. This fact will surely be manifested during the forthcoming Global Congress on Hysteroscopy, where there will be a large African, albeit, Nigerian contingent.

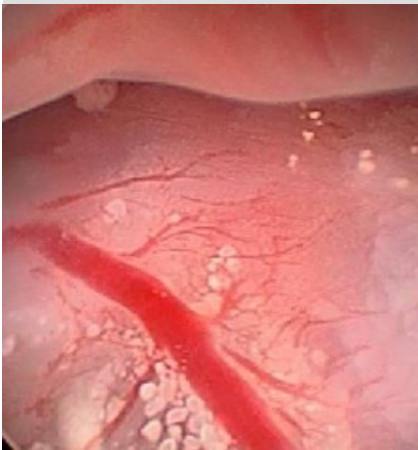I recently teamed up with an Egyptian “magician” (Professor Osama Shawki) and our desire is to spread the knowledge of hysteroscopy across Africa. For now, I invite my hysteroscopy friends to Nigeria for our Association of Gynaecological Endoscopy Surgeons conference, in September 2019. It promises to be unique.



Jude E. Okohue

Medical Director: Gynoscope Specialist Hospital  
Minimal Access Surgery unit, Madonna University Teaching Hospital  
Rivers State, Nigeria

INSIDE THIS ISSUE



	1
Welcome	2
Hysteroscopy Pictures Cervical microcalcifications	3
Interview of the month T. Justin Clark	5
Global Congress BCN	6
Back to basics Hysteroscopic fluid Management (II)	9
Original Article Endometrial scratching	15
Logo Contest	16
Original Article Microcolpohysteroscopy	

TEAM COORDINATOR  
SPAIN  
L. Alonso

## EDITORIAL COMMITTEE

SPAIN  
E. Cayuela  
L. Nieto

ITALY  
G. Gubbini  
A. S. Laganà

USA  
J. Carugno  
L. Bradley

MEXICO  
J. Alanis-Fuentes

PORTUGAL  
J. Metello

ARGENTINA  
A. M. Gonzalez

VENEZUELA  
J. Jimenez

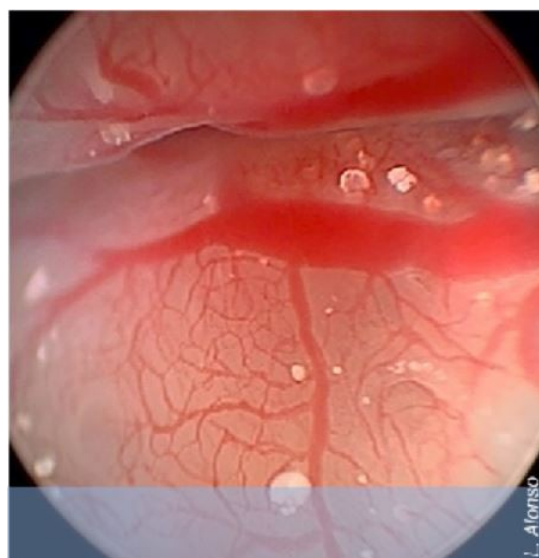
## SCIENTIFIC COMMITTEE

A. Tinelli (Ita)  
O. Shawki (Egy)  
A. Úbeda (Spa)  
A. Arias (Ven)  
M. Rodrigo (Spa)  
A. Di Spiezio Sardo (Ita)  
E. de la Blanca (Spa)  
A. Favilli (Ita)  
M. Bigozzi (Arg)  
S. Haimovich (Spa)  
E. Xia (Cn)  
R. Lasmar (Bra)  
A. Garcia (USA)  
N. Malhotra (Ind)  
J. Dotto (Arg)  
R. Manchanda (Ind)  
M. Medvediev (Ukr)  
M. Ellessawy (Ger)  
E. Boschetti Grützmacher (Ita)  
X. Xiang (Cn)  
G. Stamenov (Bul)  
Thiago Guazzelli (Bra)

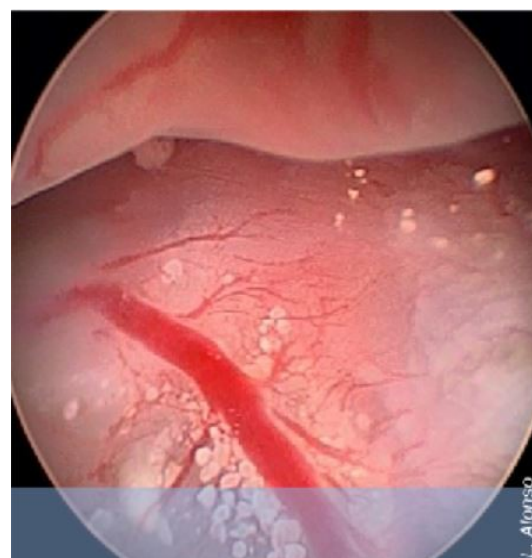
All rights reserved.

The responsibility of the signed contributions is primarily of the authors and does not necessarily reflect the views of the editorial or scientific committees.

# HYSTEROSCOPY PICTURES



*Microcalcifications in the cervical canal*



*Microdeposits following the path of blood vessels*

*It is not uncommon to find in the daily practice small hyperechogenic areas located at the level of the cervical canal when performing a pelvic ultrasound, that are seen as well-defined white spots that persist over time." The presence of microcalcifications in the cervical canal is the most frequent cause of this ultrasound finding, hyperechogenic foci seem to be more an incidental finding than an indicator of pathology. When visualized at the time of hysteroscopy, it appears as whitish areas in the cervical canal, that can be a single isolated image or a group of multiple areas that sometimes follow the path of blood vessels.*

*There are very few published studies looking at intracervical hyperechogenic foci. In a very interesting work published on endometrial and endocervical calcium micro-deposits (Duffield, C., et al. (2005). "Endometrial and endocervical micro echogenic foci: sonographic appearance with clinical and histologic correlation." J Ultrasound Med 24 (5): 583-590.) It was reported that the vast majority of patients had used hormones or IUD, had undergone interventions such as uterine curettage, spontaneous or therapeutic abortions and cesarean sections or had had an infection.*

*If you are interested in sharing your cases or have a hysteroscopy image that you consider unique and want to share, send it to [hysteronews@gmail.com](mailto:hysteronews@gmail.com)*

# INTERVIEW WITH...

Dr. T. Justin Clark, a gentleman in the hysteroscopy world. He is one of the leading UK experts in minimally invasive surgery.

**The number of hysteroscopy procedures are growing world-wide. What can we do to promote hysteroscopy?**

Several approaches are needed to encourage hysteroscopic interventions. Firstly, we need to ensure that practitioners are proficient and adopting optimal techniques. This is best achieved through the development and implementation of high-quality training programs. Secondly it is important that the best health technologies are utilised and that practitioners are aware of the available equipment and latest innovations in endoscopes, energy systems, ancillary apparatus, fluid delivery and imaging. Thirdly, hysteroscopists need to be cognisant of the evidence underpinning best practice. This needs to include an understanding for the indications for diagnostic and therapeutic hysteroscopy as well as the likely outcomes of intervention. Finally, I think disseminating best practice is of key importance. I have always found that sharing experiences at international conferences with fellow hysteroscopists to be informative and stimulating. Importantly, these interactions make me question my own practice as part of an ongoing desire to improve my performance and the outcomes for the women I look after. I am excited to be attending the second Global Congress of Hysteroscopy in Barcelona in May 2019, which is a great platform for promoting hysteroscopy.

**"Good training and a sufficient case-load is fundamental to becoming a skilled hysteroscopist"**

**Which of the latest advances in material or devices has surprised you the most?**

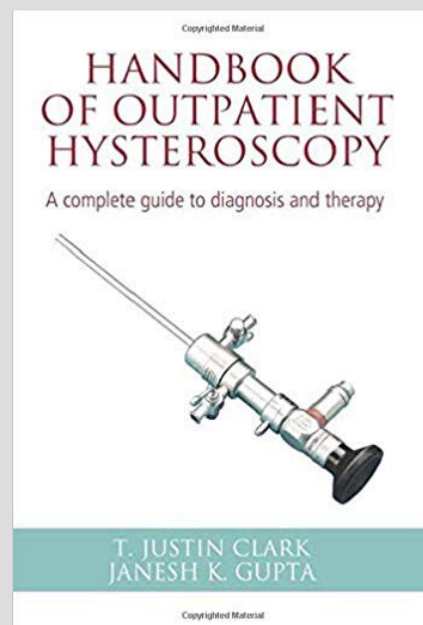
When I started hysteroscopy over 20 years ago, my practice was limited, especially in the office setting, due to a limitations in technology. Over this time mechanical instrumentation, bipolar surgery and tissue removal systems have revolutionised what we can do and the miniaturisation of equipment has opened up new settings in which to practice.

I am most excited by the development of portable systems harnessing the advances in optics and imaging. Systems like the OperaScope™ with its integrated LCD and the Endosee™ are driving forward the ability to



**T. Justin Clark**

**Consultant  
Gynaecologist and  
Professor of  
Gynaecology  
Birmingham Women's  
and Children's Hospital  
and the University of  
Birmingham, UK**



conduct hysteroscopy in a variety of settings without the paraphernalia traditionally associated with endoscopic surgery. However, the cost-effectiveness of disposable equipment and the utility of therapeutic interventions with such systems will need further evaluation.

I was disappointed to see the recent demise of hysteroscopic sterilisation, especially as its withdrawal was primarily driven by non-clinical reasons. Effective, long-term, non-hormonal contraception is important and the 'natural', non-incisional route that hysteroscopy provides to the fallopian tubes seems inherently sensible. New technologies to access the fallopian tubes utilising hysteroscopy and ultrasound and block the proximal tubes using novel inorganic and biological materials is exciting. On the latter point of biomaterials, I think the future of treating Asherman's syndrome will include the development and introduction of biological 'scaffolds', that can hold mediators and stem cells designed to prevent inflammation and scar reformation as well as stimulate endometrial regeneration.

Endometrial ablation is a highly successful procedure for heavy menstrual bleeding. I am aware of improvements to existing technologies, and the development of new technologies utilising a variety of energy systems. Choice is important for doctors and their patients and so I think the availability of properly evaluated, new products with enhanced speed, safety and portability is a good thing.

Finally, I still think we can make some sort of hysteroscopic 'fishing line' to 'hook' undermined submucosal fibroids enabling enucleation and en-bloc removal!! Oh and 'the obescope'; an extra-long hysteroscope to aid access to the uterine cavity in our more well-nourished patients!!

### **Has hysteroscopy reached its limits? What is the future of hysteroscopy?**

I think hysteroscopy will become increasingly office based driven by miniaturisation and portability of equipment and the expectations of our patients. I expect imaging to be further improved allowing more accurate and reproducible diagnosis. Whilst we can remove congenital and acquired lesions from the uterine cavity, the technologies to remove more difficult pathologies like fibroids and severe adhesions are limited and I foresee further improvements. I think we will finally solve the conundrum of hysteroscopic tubal blockage and be able to use hysteroscopy as a vehicle to deliver new biomaterials and pharmacological agents to treat problems with bleeding and reproduction.

**"Put your patients first and enjoy operating!!!"**

### **In your opinion, which is the best way to become a skilled hysteroscopist?**

Good training and a sufficient case-load is fundamental to becoming a skilled hysteroscopist. "The more I practice, the luckier I get" I think is how the saying goes. This also means that practitioners should not feel that they have to undertake the whole repertoire of hysteroscopic surgery. For example, the removal of dense adhesions or FIGO type II fibroids are difficult procedures with the potential for serious complications. Such procedures should be done by clinicians with an adequate case-load as well as the equipment and infrastructure to support the pre, peri- and post-operative care of such patients.

### **Do you have any advice for the young physician that is starting out in the world of gynecologic minimally invasive surgery?**

Too many surgical trainees treat surgery as 'a recipe', slavishly following set steps without always understanding what they want to achieve. A less rigid, more flexible and ultimately more successful approach can only be achieved with an understanding of the local anatomy and the objectives of the operations. This knowledge allows a fluidity and efficiency of movement. I would encourage trainees to observe as many surgeons as they can, mediocre and excellent alike, to better understand what great surgery looks like and how to achieve this in their own practice. Do not be afraid to learn new techniques and to make mistakes when training. The surgeons I have most admired have all had complications and did not become brilliant by chance. Overall, put your patients first and enjoy operating!!!

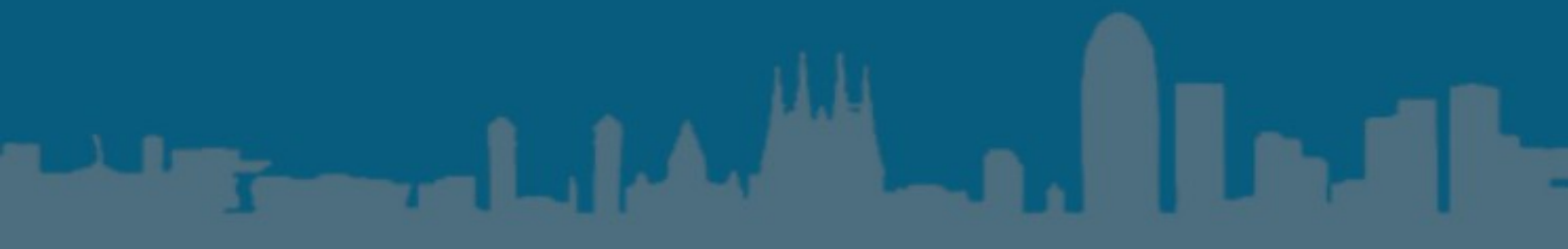

# Global Congress on Hysteroscopy

Barcelona 30 April - 3 May 2019

How to spend 4 perfect days  
learning HYSTEROSCOPY in

BAR  
CEL  
ONA



# Back to Basics

Hysteroscopy Newsletter Vol 5 Issue 1

## Hysteroscopic Fluid Management (II). A Review of the AAGL Practice Report: Practice Guidelines for the Management of Hysteroscopic Distention Media

Douglas Timmons JR MD MPH, Ashley Ulker MD, Tony Carugno MD  
Obstetrics and Gynecology Department.. Miller School of Medicine. University of Miami.USA

### REDUCING THE VOLUME OF SYSTEMIC ABSORPTION

The process of reducing the risk of distention media relation complications commences well before the procedure starts. Recognition of the types of procedures that are prone to excess media absorption will allow for preoperative measures to be put in place to avoid fluid overload. There are a number of procedures at higher risk, including those that are anticipated to take longer operating time, or those that involve dissection into the myometrium, such as resection of type 1 or type 2 leiomyomas.

Evidence shows that fluid overload in resectoscopic myomectomy is directly related to duration of the procedure, the diameter of the leiomyoma(s), and the proportion of the leiomyoma in the myometrium. The operative team should have a predetermined threshold for the intraoperative measurement of electrolytes, for the use of diuretics, and for the expeditious termination of the procedure should excess fluid absorption be detected.

#### Preoperative

Preoperative administration of GnRH agonists to reduce both the degree of systemic absorption of distending media and the potential impact of hyponatremic hypotonic encephalopathy. The preoperative use of GnRH agonists is associated with reduced fluid deficit among premenopausal women and may decrease the morbidity associated with fluid overload of nonionic hypotonic media.

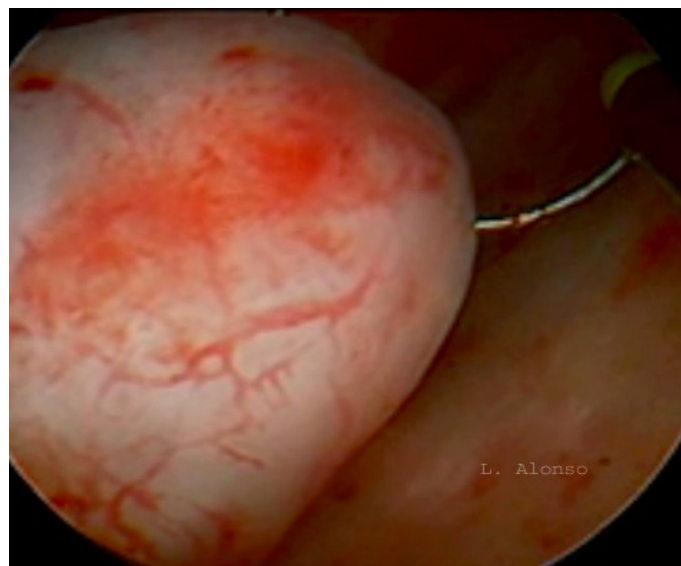#### Intraoperative

Intracervical vasopressin injection into the cervix immediately before dilation can decrease fluid absorption. Maintaining an intrauterine pressure at or below 75 mm Hg will reduce the volume of media

spilling into the peritoneal cavity via the fallopian tubes. The use of wall suction vs simple gravity for evacuation of distention media has also been shown to decrease fluid deficit. One study showed a 10-minute pause during the procedure was also shown to decrease fluid deficit. The technique used for resection or ablation of tissue may have an impact on the systemic absorption of distention media. A wire cutting loop has been shown to have higher fluid absorption compared to a RF vaporizing electrode capable of rapid conversion of large tissue volumes to gas.

### MANAGEMENT OF EXCESS ABSORPTION OF DISTENSION MEDIA

The best method of management is prevention of fluid overload via proper preoperative planning, and constant, accurate fluid monitoring intraoperatively. Cerebral edema can occur with as little as 500mL of hypotonic solution. Healthy individuals can generally tolerate up to 1000mL of absorption without



complications, however exact data is not available. If a threshold of 1000mL is reached in healthy women free of cardiovascular disease, the patient should be carefully evaluated for signs or pulmonary edema before continuing the procedure. If absorption of electrolyte-free media is a concern, place an indwelling catheter and perform intraoperative measurement of serum electrolytes and osmolality. If overload has occurred while using electrolyte-containing solution, the use of intravenous furosemide is appropriate.

### TAKE HOME POINTS

**1-** Electrolyte rich (normal saline) is the most common fluid media used for uterine distention, and allows for bipolar instrumentation use

**2-** Intracervical injection of 8 mL of a dilute vasopressin solution (0.05 U/mL) immediately prior to the procedure reduces distending media absorption during resectoscopic surgery. Such administration may also reduce the force required for cervical dilation.

**3-** Healthy individuals can generally tolerate up to 1000mL of absorption of fluid without complications, however, once the 1000mL threshold is reached, the patient should be carefully evaluated for signs of fluid overload. 2500mL is still considered absolute indication for termination of procedure.

**4-** Proper preoperative planning is crucial for avoiding fluid overload.

**5-** When available, a fluid management system should be used with an alarms set to go off when a predetermined amount of infused fluid is reached.

**6-** If overload has occurred while using electrolyte-containing solution, the use of intravenous furosemide is appropriate.

### AAGL RECOMMENDATIONS

#### Evidence Level A

**1.** Intracervical injection of 8 mL of a dilute vasopressin solution (0.05 U/mL) immediately prior to the procedure reduces distending media absorption during resectoscopic surgery. Such administration may also reduce the force required for cervical dilation. (Discussed in section: Intracervical Vasopressin)

**2.** The uterine cavity distention pressure should be the lowest pressure necessary to distend the uterine cavity and ideally should be maintained below the mean arterial pressure (MAP) (Discussed in section: Infusion and Evacuation Techniques)

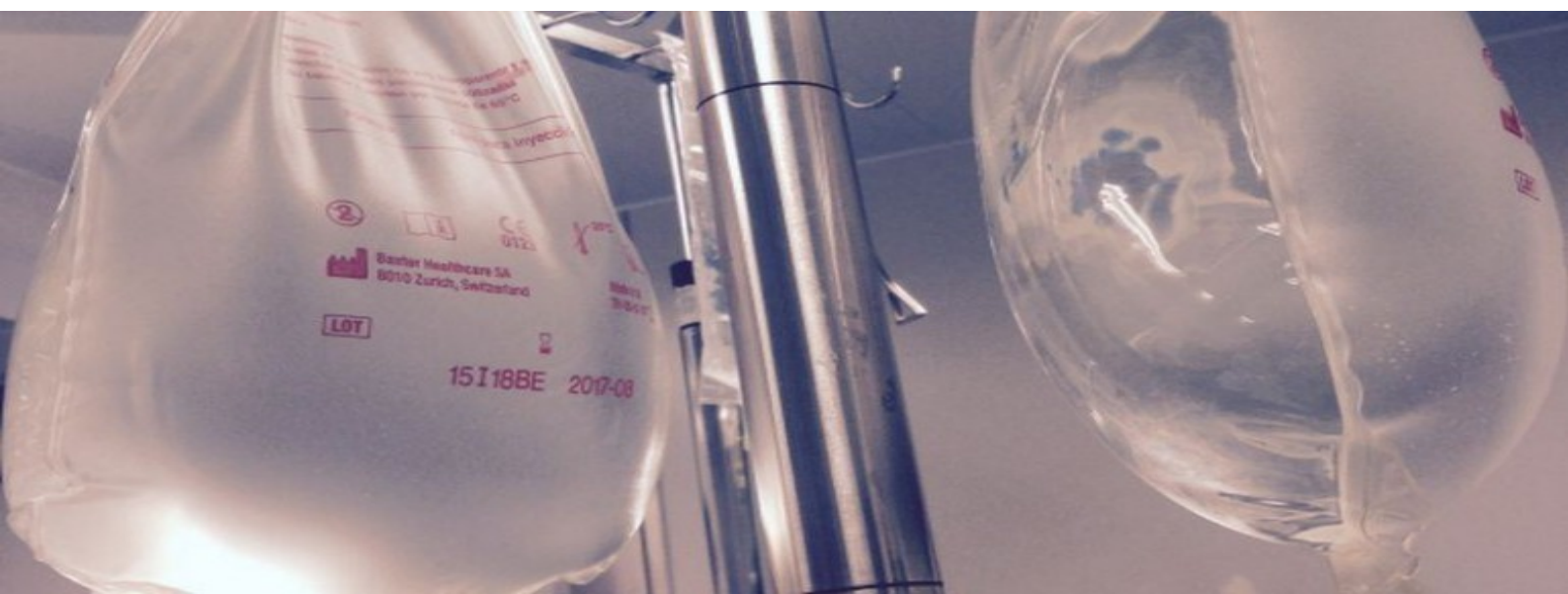#### Evidence Level B

**3.** Excessive absorption of hypotonic fluids such as glycine 1.5% or sorbitol 3% can result in fluid overload and hypotonic hyponatremia, causing permanent neurologic complications or death (Discussed in section: Mechanisms, Consequences and Incidence of Excess Fluid Extravasation: Low viscosity distention media)

**4.** The risk of hypotonic encephalopathy is greater in reproductive-aged women than in postmenopausal women. (Discussed in section: Mechanisms, Consequences and Incidence of Excess Fluid Extravasation: Low viscosity distention media)

**5.** When compared with electrolyte-free media, saline appears to have a safer profile. (Discussed in section: Managing Fluid Media: Selection of distending media)

**6.** Excessive absorption of isotonic fluids such as normal saline can cause severe complications. Although isotonic fluids do not cause cerebral edema,



there is still a mandate for continuous and accurate measurement of input and output for the calculation of fluid absorption. (Discussed in section: Managing Fluid Media: Selection of distending media)

**7.** The risk of systemic absorption varies with the procedure and increases when myometrial integrity is breached with procedures such as myomectomy. In such instances, patients should be counseled that more than one procedure may be required. (Discussed in section: Reducing the Volume of Systemic Absorption–Preoperative)

**8.** Due to the conflicting evidence regarding their impact on the volume of fluid deficit during resectoscopic surgery, the decision to use a gonadotropin-releasing hormone (GnRH) agonist in premenopausal patients to reduce extent of fluid deficit should be made at the discretion of the provider. (Discussed in section: Reducing the Volume of Systemic Absorption–Preoperative)

### Evidence Level C

**9.** CO<sub>2</sub> is a suitable medium for the performance of diagnostic hysteroscopy but should not be used for operative hysteroscopy because of its impact on hysteroscopic visualization and the risk of CO<sub>2</sub> embolus. (Discussed in section: Media types: Carbon Dioxide)

**10.** Before performing operative hysteroscopy with liquid distending medium, it is important to purge the air out of the system and during the procedure to change the liquid-containing bag before it is completely emptied. (Discussed in section: Media types: Carbon Dioxide)

**11.** The risks associated with distending media overload may be reduced by limiting the degree of preoperative hydration with oral or intravenous fluids. (No published evidence: committee recommendation)

**12.** Shortly prior to performing resectoscopic surgery, it is advisable to obtain baseline levels of serum electrolytes including sodium, chloride, and potassium in women on diuretics or with medical conditions that may predispose to electrolyte disorders.

**13.** The following statements on maximum fluid deficits are based on expert opinion. The patient should be carefully evaluated, with consideration to terminating the procedure expeditiously if intravasation is known or thought to reach the volume in these clinical contexts. For elderly patients and others with comorbid conditions including compromised cardiovascular systems, a maximum

fluid deficit of 750 mL is recommended. (Discussed in section: Management of Excess Absorption of Distending Media)

a. For healthy patients, the maximum fluid deficit of 1000 mL is suggested when using hypotonic solutions. This is based on a decrease in serum sodium of 10 mmol, with absorbed volume of around 1000 mL. The maximum limit for isotonic solution is unclear, but 2500 mL has been advocated in the previous AAGL Guidelines. Individualization and the anesthesiologist's opinion should be obtained.

b. When high-viscosity distending media are used, the maximum infused volume should not exceed 500 mL, and in the elderly and those with cardiopulmonary compromise should not exceed 300 mL.

**14.** When maximum absorption occurs with electrolyte-free distending media, immediate measurement of plasma electrolytes and osmolality is recommended. (Discussed in section: Management of Excess Absorption of Distending Media)

**15.** Normal saline should be used wherever possible for operative hysteroscopic surgery to reduce the risk of hyponatremia and hypo-osmolality. Normal saline should be used for distention during operative hysteroscopic procedures not requiring the use of monopolar electrosurgical instruments. (Discussed in section: Managing Fluid Media: Selection of distending media)

**16.** The surgical team should be prepared to accurately monitor distending fluid medium input and output, including all 3 potential sources: return from the hysteroscope, spill from the vagina, and loss to the floor. An automated system for continuous calculation of fluid deficit is recommended. (Discussed in section: Monitoring Absorption)

**17.** The use of an automated fluid management system is recommended. Such systems should ideally comprise an infusion pump that allows determination and continuous monitoring of true intrauterine distention pressure and a system for accurate measurement of fluid deficit. (Discussed in section: Reducing the Volume of Systemic Absorption; and Monitoring Absorption)

**18.** The surgical team should, prior to the start of the case, predetermine the maximum acceptable volume of systemically absorbed distending media considering both the medical condition of the patient, and the osmolality and electrolyte content of the media to be used.

# Original Article

Hysteroscopy Newsletter Vol 5 Issue 1

## ENDOMETRIAL SCRATCHING : Review Article

Dr. Sunita Tandulwadkar. Head of OBGYN Department, Ruby Hall Clinic, Pune, India

Dr. Bhavana Mittal. Director, Shivam IVF Centre, Delhi, India

### INTRODUCTION

Implantation remains a limiting step in in vitro fertilization (IVF) as well as intra cytoplasmic sperm injection (ICSI). Many procedures have been tried to improve the implantation rate in IVF/ICSI cycles. Endometrial injury is one of these procedures that has gained popularity in the past few years.

### DEFINITION

Endometrial scratching or injury is defined as intentional damage to the endometrium, in women undergoing assisted reproduction technology (ART) to improve endometrial receptivity (1)

It is also known as endometrial scratch, endometrial manipulation, controlled endometrial trauma, intentional endometrial injury, mechanical endometrial stimulus. The first non-randomized paper suggesting this association was published in 2003 (2A). More than a decade later, there is not yet agreement about what degree of injury is required, the number of injuries to be performed (one, two or more), at what day or phase of the menstrual cycle the procedure must be performed, the time that should elapse between the endometrial injury and the embryo transfer cycle, or even whether it might work or not in the unselected population or/and in patients with previous failures.

### BIOLOGICAL PLAUSIBILITY OF THE INTERVENTION

Biological plausibility must be the 'primum movens' of any new intervention. What are the underlying hypothesis that have been suggested to be involved in the unknown mechanism mediating endometrial receptivity acting through endometrial injury?(2B)

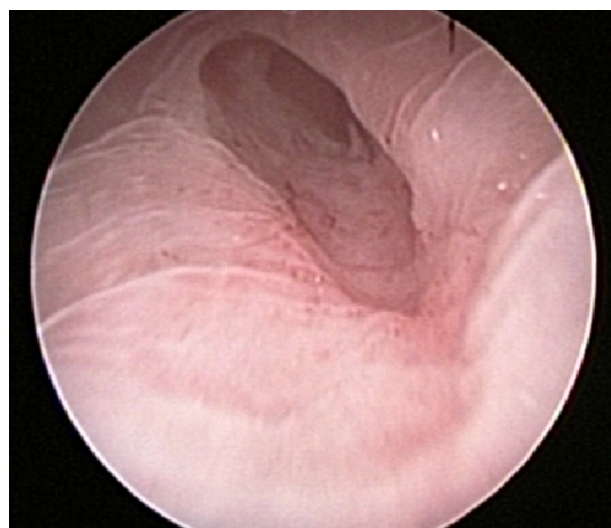
The first theory suggests that the mechanism involves inducing decidualization of the endometrium, which might improve the implantation of the transferred embryos. – (22)

The second theory suggests that the process of healing after endometrial injury involves an inflammatory reaction mediated with cytokines, interleukins, growth factors, macrophages and dendritic cells, which are beneficial to embryo implantation.- (4)

The third theory suggests that endometrial injury in a previous cycle leads to better synchronicity between the endometrium and transferred embryos through retarding endometrial maturation. – (23)

### HOW TO PERFORM IT?

After proper written informed consent, patient is asked to lie on the table for a routine pelvic examination. No analgesics are given before the procedure. Sims speculum is inserted, and anterior lip of cervix held with Allis forceps. The cannula is inserted gently through the cervical canal into the uterine cavity and advanced slowly till just resistance felt. Gentle movement of endometrial aspiration cannula (endocell) along all four walls of the uterine cavity is performed. Within 10 min after the procedure, the women are asked to quantify the



degree of pain experienced during the procedure with the help of a visual analog scale (VAS). No antibiotics are prescribed to patients after the procedure.

### WHICH INSTRUMENTS TO USE?

- Pipelle endosampler catheter (2A,2B)
- Endometrial aspiration canula(13)
- Endometrial curette(20)
- Intra uterine contraceptive device (IUCD)
- Insertion tube(21)
- Infant feeding tube(21)
- Tao brush(18)

### WHAT DEGREE OF INJURY IS REQUIRED?

- Fundus and the posterior wall of the uterine cavity were scratched three times(2b)
- Gentle movement of endocell around all four walls of uterus(13)
- Mild local injury by pipelle on posterior wall(17)
- Tao brush, rotating it 4–5 times collecting tissue from entire uterine lining(18)
- Small biopsies from anterior and posterior wall(19)

### WHEN TO PERFORM IT?

It was observed that endometrial injury improves pregnancy outcomes not only when done in luteal phase of preceding cycle but also when done in follicular phase of the same cycle. (17,18)

Moderate-quality evidence indicates that endometrial injury performed between day 7 of the previous cycle and day 7 of the embryo transfer (ET) cycle is associated with an improvement in live birth and clinical pregnancy rates in women with more than two previous embryo transfers. (1)

In COS/IUI cases, performing endometrial scratching in follicular phase of the same cycle instead of luteal phase of previous cycle has two advantages. It is more convenient for the women to undergo scratching after transvaginal ultrasound for folliculometry in the same cycle, thus avoiding the need to come in the cycle before IUI. (19, 21) There is a theoretical advantage of a recent inflammatory response and release of cytokines in the same cycle that may lead to better implantation. The procedure has shown more benefit in late follicular (D6-7) phase than early follicular phase.(13)

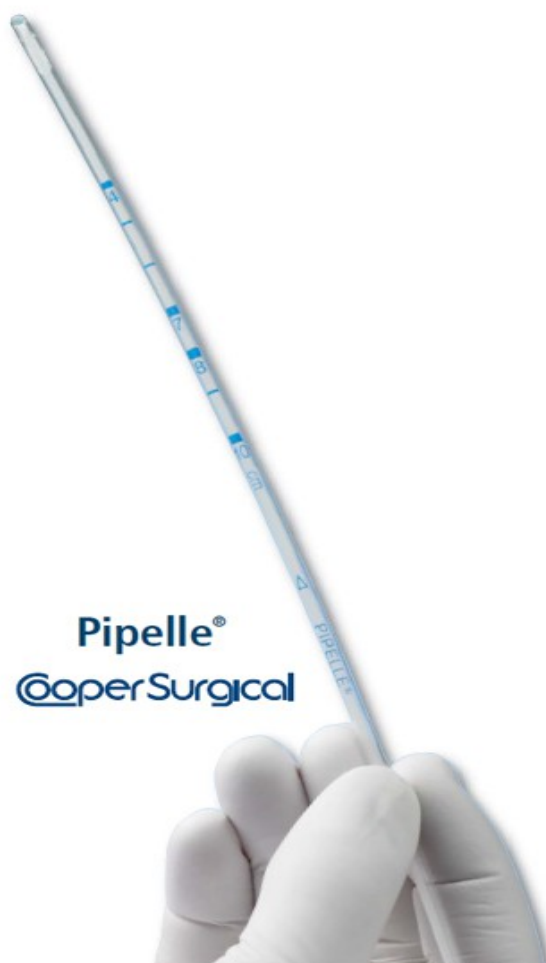### WHAT IS THE NUMBER OF INJURIES REQUIRED?

There is no consensus regarding the optimal number of endometrial injuries. In some studies, endometrial injury was( 3,2A) performed only once. Endometrial injury was performed twice in other studies.(4)

### ROLE OF HYSTEROSCOPY

Interestingly, hysteroscopy was included as another way of 'injuring' the endometrium in some studies, (14,2) although it is not included in the definition of scratching in the Cochrane database. Hysteroscopy is not an intervention performed to scratch the endometrium, rather it is used to treat endometrial pathologies that can interfere with embryo implantation. Therefore, any results from patients with endometrial 'injury' induced in this way must be related back to the primary objective of the hysteroscopic treatment rather than to any secondary scratching resulting from the intervention. Other benefits of hysteroscopy beyond the possible 'injury' effect are the correction of unsuspected intrauterine abnormalities in asymptomatic IVF patients prior the cycle, reported to be as high as 12-50% (11,15,16). Also, the assessment of the cervical conditions of the patient to achieve an easier embryo transfer and a more friendly embryo replacement (14). Therefore, studies based on hysteroscopy should not be combined with those exclusively based on endometrial biopsy to analyze the scratching effect.





## IS THERE A POPULATION THAT WOULD PARTICULARLY BENEFIT FROM ENDOMETRIAL SCRATCHING?

### IVF /ICSI

Cochrane(2015) authors included 14 clinical trials (2128 women) evaluating the effects of endometrial injury on outcomes of ART. Thirteen of these trials studied endometrial injury during the menstrual cycle before embryo transfer. One trial studied endometrial injury on the day of oocyte retrieval, which is just a few days before the day the embryo is transferred into the womb. The included studies suggest that endometrial injury performed sometime during the month before the start of ovarian stimulation as part of ART improves the chances that a woman will achieve live birth and clinical pregnancy. Moderate-quality evidence suggests that if 26% of women achieve live birth without endometrial injury, between 28% and 48% will achieve live birth with this intervention. Contrary to this, endometrial injury performed on the day the eggs are picked up reduces the chances of pregnancy.(6-10)

If ES can influence this success rate, there would be a significant cost saving through decreasing the number of IVF/ICSI cycles necessary to achieve a pregnancy. This will increase the practice of single embryo transfer and consequently have a large impact on risks and costs associated with multiple pregnancies.(5)

### RECURRENT IMPLANTATION FAILURE (RIF)

Mechanical endometrial injury (biopsy/scratch or hysteroscopy) in the cycle preceding ovarian stimulation for IVF has been proposed to improve implantation in women with unexplained recurrent implantation failure (RIF). In a systematic review and meta-analysis of studies comparing the efficacy of endometrial injury versus no intervention in women with RIF undergoing IVF, (12) all controlled studies of endometrial biopsy/scratch or hysteroscopy performed in the cycle preceding ovarian stimulation were included and the primary outcome measure was clinical pregnancy rate. Pooling of seven controlled studies (four randomized and three non-randomized), with 2062 participants, showed that local endometrial injury induced in the cycle preceding ovarian stimulation is 70% more likely to result in a clinical pregnancy as opposed to no intervention. There was no statistically significant heterogeneity in the methods used, clinical pregnancy rates being twice as high with biopsy/scratch (RR 2.32, 95% CI 1.72–3.13) as opposed to hysteroscopy (RR 1.51, 95% CI 1.30–1.75). The evidence is strongly in favour of inducing local endometrial injury in the preceding cycle of ovarian stimulation to improve pregnancy outcomes in women with unexplained RIF.

No effect was found in women undergoing frozen-thawed ET cycles.

### COS + IUI CYCLES

Cochrane (2015) review (1) concluded that it is uncertain whether endometrial injury improves the probability of pregnancy and live birth/ongoing pregnancy in women undergoing IUI or attempting to conceive through sexual intercourse.

However, some small studies have indicated that endometrial scratching is a cost-effective and easy technique which may improve clinical pregnancy rates in previous COS failure cycles, but more trials are needed to be conducted using larger sample size to achieve the improved and significant outcome.(13)

## SIDE EFFECTS

We are still uncertain about the effect of endometrial injury on adverse events such as miscarriage, multiple pregnancy or vaginal bleeding. However, the endometrial injury procedure does appear to cause some pain, although this is short lived.

A prospective study included 361 participants. A total of 22 patients refused to take part in the study. Three patients were excluded from the intervention group, because they experienced severe pain during the procedure, and therefore, endometrial scratching was discontinued. Apart from these three patients, no other patient reported moderate or severe pain during the procedure. None of the patients reported infection or heavy bleeding after the procedure. There was no disturbance in the menstrual cycle other than minimal vaginal spotting for a few days after the procedure.

In all above-mentioned studies, even after endometrial scratching, ET on the day of trigger was comparable between intervention and control group.

## CONCLUSIONS

Endometrial injury is a simple, low-cost procedure which can be performed on an outpatient basis. More than 300 publications can be found on this topic, but only four RCTs with poor quality were analyzed in three meta-analyses published in the same year. Interestingly, all of them conclude that endometrial scratching prior to starting IVF treatment may improve the chance of embryo implantation and IVF success rate, although this simple intervention would benefit from well-conducted randomized trials.

Although current evidence suggests some benefit of endometrial injury, we need evidence from well-designed trials that avoid instrumentation of the uterus in the preceding three months, do not cause endometrial damage in the control group, stratify the results for women with and without recurrent implantation failure (RIF) and report live birth.

Its benefit in women with repeated COS failure cycles or couples trying to conceive with IUI and OI remain unclear. If endometrial injury improves reproductive outcomes in this situation, it could provide a low-cost treatment alternative for some couples before they consider undergoing IVF. Studies have shown a slight increase in pregnancy outcome in women with repeated COS failures undergoing endometrial scratching in late follicular phase, but the result was not statistically significant. Larger and adequately powered studies are needed to elucidate the effects of endometrial scratching on the outcome of repeated failed COS cycles.

This intervention must not be advertised as an established practice to improve implantation until real good data demonstrate that it does and biological plausibility is demonstrated.

## REFERENCES

1. [https://cochrane.org/CD009517/MENSTR\\_endometrial-in](https://cochrane.org/CD009517/MENSTR_endometrial-in)
- 2A. Barash A, Dekel N, Fieldust S, Segal I, Schechtman E, Granot I, et al. Local injury to the endometrium doubles the incidence of successful pregnancies in patients undergoing *in vitro* fertilization. *Fertil Steril*. 2003;79:1317–22.
- 2B. Bakshi R, Jha B, Prakash R. The impact of endometrial scratching on the outcome of *in vitro* fertilization cycles: A prospective study. *Fertil Sci Res* 2016;3:80–6
3. Kumbak B et al (2014) Impact of luteal phase hysteroscopy and concurrent endometrial biopsy on subsequent IVF cycle outcome. *Arch Gynecol Obstet* 290(2):369–374
- 4- Gnainsky Y, Granot I, Aldo PB, Barash A, Or Y, Schechtman E et al. Local injury of the endometrium induces an inflammatory response that promotes successful implantation. *Fertil Steril* 2010;94:20306.
5. Induced endometrial trauma (endometrial scratch) in the mid-luteal menstrual cycle phase preceding first cycle IVF/ICSI versus usual IVF/ICSI therapy: study protocol for a randomised controlled trial
6. Karimzade MA, Oskouian H, Ahmadi S, Oskouian L. Local injury to the endometrium on the day of oocyte retrieval has a negative impact on implantation in assisted reproductive cycles: A randomized controlled trial. *Arch Gynecol Obstet*. 2010;281:499–503.
7. Narvekar SA, Gupta N, Shetty N, Kottur A, Srinivas M, Rao KA. Does local endometrial injury in the nontransfer cycle improve the IVF-ET outcome in the subsequent cycle in patients with previous unsuccessful IVF? A randomized controlled pilot study. *J Hum Reprod Sci* 2010;3:15–9.
8. Nastri CO, Gibreel A, Raine-Fenning N, Maheshwari A, Ferriani RA, Bhattacharya S, et al. Endometrial injury in women undergoing assisted reproductive techniques? *Cochrane Database Syst Rev*. 2015;3:CD009517. doi: 10.1002/14651858.
9. El-Toukhy T, Sunkara S, Khalaf Y. Local endometrial injury and IVF outcome: A systematic review and meta-analysis. *Reprod Biomed Online*. 2012;25:345–54.
10. Potdar N, Gelbaya T, Nardo LG. Endometrial injury to overcome recurrent embryo implantation failure: A systematic review and meta-analysis. *Reprod Biomed Online*. 2012;25:561–71
11. Scratching beneath 'The Scratching Case': systematic reviews and meta-analyses, the back door for evidence-based medicine Carlos Simón, José Bellver *Human Reproduction*, Volume 29, Issue 8, 1 August 2014, Pages 1618–1621
12. Endometrial injury to overcome recurrent embryo implantation failure: a systematic review and meta-analysis *J Hum Reprod Sci*. 2018 Jan-Mar; 11(1): 59–71.
13. Therapeutic Efficacy of Endometrial Scratching in Repeated Controlled Ovarian Stimulation (COS) Failure Cycles Leena Wadhwa and Mona Mishra
14. *Reprod Biomed Online*. 2014 Feb;28(2):151–61. Doi: 10.1016/j.rbmo.2013.09.025. Epub 2013 Oct 5.
15. Bakas et al, Role of Hysteroscopy Prior to Assisted Reproduction Techniques. *Journal of Minimally Invasive Gynecology*, March–April 2014, Pages 233–237
16. Prevalence of unsuspected uterine cavity abnormalities diagnosed by office hysteroscopy prior to *in vitro* fertilization. H.M. Fatemi J.C. Timmermans J. van Disseldorp B.C. Kasius A. *Human Reproduction*, Volume 25, Issue 8, 1 August 2010, Pages 1959–1965
17. Parsanezhad ME, Dadras N, Maharlouei N, Neghaban L, Keramati P, Amini M, et al. Pregnancy rate after endometrial injury in couples with unexplained infertility: A randomized clinical trial. *Iran J Reprod Med* 2013;11:869–74
18. Abdelhamid AM. The success rate of pregnancy in IUI cycles following endometrial sampling. A randomized controlled study: Endometrial sampling and pregnancy rates. *Arch Gynecol Obstet* 2013;288:673–8.
19. Zarei A, Alborzi S, Dadras N, Azadi G. The effects of endometrial injury on intrauterine insemination outcome: A randomized clinical trial. *Iran J Reprod Med* 2014;12:649–52.
20. Rasheed FA. The effect of single endometrial curettage on pregnancy rate in unexplained infertility in primary care setting. *Br J Med Med Res* 2014;4:3158–66.
21. Nossair WS, El Behery MM, Farag MS. Endometrial scratch-suction and implantation failure. *Open J Obstet Gynecol* 2014;4:217–27
22. Cellular and Molecular Neurobiology June 2009, Volume 29, Issue 4, pp 455–473. De-differentiation Response of Cultured Astrocytes to Injury Induced by Scratch or Conditioned Culture Medium of Scratch-Insulted Astrocytes. Hao Yang et al
23. Lass A, Peat D, Brinsden P. Histological evaluation of endometrium on the day of oocyte retrieval after gonadotrophin-releasing hormone agonist-follicle stimulating hormone ovulation induction for *in-vitro* fertilization, *Hum Reprod*, 1998, vol.13 (pg.3203–3205)

# HYSTEROSCOPY DEVICES

The essence of performances

## iCare

Our camera uses a CMOS HD sensor with more than 2 million pixels. Needless to mention resolution plays can be ensured.

Our light source uses the latest LED technology and provides exceptional light output, even with small optics. It guarantees an outstanding depth of field under any circumstances, and its homogeneity is such that even the periphery of your image will be bright. Finally, thanks to its daylight color temperature, obtain the best possible color fidelity. Benefit in your consultation room from the technologies and performances of the operating room!



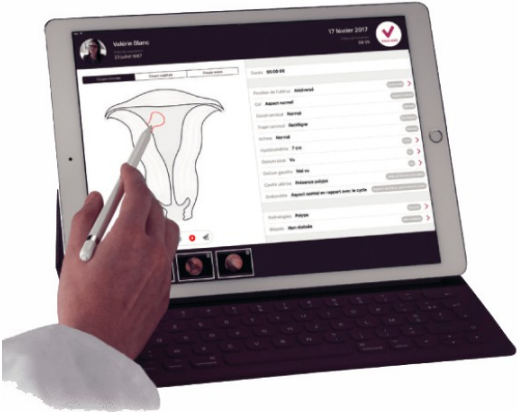<https://www.delmont-imaging.com>



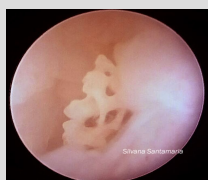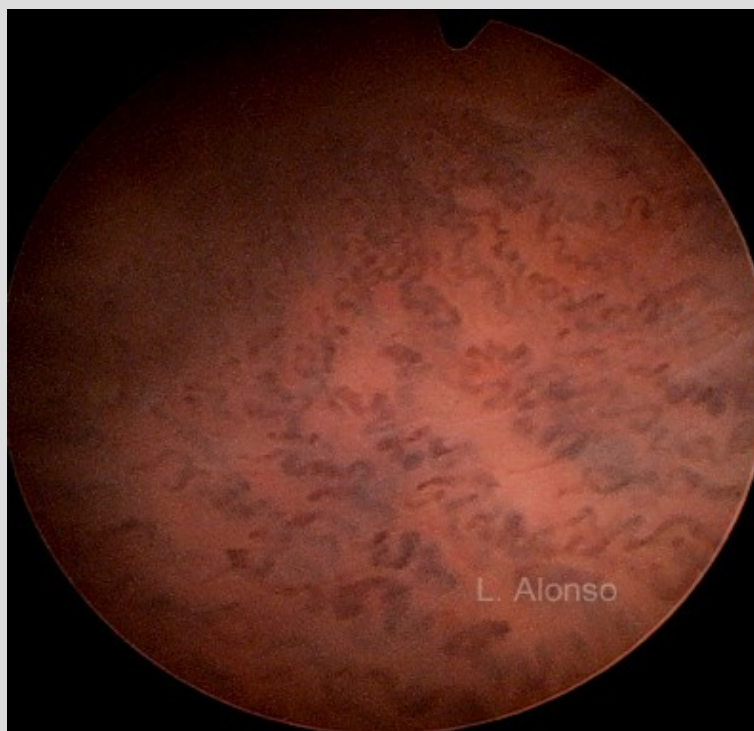A long pressure is required on this button to activate a white balance, protecting your exams from involuntary actions.

Change the power of the light source between two pre-programmed light intensities to easily adapt to any situation.

Trigger your photos and videos from this button. You can even take pictures during video recording.




# WHAT'S YOUR DIAGNOSIS?



*Answer to last edition:*

*Osseous metaplasia*



## Hysteroscopy

A. Tinelli, L. Alonso & S. Haimovich  
2018 Springer

This book offers a cutting-edge guide to hysteroscopy and provides readers with the latest and most essential information on procedure techniques, clinical advances and international developments in practice and treatment of endometrial pathology. Providing comprehensive coverage, it explains in detail every aspect of hysteroscopy, from diagnostics to hysteroscopic surgery. As such, it addresses the bases of hysteroscopy; pre-, intra- and post-hysteroscopy medications; intracavitary pathologies; fertility issues; and surgical implications and complications. At the same time, it also explores challenging and controversial topics, such as hysteroscopy and ART, submucous myomas, and uterine malformations.

# Logo Contest

It is a great honor to announce the winner of the May 2nd International Hysteroscopy Day (#May2IHD) Logo contest. We received several very well-designed logos. The hysteroscopic community voted and the winner is Dr Thomas Moscovitz from Brasil. Congratulations!!!

He won a free registration to the Global Congress. A special thanks to all our colleagues who sent their arts to participate in this great contest. Thank you to all of you for voting. Please congratulate Dr Moscovitz for winning the contest!!!  
We will see you in Barcelona!!!!

The May2IHD team



**First Place** with 1096 points: Dr *Thomas Moscovitz*. **Brasil**



**Second Place** with 1000 points:  
Dr *Luigi Montevvecchi*. **Italy**



**Third Place** with 997 points:  
Dr *Jorge Dotto and Miguel Bigozzi jr.* **Argentina**

# Original Article

Hysteroscopy Newsletter Vol 5 Issue 1

## Microcolpohysteroscopy: Technique for the early diagnosis of cervical disease

Dr. Hiram Humberto Castillo Villatoro, Professor and Deputy Secretary of the International Microcolpohysteroscopy Association (IAMCH), Guatemala, Central America.

### MICROCOLPOHYSTEROSCOPY

Technique designed for the study of Cervical Pathology, developed through the colpomicroscope of Antoine and Grunberger in 1949 in Austria subsequently modified by Jacques Hamou in Paris France in 1980.

### MICROCOLPOHYSTEROSCOPE

The original instrument is a 25 cm long endoscope, provided with a 90 degree angle lens, with 30 degree oblique panoramic visualization as contact at different magnifications, with a diameter of 4 mm with optional diagnostic external sheath of 5.2 mm diameter and an operative 7 mm sheath provided with a 5 French working channel. It comes with two eyepieces with four magnifications; in the axis of the optics is the direct eyepiece with magnifications for panoramic vision of 1X and colposcopic of 20X and of contact of 60X magnification. Another lateral eyepiece for cellular vision in vivo at 150X of magnification (Figure 1).

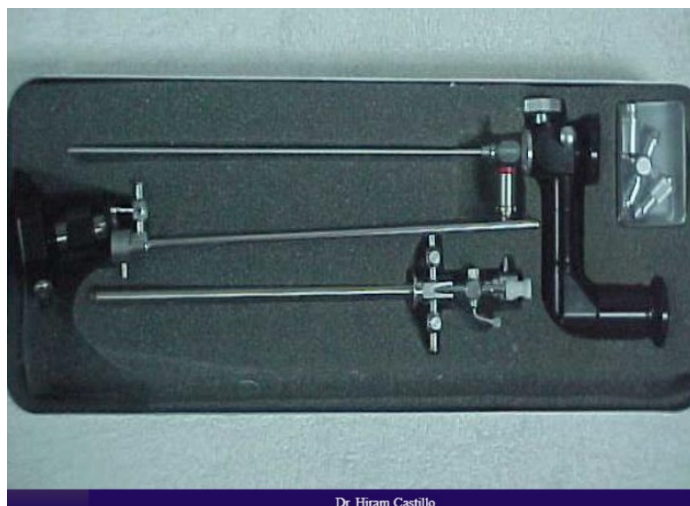

Figure 1: Microcolpohysterospe

Currently, a 30 cm long endoscope is also available. With a single direct eyepiece with a panoramic view of 1X and an in vivo cell vision of 80X, with zoom it can reach up to 100X, with a diameter of 3 mm and a 4 mm diagnostic sleeve. This endoscope is frequently also used for hysteroscopy (Figure 2).




Figure 2: Modern microcolpohysteroscope

### COMPLEMENTARY ITEMS

- 1- Endoscopic camera
- 2- HD Monitor
- 3- Zoom (optional)
- 4- Color photo printer
- 5- Hystero CO2 insufflator
- 6- Zenon light source from 150 to 300 Wtz. (cold light)

## VITAL DIES

Waterman blue, Acidophilus solution (PH 5), colors the basal cells and the first cylindrical papillae exposed to the vaginal pH.

Lugol solution at 2%, highlights cells that contain glycogen.



Dr. Hiram Castillo

## PROCEDURE TECHNIQUE

After cleaning the cervix with normal saline to remove cell debris and excess cervical mucus, proceed to apply 2% Lugol to the cervix, it will be easy to visualize the cells provided with glycogen, then apply Waterman Blue dye, to visualize basal cells and the prolongation of them towards the external and internal margins of the exocervix, transformation zone, squamocolumnar junction and the first papillae of the cylindrical epithelium, such as the migration of the abnormal basal epithelium towards the endocervical canal, this is done with the support of the hystero CO2 insufflator at a pressure of 15 to 20 ml/min.

To allow a clear view of the field and to facilitate the dilation of the endocervical canal, the procedure is performed introducing only the beveled distal tip of the microcolpohysteroscope in the endocervical canal up to the internal os, reaching the squamous columnar junction visualizing the transformation zone, starting in the posterior cervix following with clockwise rotation from 3 o'clock quadrants, in the presence of bleeding which can make visualization and orientation difficult, identifying the iodine-negative zones and the areas with the highest concentration of Waterman's Blue facilitate the procedure.

When using the Hamou I microcolpohysteroscope, which has both eyepieces and four magnifications, It is possible to visualize the following:

**Magnification of 1X:** Conventional panoramic view, allows to perform an endocervicoscopy.

**Magnification of 20X:** Similar to colposcopy, locate areas of iodine-negative transformation.

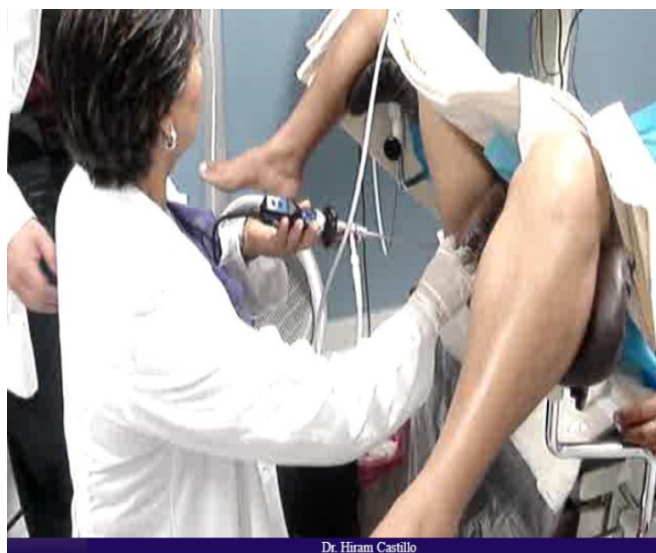**Magnification of 60X:** Visualize the basal epithelium in architecture, topography, location, extension, distribution of glandular structures and vascularization. This phase is the most appropriate to perform rapid and complete visualization of the cervix identifying suspicious areas.

**Magnification of 150X:** Allows visualization of the nucleus-cytoplasm ratio as well as their characteristics, this power of magnification is what allows to make the diagnosis and direct the biopsy.

When using the Hamou II microcolpohysteroscope, which has only one eyepiece and two magnifications, we visualize:

**Magnification of 1X:** Conventional panoramic view, allows to perform endocervicoscopy.

**Magnification of 80X:** Allows to visualize the nucleus-cytoplasm ratio and their characteristics, allowing diagnosis and direct biopsy.



Dr. Hiram Castillo

## NORMAL TRANSFORMATION ZONE:

The transformation zone (TZ) is defined as the union between the edges of the mature squamous epithelium and the margin of the columnar epithelium. It is on average 2 mm wide and very regular, so the complete visualization is obtained by rotation of the optics, being totally included in

the visual field, following a clockwise rotation and visualizing all four quadrants, however, on occasions, it can be wider and more irregular due to physiological metaplastic processes, it is sometimes necessary to repeat the application of Waterman's Blue ink inside the endocervical canal.

The TZ is formed by metaplastic cells that in their more immature phase are observed coating the endocervical papillae, the parabasal, basal and intermediate cell lacking glycogen, do not take the lugol staining and become stained only with waterman blue ink, it is observed as a blue strip with 2 margins;

**Internal margin** (squamous-columnar junction) represented by squamocolumnar junction is irregular and ill defined by metaplastic processes.

**External margin** (squamous-squamous junction) formed by edges with mature cells stained by lugol more externally located and of lesser maturity with blue coloration at the internal margin. (Fig. 3)

### NORMAL SQUAMOUS EPITHELIUM

With the application of Lugol stain and Waterman's Blue ink, superficial cells with small, picnotic nuclei are easily visualized, assessing their horizontal disposition and characteristics of normality, in their nucleus-cytoplasmic ratio, assessing the hormonal status according to their mature status, as we go further towards the outside or periphery it is observed a more advanced mature cells with their membranes close to each other forming intercellular bridges, acquiring the dark Lugol stain, eventually with keratinization processes, where the nuclei are well defined, even not visible (Fig. 4).

### NORMAL COLUMNAR ENDOCERVICAL EPITHELIUM:

The cubic papillae that are in contact with the exocervix, are the only ones that can capture the stain of the waterman blue dye, because they have less capacity to secrete mucus, the rest of the epithelium inside the endocervical canal does not capture it, with the microcolpohysteroscope, allows to visualize the size of the papillae as well as the vascularization (Fig. 5 and 6).

### ABNORMAL TRANSFORMATION ZONE:

The change from the normal squamous epithelium to the atypical epithelium is clearly visualized with

Fig. 3

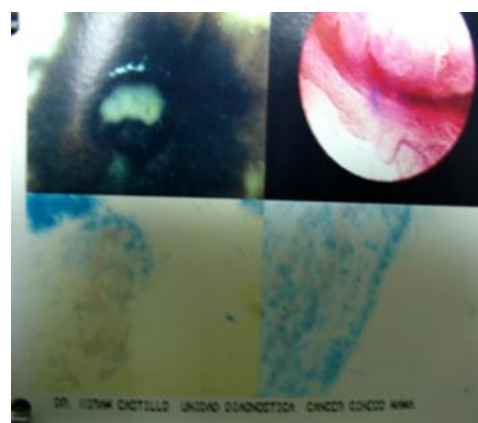

Fig. 4

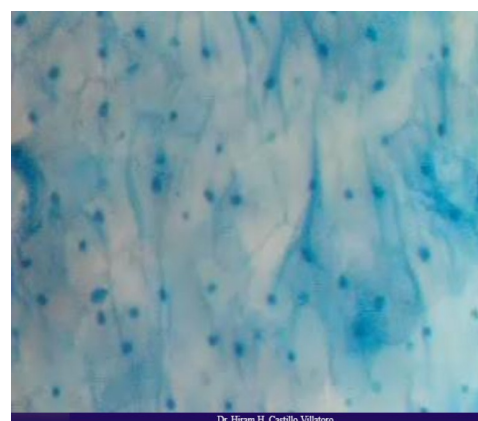


Fig. 5

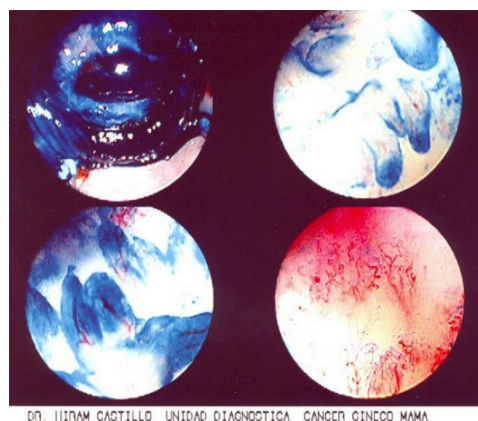
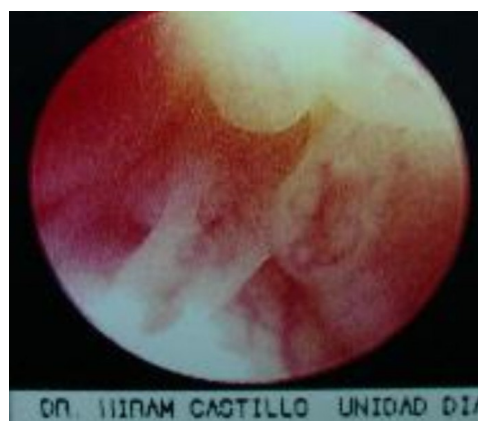


Fig. 6



the microcolpohysteroscope, easily identifying the limits of the lesion, locating the area of greatest topographic, architectural, cellular and vascularization alteration, allowing to perform the biopsy of that exact area, avoiding collecting biopsies from normal areas.

Microcolpohysteroscopic aspects of the abnormal transformation zone

- Loss of normal architecture.
- Altered cytoplasmic/nucleus ratio; the cytoplasm capturing the waterman blue ink decreases in diameter in relation to a larger nucleus.
- Nuclear anomalies; hyperchromic stain, polymorphisms, hypertrophic.
- Atypical vascularization; anomalies in caliber and trajectory according to the degree of injury, capillary fragility, tortuosities, hypervascularization.
- The vascularization easily identifiable through microcolpohysteroscopy allowing to make a more precise diagnosis of early invasion (Figure 11)

MICROCOLPOHYSTEROSCOPY AND VIRUS INFECTION

**Coilocytosis:** In the superficial cells of the mature epithelium, the perinuclear halo, vacuolation and balonization of the cytoplasm is visualized.

**Nuclear alterations:** Binucleation or multinucleations, hyperchromatic, hypertrophic, clear and irregular nuclei, their comparison between themselves and especially with normal tissue facilitates the diagnosis.

**Superficial keratosis:** Areas that faintly stain with lugol, visualizing white-yellowish, anucleated squamous cells that weakly take on waterman blue dye, give a dirty appearance to the field.

**Spiral disposition:** It is characteristic of the first phase of papillary condyloma in which the superficial iodine-negative cells are arranged in a spiral shape, forming the base of future papillae (Figures 7).

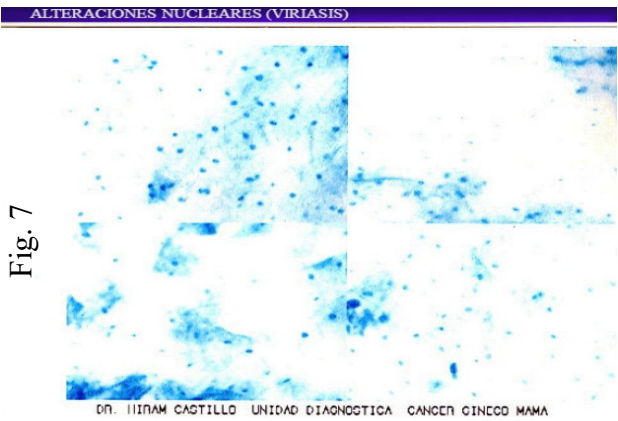


Fig. 7

Fig. 8

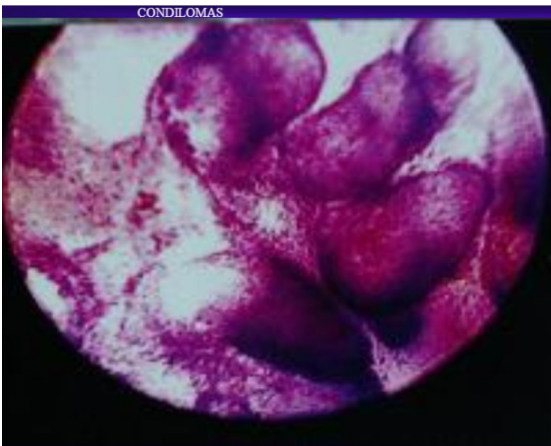
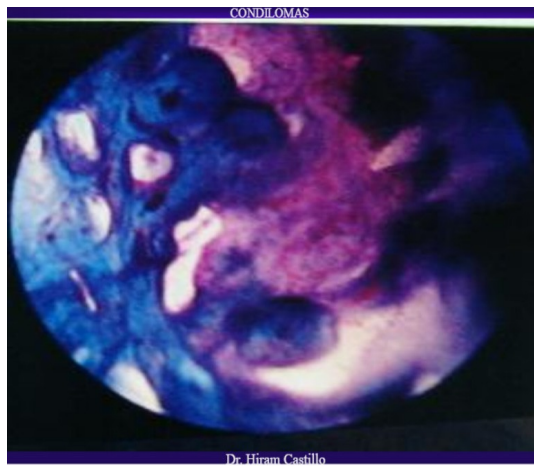


Fig. 9



CONDYLOMAS

**Papillary:** Formed with papillae covered by iodine-negative squamous cells, with few alterations (rarely associated with atypia), centered by a vascular loop characterized by a tortuous trajectory (Figure 8).

**Micropapillary:** Small pointed and cone shaped areas (spicules) that stain dark blue located in the surrounding epithelium, as they are coated with iodine-negative basal cells. Some spicules have a clear halo at the base because they do not take this stain, they are mobile, usually multiple, and occasionally show their central vascular axis (Figure 9).

ECTOPIA

It is when the columnar epithelium is located outside its normal location with a greater or lesser area of normal basal epithelium. The mucus load is significantly lower due to the exposure of the vaginal acid medium and the initial metaplastic phenomena, they are easily visualized when stained with waterman blue ink, identifying the papillary structures and terminal capillary vessels.

Hysteroscopy Newsletter  
is an opened forum to all  
professionals who want to  
contribute with their  
knowledge and even  
share their doubts with a  
word-wide gynecological  
community



FIND US ON

-  [hysteroscopy\\_newsletter](#)
-  [www.facebook.com/hysteronews](#)
-  [www.twitter.com/hysteronews](#)
-  [Hysteroscopy newsletter](#)
-  [HYSTEROscopy group](#)
-  [Hysteroscopy newsletter](#)
-  [www.medtube.net](#)



HYSTERO Scopy  
Newsletter

# HYSTERO Scopy Editorial team

## The “unstoppable” Hysteroscopy Newsletter NET

