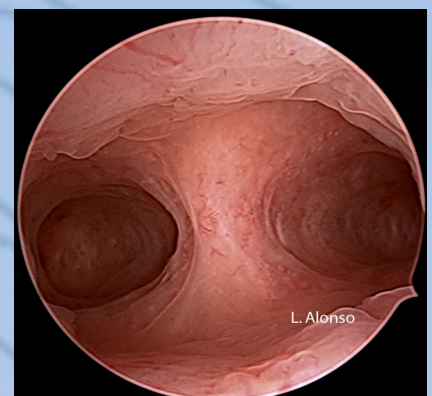


Hysteroscopy Newsletter

| | |
|--|----|
| <i>Editorial</i> | 2 |
| Attilio di Spiezio Sardo | |
| <i>Septate Uterus: a Review</i> | 3 |
| Luis Alonso Pacheco | |
| <i>Diagnosis of the Septate Uterus by Different Modalities</i> | 6 |
| Haresh Vagharia | |
| <i>Dilemma in the diagnosis of septate uterus: Overestimation vs Underestimation</i> | |
| Artur Ludwin | 9 |
| <i>Surgical Treatment of the Septate Uterus</i> | |
| Ursula Catena | 15 |
| <i>New Concepts in the Treatment of the Septate Uterus</i> | 20 |
| Stefano Bettocchi | |
| <i>Reproductive Impact of the Septate Uterus</i> | 22 |
| Maria Carrera | |
| <i>Cervical Septum's Dilemma</i> | 25 |
| Jose Carugno, Kiara Marquez | |
| <i>Robert's Uterus</i> | 28 |
| Laura Nieto | |



TEAM COODINATORS

L. Alonso
J. Carugno

EDITORIAL COMMITTEE

SPAIN

E. Cayuela
L. Nieto

ITALY

G. Gubbini
A. S. Laganà

USA

L. Bradley

MEXICO

J. Alanis-Fuentes

BRASIL

Thiago Guazzelli

ARGENTINA

A. M. Gonzalez

VENEZUELA

J. Jimenez

SCIENTIFIC
COMMITTEE

A. Tinelli (Ita)
O. Shawki (Egy)
A. Úbeda (Spa)
A. Arias (Ven)
A. Di Spiezio Sardo (Ita)
E. de la Blanca (Spa)
A. Favilli (Ita)
M. Bigozzi (Arg)
S. Haimovich (Spa)
E. Xia (Cn)
R. Lasmar (Bra)
A. Garcia (USA)
J. Dotto (Arg)
R. Manchanda (Ind)
M. Medvediev (Ukr)
M. Ellessawy (Ger)
X. Xiang (Cn)
G. Stamenov (Bul)
Peter Török (Hun)

*All rights reserved.
The responsibility of the signed contributions is
primarily of the authors and does not
necessarily reflect the views of the editorial or
scientific committees.*

HYSTEROSCOPY Editorial team

Dear hysteroscopy friends,

It is with great pleasure and pride that I present to you this new issue of the Hysteroscopy Newsletter, which increasingly compiles and disseminates thoughtful insights into the interesting world of hysteroscopy, which as all of you well know, is in constant evolution and change. The topic of this issue, totally focused on the septate uterus which is particularly dear to me; In recent years, enormous progress has been made which has made it possible to expand knowledge and improve the management of this class of Müllerian anomalies, which are still the subject of heated debate.

In this issue, the opinion and experience of leading experts on the subject made it possible to outline a precise, clear and rigorous picture on the correct methods of diagnosis and treatment of the septate uterus and its variants. In these pages you will find everything you need to know to diagnose this enigmatic pathology and to manage an apparently simple surgical technique, with clear objectives, but which hides pitfalls, that can at the same time be very frustrating, in terms of anatomical outcomes.

Luis Alonso opens the issue with an excellent review that offers an overview, enriched with high quality images, of the disease in question... His review is so comprehensive that you will wonder if it makes sense to keep reading the rest of the articles! But Haresh Vaghasia will change your mind, clarifying the role of diagnostic techniques and putting a firm point that leaves no room for further doubts. Ambiguities that are instead instilled from the point of view of Arthur Ludwin, who rekindles souls by stimulating a "critical" thinking. With regard to treatment, Ursula Catena focuses on the goal of simplicity and clarity with a summary on the state of the art of hysteroscopic metroplasty techniques, traditional and most innovative instrumentation, and on methods for an objective evaluation of the completeness of the intervention. Following, Professor Stefano Bettocchi provides an important added value to this issue, inviting to change the perspective and opening a new frontier in the surgical approach to the uterine septum. Then, Jose Carugno and Kiara Márquez face perhaps one of the most spinous issue, which is the treatment of the cervical septum, and I think that after reading it, you will obtain an evidence based view of this clinical challenge. Finally, Maria Carrera makes a brilliant summary on the evaluation of the reproductive impact of the uterine septa, which remains the point on which there is still a long way to go, as well as for the study of rare and less known forms, such as the Robert's uterus that is clearly illustrated by Laura Nieto Pascual.

In conclusion, in light of the availability and the potential of modern diagnostic methods and new surgical instrumentation, my advice is to standardize the diagnostic and operative techniques in your clinical practice, to set clear and rigorous objectives and above all, to have the perseverance needed to achieve them.

I wish you happy reading!

Attilio Di Spiezio Sardo
Napoli, Italia

*If you are interested in sharing your cases or have a hysteroscopy image that
you consider unique and want to share, send it to hysteronews@gmail.com*

Septate Uterus: A Review

Luis Alonso Pacheco

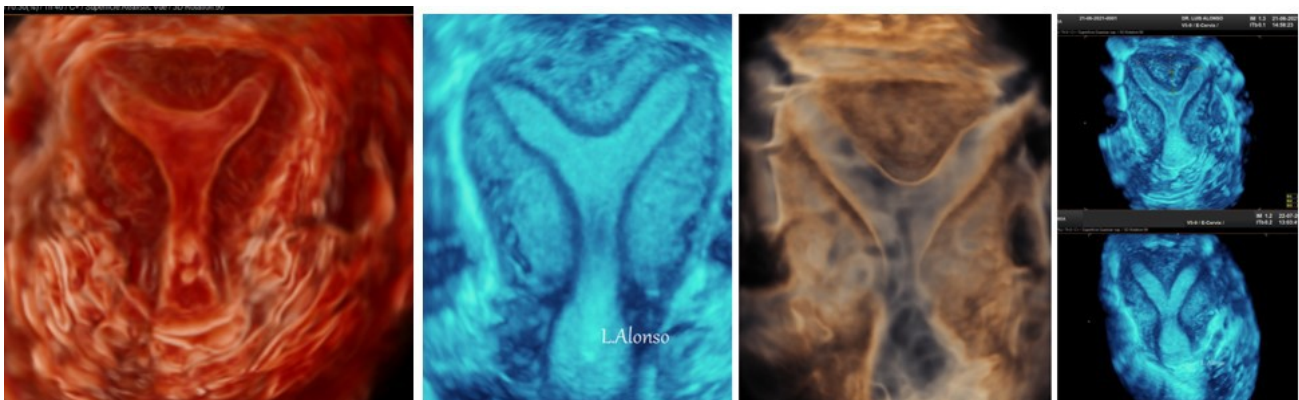
Centro Gutenberg. Málaga. Spain

Hysteroscopy Newsletter Vol 8 Issue 2

INTRODUCTION

Septate uteri continue to be a challenge for the hysteroscopist. This type of uterine malformation occurs as a result of failure in the reabsorption of the fusion area of the Müllerian ducts. Septate uterus is associated with poor reproductive outcomes, including high rates of miscarriage and preterm birth. Hysteroscopic metroplasty is considered the Gold Standard treatment of this condition, a procedure that is in most cases simple and safe to perform and reduces the rates of adverse obstetric outcomes related to the presence of the septum.

There are few studies on the histological structure of the uterine septum. March's phrase "the septum is a fibroelastic tissue" remains among gynecologists and there is a common belief that the septum is composed of tissue with little amount of muscular fibers and poorly vascularized. Sparac et al studied the histology of the septum and concluded that it is not composed of an avascular connective tissue, but of fibromuscular tissue with a predominance of connective tissue in 72.3% of the cases and predominantly muscle tissue in 27, 6% [3]. The vascularization of this structure has also been studied by power Doppler by Kupesic [4] who found vascularization in 71.22% of the patients, concluding that the majority of the septa are vascularized.



The incidence of uterine malformations in the general population remains unknown, this is due to the fact that a large portion of these women are asymptomatic, also, the absence of standardization in the diagnosis, affects the results of the different studies. Data from the Chang et al [1] on 94 observational studies that included a total of 89,861 women found a prevalence of uterine malformation of 5.5% in the general population, 8.0% in the infertile group, 13.3 % in those with a history of spontaneous abortions and 24.5% in women with history of spontaneous abortion and infertility. The most frequently reported malformation was arcuate uterus whereas septate uterus was the most frequent in the infertile patient.

CLASSIFICATION

The septate uterus has been classically divided into two types, complete and partial. The complete septate uterus is the one in which the septum reaches the internal cervical os (ICO) while the partial septum does not reach up to the cervix.

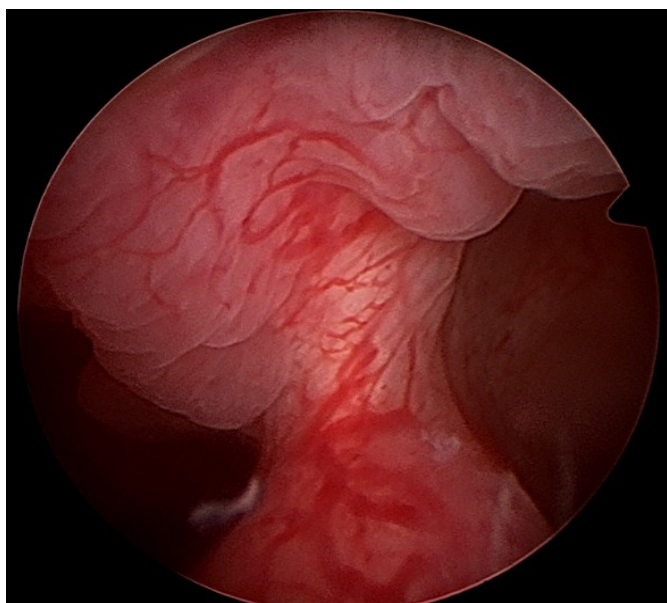
The classification of the AFS classified them as class V (Va the complete and Vb the partial) Recently the ESGE and the ESHRE have established a new classification system. In this system septate uteri are classified as class U2, (U2a the partial and U2b the complete)

CLINICAL COURSE

Rates of miscarriage associated with the presence of the septum of up to 60% have been published [4]. The mechanism by which the septum produces abortion is unclear and several theories have been proposed to explain this fact. The most accepted is in relation to a theoretical decrease in vascularization of the septum that can affect embryoimplantation. Other authors suggest that the cause of spontaneous abortions could be related to an uncoordinated contractility of the muscle fibers of the septum [5]

The correlation between septate uterus and preterm birth is controversial. Different studies estimate the rate of premature birth at 14.5%. There are several factors that could be related, such as the decrease in size of the uterine cavity, the increase of intrauterine pressure during pregnancy and the existence of an altered ratio of muscle fibers / connective fibers at the cervical level of women with uterine malformation. [6]

Regarding the relationship between the uterine septum and infertility, several studies suggest that women with uterine septum and infertility, in which there is no other factor, could benefit from hysteroscopic metroplasty. Pabuccu published a prospective observational study of reproductive outcomes after metroplasty in women with uterine septum and infertility and found pregnancy rates of 41% with live birth rates of 29.5%. [7]



DIAGNOSIS

An accurate diagnosis is essential to propose the right surgical treatment. In the case of the septate uterus, an accurate assessment of both external and internal uterine morphology is essential. The main points of the diagnosis of the septal uterus are to differentiate between septum and subseptum (complete septum vs partial septum) and to determine the presence of an indentation at the uterine fundus of the uterus.

Hysterosalpingography offers information about the morphology of the uterine cavity. In the case of the septate uterus, it shows two small symmetric endometrial cavities. Usually the separation angle of the two cavities is less than 75 ° in the case of the septate uterus, although this is not an adequate method to differentiate between the septate and bicornuate uterus

Ultrasound is an important diagnostic tool for the diagnosis of this pathology since it offers information on the morphology of the uterine cavity, on the external uterine contour and on the depth and vascularization of the septum. The 2D ultrasound is a suitable method for the diagnosis of uterine malformations, although its main limitation consists of the impossibility to obtain a coronal view of the uterus. It has been estimated that 2D ultrasound has a diagnostic accuracy in the case of uterine malformations of 80.65% [8]. Sonohysterography, when using liquid medium to distend the uterine cavity, improves the diagnosis with a sensitivity and specificity rate of 93% and 99% respectively. [9]

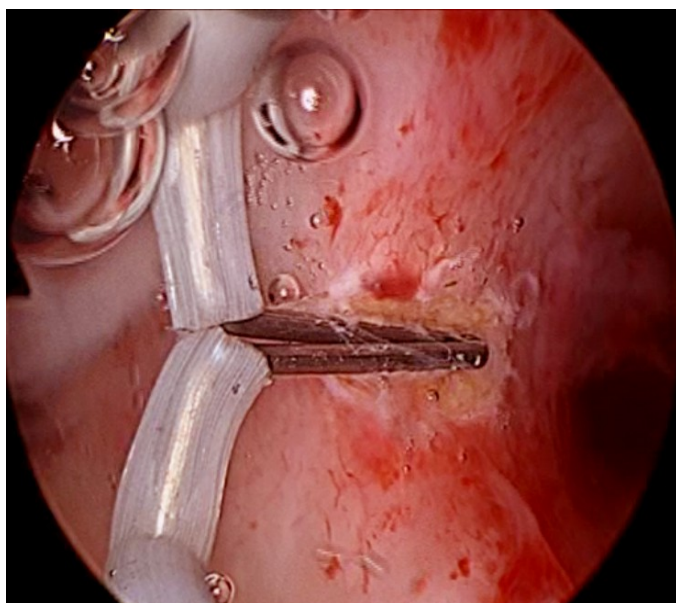
The 3D ultrasound offers an accurate reconstruction of the uterine morphology, both of the cavity and the external contour. The accuracy of 3D ultrasound in the diagnosis is 91.6% when evaluating the external contour and 100% in the study of the uterine cavity, having diagnostic results similar to those of MRI. [10]

MRI also offers precise information on the cavity and uterine contour. Classically it is awarded diagnostic accuracy of 100%, figures that are similar to those achieved with the association of hysteroscopy plus laparoscopy, which is classically considered the "gold standard" technique for the diagnosis of uterine malformations, although the latter combination, being invasive, is not recommended as a first-line diagnostic modality.

TREATMENT

The need for a surgical correction of the uterine septum is dictated by the obstetric history of the patient than by the presence of the septum, the main indication of surgical correction being poor obstetric history. There is still controversy as to when a septate uterus should be corrected, while some authors recommend surgical correction only in cases with poor reproductive outcomes, others recommend prophylactic hysteroscopic metroplasty given the poor obstetric results to which this malformation is associated.

The main indication is in patients with recurrent pregnancy loss since it has been observed that surgical correction improves reproductive outcomes in these patients. In patients with septate uterus with infertility, the value of metroplasty is still a matter of debate. A prospective study by Mollo et al reported that the chances of conceiving increased after correction of the septum and today it is accepted that hysteroscopic metroplasty increases pregnancy rates in women with primary infertility. [11]



In patients who are going to undergo assisted reproduction procedures, De Angelis demonstrated the beneficial effects of metroplasty before the reproduction treatment, concluding that a hysteroscopic metroplasty should be recommended to all patients with septate uterus before IVF to improve success rate.

Surgical treatment has evolved from the techniques of Tompkins or Jones through the abdominal route to the current hysteroscopic approach. It was in 1974 when Edstrom first described the resection of a uterine septum guided by endoscopy [12]. This was the starting point for what is the current metroplasty.

Hysteroscopic metroplasty consists of a transverse incision of the uterine septum and a real resection of the septum. This incision should be made just in the middle of it, equidistant from the anterior and posterior uterine walls. The tubal ostia are of great help to maintain the correct plane and orientation and to avoid healthy myometrium injury.

We conclude that resection of the uterine septum significantly decreases the rates of pregnancy loss and preterm birth, as well as improving fertility in those women with septate uterus and infertility of unknown origin. Hysteroscopic metroplasty is an effective and safe treatment with low complication rates when performed by expert after an accurate diagnosis.

REFERENCES

- 1- Chan YY, Jayaprakasan K, Zamora J, Thornton JG, Raine- Fenning N, Coomarasamy A. The prevalence of congenital uterine anomalies in unselected and high-risk populations: a systematic review. *Hum Reprod Update*. 2011;17(6):761-71.
- 2- Saravelos SH, Cocksedge KA, Li TC. Prevalence and diagnosis of congenital uterine anomalies in women with reproductive failure: a critical appraisal. *Hum Reprod Update*. 2008;14(5):415-29.
- 3- Sparac V, Kupesic S, Ilijas M, Zodan T, Kurjak A. Histologic architecture and vascularization of hysteroscopically excised intrauterine septa. *J Am Assoc Gynecol Laparosc*. 2001;8(1):111-6.
- 4- Reichman DE, Laufer MR. Congenital uterine anomalies affecting reproduction. *Best Pract Res Clin Obstet Gynaecol*. 2010;24(2):193-208.
- 5- Dabirashrafi H, Bahadori M, Mohammad K, Alavi M, Moghadami- Tabrizi N, Zandinejad K, et al. Septate uterus: new idea on the histologic features of the septum in this abnormal uterus. *Am J Obstet Gynecol*. 1995;172(1 Pt 1):105-7.
- 6- Reichman DE, Laufer MR. Congenital uterine anomalies affecting reproduction. *Best Pract Res Clin Obstet Gynaecol*. 2010;24(2):193-208.
- 7- Pabuccu R, Gornel V. Reproductive outcome after hysteroscopic metroplasty in women with septate uterus and otherwise unexplained infertility. *Fertil Steril*. 2004;81(6):1675-8.
- 8- Yu LL, Zhang X, Zhang T, Chen HR, Wang ZH. Detection of congenital uterine malformation by using transvaginal three-dimensional ultrasound. *Journal of Huazhong University of Science and Technology Medical sciences*. 2014;34(5):782-4.
- 9- Saravelos SH, Cocksedge KA, Li TC. Prevalence and diagnosis of congenital uterine anomalies in women with reproductive failure: a critical appraisal. *Hum Reprod Update*. 2008;14(5):415-29.
- 10- Bernejo C, Martinez Ten P, Cantarero R, Diaz D, Perez Pedregosa J, Barron E, et al. Three-dimensional ultrasound in the diagnosis of Müllerian duct anomalies and concordance with magnetic resonance imaging. *Ultrasound Obstet Gynecol*. 2010;35(5):593-601.
- 11- Mollo A, De Franciscis P, Colacurci N, Cobellis L, Perino A, Venezia R, et al. Hysteroscopic resection of the septum improves the pregnancy rate of women with unexplained infertility: a prospective controlled trial. *Fertil Steril*. 2009;91(6):2628-31.
- 12- Edstrom K. Intrauterine surgical procedures during hysteroscopy. *Endoscopy*. 1974;6:175-81.

Diagnosis of the Septate Uterus by Different Modalities

Haresh Vaghasia

Apollo Spectra Hospital, Mumbai, India

Hysteroscopy Newsletter Vol 8 Issue 2

INTRODUCTION

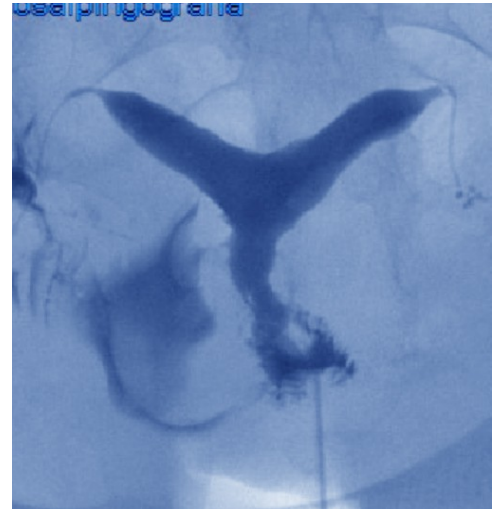Diagnosis of Septate uterus is of fundamental importance and forms the base of its management. Historically, assessment of the external and internal uterine contour at laparoscopy and hysteroscopy were considered the gold standard method for diagnosing Mullerian anomalies. The advancement of radiological methods over the past two decades made the diagnosis of a septate uterus more standardised, eliminating the need of surgical intervention for diagnosis.

From raising a mere suspicion to accurate diagnosis of septum various modalities like X-ray hystero-salpingography, 2D ultrasound, power doppler, hysterosalpingo-contrast-sonography, 3D ultrasound, MRI, hysteroscopy and laparoscopy are available which are discussed below.

METHODS

X-ray Hysterosalpingography (HSG) is commonly performed in infertility cases to test the uterine cavity and tubes. It is an invasive, painful examination with limitations like inability to evaluate the external contour, cannot differentiate the septate and the bicornuate uteri. It may mislead in diagnosing a septate uterus as an unicornuate uterus, when the cannula is pushed deep past the septum delineating only one horn. High false-positive findings makes HSG a non-reliable. However, a well taken film can strongly indicate the abnormality.

Two-dimensional ultrasonography (2D USG) is a preliminary diagnostic tool which is easily accessible, non-invasive, and cost-effective. This tool is however fruitful only in qualified hands and when performed during the mid-cycle. Scanning the uterus in various planes helps ascertain the diagnosis of septate uterus. Presence of two closely placed endometrial cavities in the transverse plane must be traced from fundus down to estimate partial or complete septum.



Power Doppler provides a new and noninvasive tool for differentiation of septate from bicornuate uterus. On doppler irregular vascular networks are detected between the two hemi-cavities of septate uterus. However, bicornuate uteri shows a peculiar vascular network forming the Greek letter 'γ' between the two hemi-cavities at the level of the uterine midline. Detection of the γ sign can be used to differentiate septate from bicornuate uterus.

Three-dimensional ultrasonography (3D USG) has good reproducibility, high level of intra observer agreement, provides additional and more reliable images and allows for the evaluation of the cervix and the vagina simultaneously; however, it is less available and requires more specialized training than the 2D USG. A 3D USG combined with saline infusion can be accurate compared to stand alone 3D USG and invasive procedures of laparoscopy & hysteroscopy.

In 3D USG examinations, the diagnosis of uterine septum, requires multiplanar and rendering modes of the uterus in sagittal, transverse and true coronal planes. Surface rendering reconstruction in coronal plane of the uterus demonstrates uterine fundal contour. (Details of which are discussed in the next section)

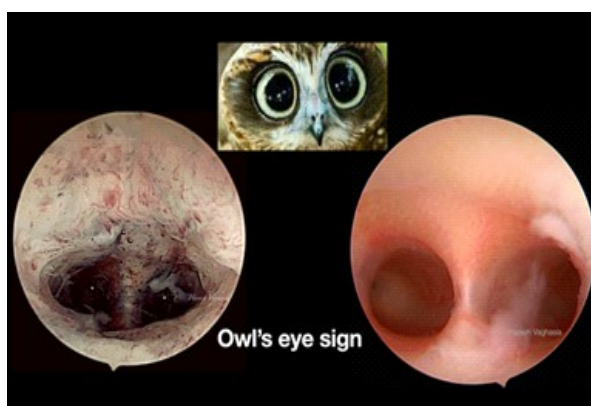Saline Infused Sonography (SIS) or Sono-Hysterography is a less invasive and more informative method than x-ray. This procedure demands skilled hands. One must be aware to avoid over-distention of cavity as it can modify its internal contours, masking the septum, resulting in a false negative result. Sono-hysterography is superior to conventional hysterosalpingography in differentiation of septate from bicornuate uterus; eliminating the need of laparoscopy.

MRI is considered the gold standard for the diagnosis of complex Mullerian anomalies. MRI offers objective and reliable information about overall anomalous anatomy. MRI is 70% accurate for the diagnosis of uterine septum, producing comparable result to 3D USG. There is limited data comparing the diagnostic accuracy of MRI versus laparoscopy/hysteroscopy. It is more expensive and less available than the ultrasound and needs a qualified professional to interpret the results. The technique also falters due to multiple acquisitions leading to long scanning duration and patient non compliance.

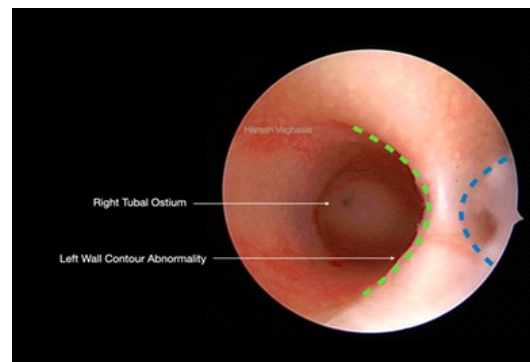
Hysteroscopy is minimally invasive and provides reliable information about the vagina, cervical canal and uterine cavity, although it does not evaluate the thickness of the uterine wall or the external contours. Hence, does not differentiate the septate uterus from the bicornuate one. There are no specific criteria for diagnosis of a septate uterus using hysteroscopy, which makes inefficient tool decide on treatment.

There are tell-tale signs which may be useful in diagnosing a septate uterus on hysteroscopy, which are described below :

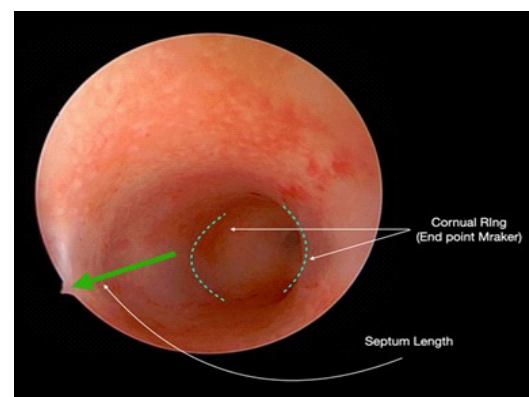
- Sub-septum is generally easy to diagnose with a panoramic view of the cavity as shown in the illustrations below.



- A panoramic view from the Internal cervical opening (ICO) in a complete septum is characteristic - where the septum occupies more or equal space of the view than the cavities seen as two owl eyes and hence can be called "Owl Eye Sign". (Illustration A)
- In most of the cases of septate uterus while withdrawing hysteroscope from the ostia will show a contour deformity on the contra-lateral side of the ostia which is in view (e.g. while coming out from left ostia the right wall would appear close the scope and straight due to septum blocking the mirror image counterpart. (Illustration B)



- It is vital for a hysteroscopic surgeon to define the upper end of the septum. In both partial as well as complete septum the upper end lies between an imaginary line from the right to left cornual ring. (Illustration C) This knowledge of anatomy helps in deciding completion of septotomy or resection of septum.



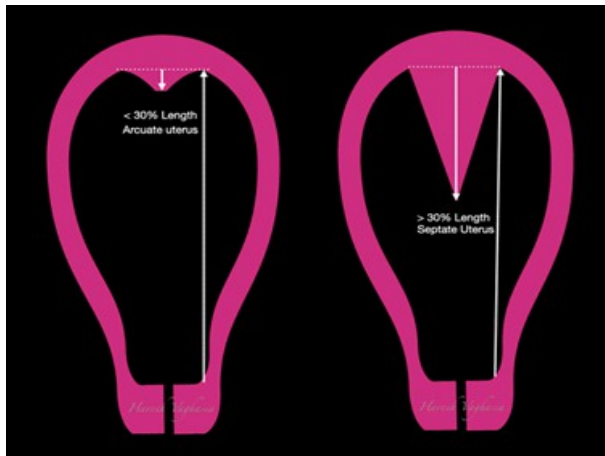
- The negotiation of hysteroscope from ICO to the cavities can be more demanding in bicornuate uteri as compared to septate uterus; which is acutely divergent caused by failure of unification of the body.

Three diagnostic criteria at hysteroscopy have been documented as shown in figures below

1- The extent of the intracavitary protrusion:

Fundal protrusion $< 30\%$ indicates an arcuate uterus


Fundal protrusion $\geq 30\%$ indicates a septate uterus



2- The angle at the central point of the fundal protrusion:

An obtuse angle ($>90^\circ$) indicates an arcuate uterus

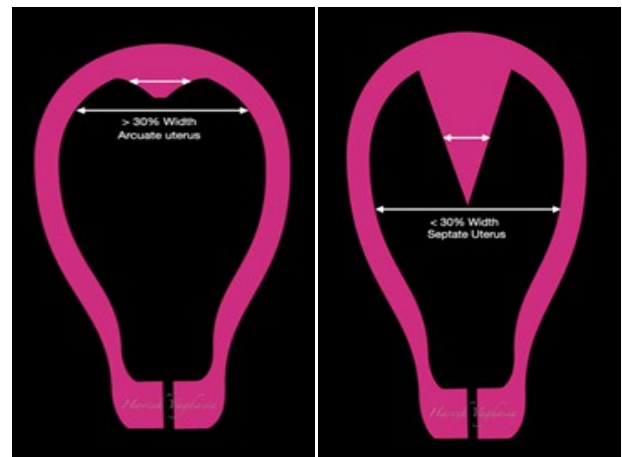
An acute angle ($\leq 90^\circ$) indicates a septate uterus



3- The width of the bulging structure at the tip end compared with the distance between both tubal ostia (inter-ostial distance - ISD) .

Width $\geq 30\%$ of ISD suggests an arcuate uterus

Width $< 30\%$ of ISD suggests a septate uterus



It is important when confirming the diagnosis of septate uterus that the external uterine contour as well as the internal configuration of the endometrial cavity are assessed. HSG or hysteroscopy alone is inadequate, but details of the septum may be delineated using a good hysteroscopic evaluation before planning or commencing a septotomy or septum resection.

Laparoscopy evaluates the external contour of the uterus and the peritoneal structures, but it is an invasive exam, does not evaluate the thickness of the uterine wall and completely depends on the experience and subjective evaluation of the examiner.

SUMMARY

There is fair evidence that 3-D USG, SIS, and MRI are good diagnostic tools for distinguishing a septate and bicornuate uterus when compared with laparoscopy/hysteroscopy.

It is recommended that imaging with hysteroscopy, should be used to diagnose uterine septa rather than laparoscopy with hysteroscopy, because this approach is less invasive.

MRI and SIS has no additional advantage over 3D USG. On the contrary MRI is expensive, less compliant and time consuming. SIS & hysteroscopy are invasive investigations which needs to be performed during proliferative phase or after endometrial preparation.

3D USG is the gold standard and non-invasive diagnostic tool for diagnosis of uterine septum.

Dilemma in the diagnosis of septate uterus: Overestimation vs Underestimation

Artur Ludwin

Department of Gynecology and Oncology, Jagiellonian University, Ludwin & Ludwin Gynecology, Private Medical Center, Krakow, Poland

INTRODUCTION

Probably, all expert hysteroscopic surgeons recognized a problem, that some part of fertility centers and hysteroscopists offer hysteroscopic septum resection to women with a normal uterus and minute internal fundal indentations. They treat of fundal myometrium starting from the internal fundal indentation of 3 mm and commonly less than 10 mm and report such 'cosmetology' procedures as a uterine septum or 'subseptum' resection.

On the other hand, we meet women with recurrent miscarriages and uterine septum occupying most of the uterine cavity, who undergo subsequent miscarriage, but they are not referred for surgery, because the uterus does not meet some of the currently used criteria and definitions of septate uterus.

Indeed, a highly polarized debate among hysteroscopic surgeons is on where is the landmark separating reproductive hysteroscopic surgery of a true septate uterus and cosmetology of normal conditions (1).

At the opposite pole, there are opinions of practitioners of evidence-based medicine, that hysteroscopic metroplasty for women with septate uterus should not be offered in daily practice at all. They found in the first and long-awaited multicenter randomized controlled trial on septum resection no reproductive benefits from the treatment of a condition treated under the name of septate uterus (2). A problem is in this study that 'true' metroplasties of septate uterus were mixed with cosmetology following the definition used, which included normal and arcuate uterus according to the two out of three current classifications (1).

The problem with these disagreements in definition and over/under-diagnosis is not entirely novel, but it has been increasing since the European Society of Human Reproduction and Embryology/European Society for Gynaecological Endoscopy (ESHRE/ESGE) in 2013, and the American Society of Reproductive Medicine (ASRM) in 2016 published two different arbitrary definitions of the septate uterus, respectively (3, 4).

To resolve the problem of these classifications with totally arbitrary criteria for diagnosis, the first non-arbitrary classification and definitions for most common uterine conditions according to the Congenital Uterine Malformations by Experts (CUME) group has been developed (5).

Here, the opinion about overdiagnosis and underdiagnosis of septate uterus and its impact on research interpretation and surgical practice is presented.

Before current classifications: septate uterus by subjective diagnosis

Traditionally, a septate uterus vel uterine septum was defined as a congenital uterine malformation, when a single uterine body with a normal external outline is internally divided into two parts. This archetypic name meant a major uterine anomaly with a significant division of the uterine cavity. It was recognized that such defined malformation is associated with poor reproductive outcomes, especially recurrent miscarriages, pre-term birth, maybe infertility, and worse results of ART. Contrary, uteri with minor internal fundal indentation were considered to be benign morphologic conditions without significant clinical implications and classified as an arcuate uterus.

The most popular classification of Mullerian anomalies according to the American Fertility Society (AFS) reflected such distinction and offered a scheme of uterine coronal views, yet without any measurable definition and criteria for septate uterus and other anomalies (6).

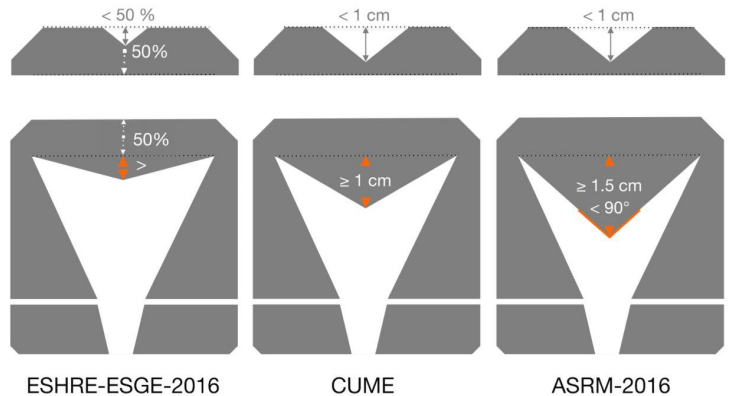
Using this former classification, a prevalence of septate uterus in general population of patients, who underwent optimal diagnostic tests is 2.3%, and non-significantly different in infertile women miscarriage equal to 3%. Interestingly, the prevalence of arcuate uterus was lower in those with infertility (1.8%) and miscarriages (2.9%) in comparison to general population (3.9%) (7). Yet, these estimations are not related to any measurable criteria by the current classifications, and quantified appearance of septate and arcuate uterus.

Current classifications: Septate uterus by ESHRE/ESGE, ASRM and CUME criteria

Currently, there are three main classifications of septate uterus with measurable criteria, and suggested cut-offs: ESHRE/ESGE (2013, 2016), ASRM (2016, 2021) and CUME (2018) for internal indentation (8-13). The classifications define different measurable criteria and cut-offs for assessment internal and external fundal indentation (Table 1). The ESHRE-ESGE uses internal indentation depth/wall thickness ratio $> 50\%$ for diagnosis of septum, and this criterion has been never used and tested before its arbitrary establishing. It means that the most common septate uteri by ESHRE/ESGE have the internal indentation depth close to 0.5 cm considering that median of 50% of wall in reproductive age, which is less than 0.5 cm.

The ASRM recommends measuring of internal indentation of angle and depth with cut-off $< 90^\circ$ and ≥ 1.5 cm for septum, respectively, following the connection of two previous definitions by Salim et al. (13) and Ludwin et al. (14), respectively. Yet, The CUME recommends, the internal indentation depth ≥ 1 cm as septate since this measurement is simple and reliable and this criterion is in agreement with diagnosis made most often by multiple representative experts. Also, the CUME found that internal indentation angle $\geq 140^\circ$, and indentation/wall $\geq 110\%$ are in agreement with multi-rater reference (the independent diagnosis made most often by experts), but these measurements are less

reliable. Recently, ASRM/MAC2021 corrected its definition by copying a criterion of 1 cm of internal indentation, yet the angle remains $\geq 90^\circ$ (8).



Criteria for diagnosis of septate uterus by ESHRE/ESGE, CUME and ASRM-2018. CUME has the alternative cut off for internal indentation angle ($< 140^\circ$) and indentation/wall ratio (110%) are less reliable. Image adopted from Ludwin et al., 2019

All these criteria can be measured in imaging methods, which are able to depict the coronal view of the uterus: 3D ultrasound, 3D sonohysterography and MRI. Other methods have several limitations in performing these measurements. For instance, laparoscopy with hysteroscopy is not able to measure uterine wall thickness and cannot be used alone as a diagnostic tool with ESHRE/ESGE definitions (16). Also, hysteroscopy has no instruments for exact measures of the angle, and subjective diagnosis by hysteroscopic view is with very poor agreement between international experts (17).

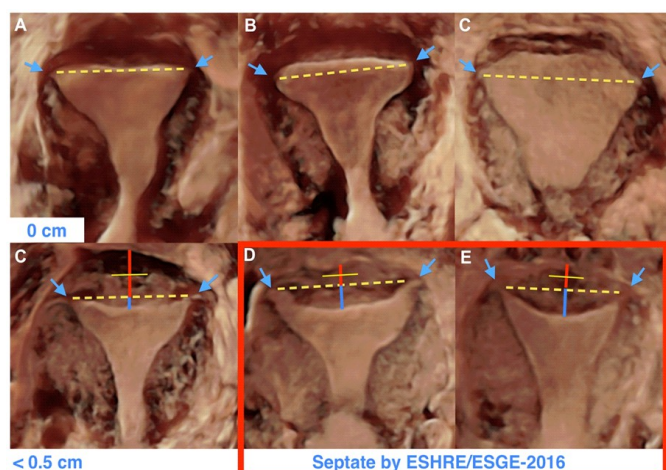
Impact of ESHRE/ESGE, ASRM, and CUME on the septum frequency diagnosis

There are no studies with the estimation of the prevalence of septate uterus in the truly unselected general public. But it was easy to recognize in consecutive women from daily practice in a medical center focused on the management of congenital uterine malformations that the prevalence of septate uterus can be varied from 2.7% if the septate uterus fulfilled all three definitions to 32.6% if the diagnosis was made according to at least one of the three definitions (12). The ESHRE/ESGE-2016 criteria significantly increased the frequency of septate uterus recognition in comparison to ASRM-2016 and CUME. The relative risk of overdiagnosis of

Table 1. Current classifications and their criteria, scientific grounds of establishing, and overdiagnosis, underdiagnosis

| Classification | Definition and criteria | Manner of definition and criteria development | Implications for frequency of diagnosis |
|-----------------|--|---|---|
| ESHRE/ESGE 2014 | Internal fundal/uterine indentation depth > 50% of myometrial thickness and external indentation depth < 50% of myometrial thickness, with myometrial thickness measured as average of anterior and posterior thicknesses, assessed in sagittal plane | Arbitrary choice without scientific grounds, and criteria testing | Overdiagnosis: good proportion of septate uteri have indentation < 10 mm, and meet criteria of normal/arcuate uterus by two other classifications |
| ESHRE/ESGE 2016 | Internal fundal/uterine indentation depth > 50% of uterine-wall thickness and external indentation depth < 50% of uterine-wall thickness, with uterine-wall thickness measured above <u>interostial/intercornual line</u> | Arbitrary choice without scientific grounds, and criteria testing | Extreme overdiagnosis, most septate uteri have the internal indentation close to 5mm, very poor agreement with diagnosis made most often by representative experts (clinicians, surgeons, sonologists) |
| ASRM 2016 | Internal fundal indentation depth ≥ 1.5 cm and angle of internal indentation < 90° and external fundal indentation depth < 1 cm | Arbitrary choice from two arbitrary modifications of AFS classification by Salim et al. and Ludwin et al., respectively | Underdiagnosis and good proportion of uteri without diagnosis (wide angle and > 1.5 cm, acute angle and < 1.5 cm = no diagnosis), poor agreement with diagnosis made most often by representative experts (clinicians, surgeons, sonologists) |
| ASRM/MAC2021 | Internal fundal indentation depth > 1.0 cm and angle of internal indentation < 90° and external fundal indentation depth < 1 cm | Arbitrary choice without adequate reference, and justification of changes relative to ASRM 2016 and that the criterion of depth is similar to CUME | Possible underdiagnosis by criterion of angle of internal indentation < 90°, and good proportion without diagnosis (wide angle and > 1.0 cm; and acute angle and < 1cm = no definition) |
| CUME | Internal fundal indentation depth ≥ 1 cm and external fundal indentation depth < 1 cm* Alternative criteria for internal indentation by CUME: angle of internal indentation < 140° or Internal fundal/uterine indentation depth > 50% of uterine-wall thickness | Result of reliability and diagnostic accuracy study with top experts as a reference, Among three criteria for internal indentation: the depth has better inter-rater reliability than angle and depth/wall ratio | Reasonable multi-rater reference, the criteria reflect the diagnosis made most often by experts. |

*The criterion for external cleft < 1cm were used temporary in studies assessing frequency of diagnosis, yet the original CUME definition of septate uterus was developed for uterus with no external fundal indentation.



Originally diagnosed normal uteri in 2014 by ESHRE/ESGE-2014 and modified AFS classification by Ludwin et al. (3). A good proportion of them has become a septate uterus by ESHRE/ESGE-2016, but with small internal indentation, which meets criteria of normal uterus by ASRM-2016, ASRM/MAC 2021, and CUME. Image adopted from Ludwin and Ludwin 2015 (3), and Ludwin et al. 2019 (12). A good example on how development of new definitions has a tendency to create overdiagnosis.

septate uterus by ESHRE/ESGE-2016 vs ASRM-2016 and CUME was 6.6 and 2.6, respectively. But ASRM significantly decreased the frequency of septate uterus recognition in comparison to CUME with the relative risk of underdiagnosis equal to 0.4.

To understand the issue of over and underdiagnosis, one can consider that using these classifications in a single medical center for three months, 80 septate uteri by ESHRE/ESGE were diagnosed instead of 31 and 12 by CUME, and ASRM-2016, respectively among 261 participants (12).

In the CUME study, which included 100 consecutive women with any internal fundal indentation, 80%, 5%, and 18% had septate uterus by ESHRE/ESGE, ASRM, and CUME, respectively. Indeed, the suggested cut-off by ESHRE-ESGE greatly overestimates the prevalence of septate uterus, while the definition by ASRM underestimates the prevalence of septate uteri, leaving most of them in the gray zone, which does not meet the criteria of both normal/arcuate and septate uterus (5).

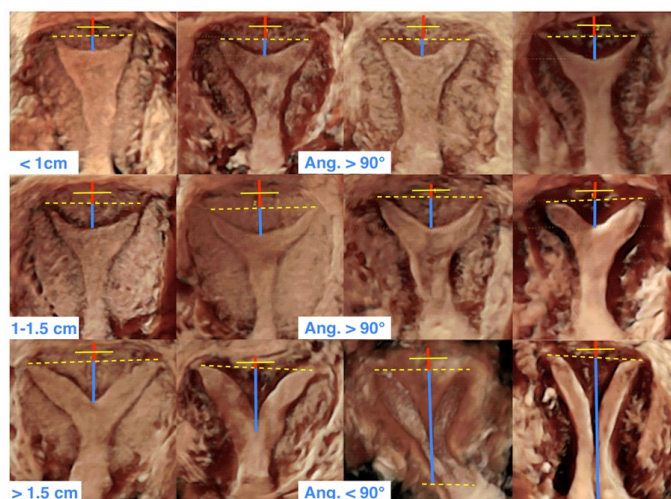
Moreover, another study in women with internal indentation of obtuse angle (arcuate uterus by modification of AFS by Salim et al.) showed that there were no significant differences in the past reproductive outcomes between women diagnosed with normal and septate uterus by

ESHRE/ESGE. It may implicate that surgical metroplasty guided by ESHRE/ESGE definitions in cases, should have no reproductive benefits.

Also, results studies and opinions agreed, that the ESHRE-ESGE system is promoting 'septal resection' for what appears to be a benign condition – normal/arcuate uterus (12, 15, 16). Interestingly, among 15 experts from 9 societies in the CUME study, there was not even one, including those from ESHRE/ESGE. Moreover, also expert surgeons from ESGE, and AAGL highly disagreed with the diagnosis by ESHRE criteria (5). The agreement between experts and the ESHRE/ESGE criteria was very poor (Kappa 0.1). But, also the agreement between experts and ASRM was poor, due to underdiagnosis by ASRM and leaving most of the cases classified by experts as the septate uterus in the gray zone.

Impact of overdiagnosis on practice and research

When overdiagnosis is used as a base of qualification for surgery, initially the profits for sellers of overtreatment are increasing, but it is

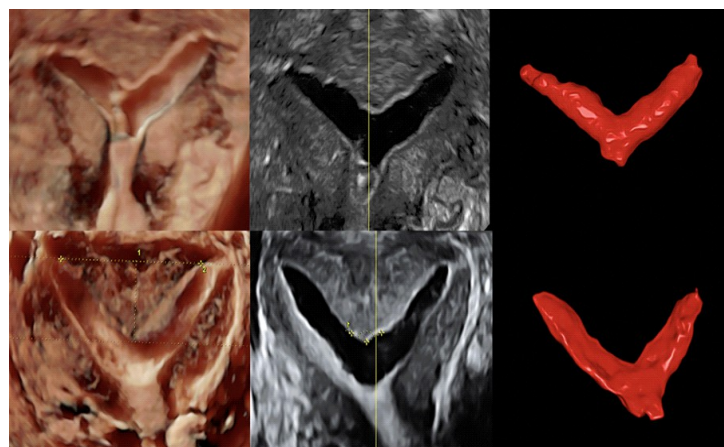


Originally diagnosed cases as septate uterus by ESHRE/ESGE-2014 criteria, yet normal (top row) and arcuate uterus (middle row) by modified AFS classification by Ludwin et al. (3). All uteri meet the criteria of septate uterus by ESHRE/ESGE-2016 (internal indentation depth/wall above interostial/intercornual line > 50%). Using ASRM-2016 definition (1.5cm of internal indentation depth with acute angle for diagnosis of septum) septate uteri are in the bottom row, yet the uteri in middle row are without diagnosis by ASRM-2016 and ASRM/MAC2021. According to CUME, the uteri in the middle and bottom row meet the criteria of septate uterus. The uteri in the top row are normal/arcuate by CUME and ASRM-2016 and ASRM/MAC2021. These examples indicate that ESHRE/ESGE, and ASRM overestimate and underestimate the diagnosis of septate uterus in comparison to CUME classification. Image adopted from Ludwin and Ludwin 2015 (3), and Ludwin et al. 2019 (12)

costly for patients and society. It was guesstimated that the global costs associated with the ESHRE/ESGE definition of septum would potentially be an extra US\$ 100–200 billion per 5 years in comparison to ASRM and CUME if preventive hysteroscopic metroplasty would be performed before pregnancy in young women aged 15–24 years (12).

However, selling overdiagnosis and overtreatment would be profitable for fertility centers and hysteroscopic surgeons only in short term. The official endorsement of overdiagnosis by serious societies like ESHRE/ESGE in its classification systems is harmful to the continuation of potentially truly necessary procedures because overdiagnosis is/will be used in RCTs as an inclusion criterion and to assess the effect of the intervention on the overdiagnosis.

The best example is this situation is the TRUST study on septum resection (2). In the published final protocol of the study, it is described that following 'the most recent ESHRE/ESGE classification, the septate uterus was defined as with an internal indentation at the fundal midline exceeding 50% of the uterine wall thickness regardless of the size of the septum. Actually, during open peer review by studying five versions of the protocol, it was found that the criteria for recognition of septate uterus used in the first stage of the study (the first 5 years) were significantly different from those used after 2014, as well as, after 2016. It may be the most important problem for the validity of this study because in the first period women with internal indentation depth equal to $\frac{1}{4}$ of the uterine cavity, in the second-period women with mere suspicion of the septate uterus by the ESHRE-ESGE criteria, and in the final phase of the study women with no limits to internal indentation measurements were included. Considering that the mentioned definition was following the ESHRE/ESGE, it is a high risk that a considerable part of women has a normal/arcuate uterus according to CUME and ASRM (2). The final study report does not disclose that the study is affected by overdiagnosis according to ESHRE/ESGE definition and in any stage of the reporting, the question about the number of women diagnosed by CUME and ASRM-2016 was not answered.



Two uteri, which do not meet the criteria of the normal/arcuate and septate uterus by ASRM-2016 and ASRM/MAC2021, and have no diagnosis by the ASRM classification due to obtuse angle of internal indentations (angle of internal indentation equal to 125° and 100° in the top and bottom row, respectively). In the top row the uterus has internal indentation depth > 1 cm, in the bottom row > 1.5 cm. These uteri meet the criteria of the septate uterus by ESHRE/ESGE-2016 and CUME. These are examples of underestimation of the septate uterus by ASRM/MAC2021 and ASRM-2016. Images were obtained using 3D sonohysterography with different render modes: HDlive and VCI, and automatic volume calculation software (SonoAVC).

For assessing the validity of the definition used in the TRUST study, one should consider the CUME study, which showed that among 20 septate uteri by ESHRE/ESGE, only 5 uteri and 1 uterus meet the CUME and ASRM criteria of the septum, respectively (5).

If the proportion of septate uterus by ESHRE/ESGE, ASRM, and CUME in the TRUST trial is only partially similar, it may mean that the study results mostly reflect 'hysteroscopic cosmetology' or an unreliable definition of septate uterus. In this context, the TRUST trial seems to be valid. When doctors use overdiagnosis of septate uterus by ESHRE/ESGE, and other unreliable definitions of septate uterus without measurable criteria and treat normal/arcuate uterus under the name of the septate uterus, the benefits of metroplasty are difficult to find (12, 15–17). Why? Because reproductive outcomes including ART results in women with internal indentation < 1 cm and obtuse angle are the same as in those without internal fundal indentation (12, 15–17).

CONCLUSIONS

The prevalence of septate uterus according to the ESHRE/ESGE, ASRM and CUME definitions differs significantly. An important limitation of the ASRM is the high proportion of grey zone (uteri without diagnosis), and the fact that criterion of acute angle underestimates the diagnosis of septate uterus in comparison to the diagnosis made most often by representative experts. The ESHRE/ESGE criteria mostly label healthy women with normal/arcuate uterus and common form of internal indentation as with septate uterus.

The CUME offers cut-off for all currently used measurements to make diagnosis accurate, reproducible and in agreement with multiple expert opinion (5). It is rationale to validate all diagnoses in practice, research and reporting of results of surgical procedures by disclosing absolute measurements of internal indentation/septum and using CUME as reasonable reference of septate uterus to prevent under- and overdiagnosis.

REFERENCES

- 1-Ludwin A. Septum resection does not improve reproductive outcomes: truly? *Human Reprod* 2020; 35: 1495–1498
- 2-Rikken JFW, Kowalik CR, Emanuel MH, Bongers MY, Spinder T, Jansen FW, Mulders A, Padmehr R, Clark TJ, van Vliet HA, Stephenson MD, van der Veen F, Mol BWJ, van Wely M, Goddijn M. Septum resection versus expectant management in women with a septate uterus: an international multicentre open-label randomized controlled trial. *Hum Reprod* 2021; 36: 1260–1267.
- 3-Ludwin A, Ludwin I. Comparison of the ESHRE-ESGE and ASRM classifications of Mullerian duct anomalies in everyday practice. *Hum Reprod* 2015; 30: 569–580.
- 4-The American Fertility Society classifications of adnexal adhesions, distal tubal occlusion, tubal occlusion secondary to tubal ligation, tubal pregnancies, mullerian anomalies and intrauterine adhesions. *Fertil Steril* 1988; 49: 944–955.
- 5-Ludwin A, Coelho Neto MA, Ludwin I, Nastri CO, Costa W, Acien M, Alcazar JL, Benacerraf B, Condous G, DeCherney A, De Wilde RL, Diamond MP, Emanuel MH, Guerriero S, Hurd W, Levine D, Lindheim S, Pellicer A, Petraglia F, Saridogan E, Martins WP. Congenital Uterine Malformation by Experts (CUME): diagnostic criteria for T-shaped uterus. *Ultrasound Obstet Gynecol* 2020; 55: 815–829.
- 6-The American Fertility Society classifications of adnexal adhesions, distal tubal occlusion, tubal occlusion secondary to tubal ligation, tubal pregnancies, mullerian anomalies and intrauterine adhesions. *Fertil Steril* 1988; 49: 944–955
- 7-Chan YY, Jayaprakasan K, Zamora J, Thornton JG, Raine-Fenning N, Coomarasamy A. The prevalence of congenital uterine anomalies in unselected and high-risk populations: a systematic review. *Hum Reprod Update*. 2011;17:761-71.
- 8-Pfeifer SM, Attaran M, Goldstein J, Lindheim SR, Petrozza JC, Rackow BW, Siegelman E, Troiano R, Winter T, Zuckerman A, Ramaiah SD. ASRM mullerian anomalies classification 2021. *Fertil Steril* 2021; 116: 1238–1252.
- 9-Grimbizis GF, Gordts S, Di Spiezio Sardo A, Brucker S, De Angelis C, Gergolet M, Li TC, Tanos V, Brolmann H, Gianaroli L, Campo R. The ESHRE/ESGE consensus on the classification of female genital tract congenital anomalies. *Hum Reprod* 2013; 28: 2032–2044.
- 10-Grimbizis GF, Di Spiezio Sardo A, Saravelos SH, Gordts S, Exacoustos C, Van Schoubroeck D, Bermejo C, Amso NN, Nargund G, Timmerman D, Athanasiadis A, Brucker S, De Angelis C, Gergolet M, Li TC, Tanos V, Tarlatzis B, Farquharson R, Gianaroli L, Campo R. The Thessaloniki ESHRE/ESGE consensus on diagnosis of female genital anomalies. *Hum Reprod* 2016; 31: 2–7.
- 11-Practice Committee of the American Society for Reproductive M. Uterine septum: a guideline. *Fertil Steril* 2016; 106: 530–540.
- 12-Ludwin A, Ludwin I, Coelho Neto MA, Nastri CO, Bhagavath B, Lindheim SR, Martins WP. Septate uterus according to ESHRE/ESGE, ASRM and CUME definitions: association with infertility and miscarriage, cost and warnings for women and healthcare systems. *Ultrasound Obstet Gynecol* 2019; 54: 800–814.
- 13-Salim R, Woelfer B, Backos M, Regan L, Jurkovic D. Reproducibility of three-dimensional ultrasound diagnosis of congenital uterine anomalies. *Ultrasound Obstet Gynecol* 2003; 21: 578–582.
- 14-Ludwin A, Pitynski K, Ludwin I, Banas T, Knafel A. Two- and three-dimensional ultrasonography and sonohysterography versus hysteroscopy with laparoscopy in the differential diagnosis of septate, bicornuate, and arcuate uteri. *J Minim Invasive Gynecol* 2013; 20: 90–99.
- 15-Knez J, Saridogan E, Van Den Bosch T, Mavrelas D, Ambler G, Jurkovic D. ESHRE/ESGE female genital tract anomalies classification system-the potential impact of discarding arcuate uterus on clinical practice. *Hum Reprod*. 2018 Apr 1;33(4):600-606.
- 16-Prior M, Richardson A, Asif S, Polanski L, Parris-Larkin M, Chandler J, Fogg L, Jassal P, Thornton JG, Raine-Fenning NJ. Outcome of assisted reproduction in women with congenital uterine anomalies: a prospective observational study. *Ultrasound Obstet Gynecol* 2018;51: 110 – 117.
- 17-Surrey ES, Katz-Jaffe M, Surrey RL, Small AS, Gustofson RL, Schoolcraft WB. Arcuate uterus: is there an impact on in vitro fertilization outcomes after euploid embryo transfer? *Fertil Steril* 2018;109: 638 – 643.23.

Surgical Treatment of the Septate Uterus

Ursula Catena

CLASS Hysteroscopy Center

Fondazione Policlinico Universitario A. Gemelli IRCCS. Rome, Italy

Septate Uterus is the most common Mullerian anomaly, with an incidence of 5.5% in the unselected population, 8.0% in infertile women, 13.3% in those with a history of miscarriage, and 24.5% in those with miscarriage and infertility (1).

For the diagnosis of uterine septum, three-dimensional (3D) ultrasound has become the non-invasive gold standard method. If performed in secretory period, it provides a clear image of the internal and external contours of the uterus and makes the evaluation of uterine morphology more reproducible. With this tool we can have a diagnostic suspicion being less invasive than other commonly used radiological and surgical diagnostic modalities (magnetic resonance, laparoscopy). In fact, in the past years' laparoscopy was performed to assess the morphology of the uterine fundus and to establish a differential diagnosis between septate and bicornuate uterus. Nowadays, the use of 3D ultrasounds has made this approach obsolete even if remains the first choice in complex cases and when associated pelvic pathologies are suspected.

By using ultrasound, a standardized classification system to diagnose uterine septum is required. In recent decades, many classifications have been

published. Currently, one of the most used classifications is the ESHRE/ESGE classification of 2013 (2) which allow an easy categorization of all malformations of the female genital tract.

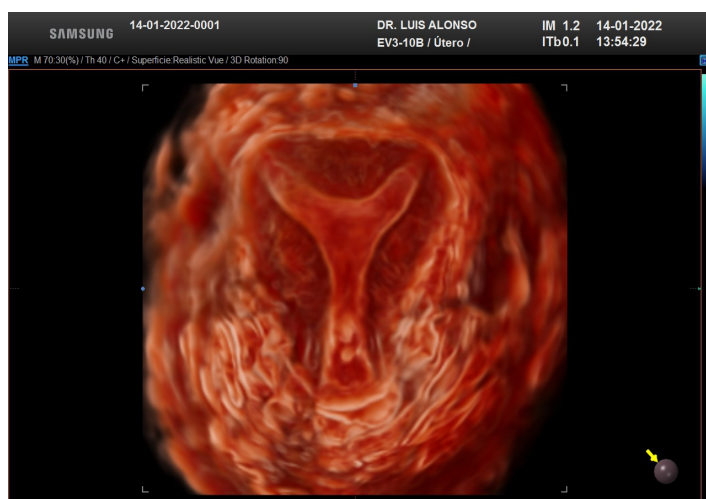
By looking at the diagnostic process, after ultrasound 3D evaluation, a diagnostic office hysteroscopy is mandatory to confirm the ultrasound suspect and to exclude other associated anomalies (i.e. associated malformations of cervix and vagina).

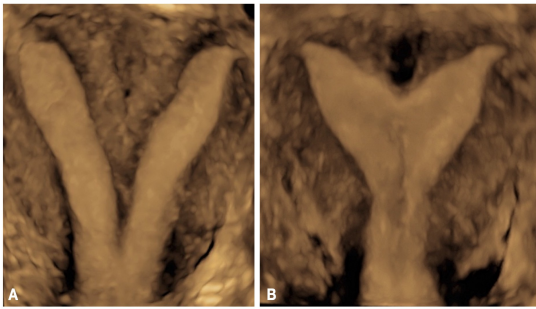
Treatment of partial septate uterus remains a very controversial topic. Studies reported no differences in terms of pregnancy rate in patients underwent metroplasty versus non operated patients (3, 4). Some other authors recommend hysteroscopic treatment of uterine septum, as it improves the live birth rate (5, 6).

In this scenario an individualized treatment should be planned: patients with incidental diagnosis of partial uterine septum with negative obstetric anamnesis could avoid surgery, while patients with primary infertility and recurrent abortion should be treated. In these selected cases, the patient should be referred to specialized centers.

Historically, metroplasty for uterine septum was suggested only in patients with recurrent pregnancy loss. Tompkins and Jones' laparotomic hysterotomy was the standard technique, it provided quite good results (7), but resulting in a high morbidity, long time before conception and subsequent cesarean delivery.

In 1974, Edstrom first described the hysteroscopic resection of uterine septum (8). Since that moment, hysteroscopic surgical technique has been refined, technological improvements have led to miniaturization of endoscopes, resulting in a safer and less-invasive diagnostic and therapeutic tool.





3D Ultrasounds. (A) Preoperative 3D ultrasounds evaluation in a case of complete uterine septum (Class U2b according to ESHRE/ESGE classification). (B) Postoperative 3D ultrasounds evaluation in the secretive phase of the first menstrual cycle after suspension of hormonal therapy.

The change that we can observe over time regarding indications and actual clinical practice is very evident: the increasing availability of less invasive surgical approaches has made possible a greater application of these techniques, which is increasingly based on the consideration of future reproductive options for woman and that allow patient herself to be involved in this decision-making process. Furthermore, the necessity to perform hysteroscopic metroplasty only in dedicated centers with experts trained in the management of complex Uterine Malformations is generally shared. Obviously, surgeons who operate in high-volume centers with centralized care - for example 50-100 women with septate uterus per year - can certainly have better outcomes.

Some authors perform metroplasty in the early proliferative phase of the menstrual cycle, without pharmacological preparation of the endometrium. However, in particular in case of complete uterine septum, it is advisable to administer progestin therapy to reduce endometrial thickness. This allows a better vision during the procedure and reduce the intraoperative bleeding.

Hysteroscopic treatment of uterine septum aims to restore a physiological morphology of the uterine cavity, maintaining, an adequate fundal thickness between 10 and 15 mm.

Metroplasty consists in incising the septum along the median plane, starting from the apex and proceeding gradually towards the fundus. Landmarks during the procedure have always to be tubal ostia. This trick allows to maintain the correct line of incision and avoids perforation that may occur, most frequently, at the level of the posterior uterine wall when the correct line of incision is lost

The procedure is considered completed when the hysteroscope can be freely move from one tubal ostium to the other and when ostia are simultaneously visible from a panoramic hysteroscopic point of view.

In 2016, Di Spiezio et al. proposed the use of a graduated intrauterine palpator specifically designed to measure the length of the resected septum, in order to correlate this measure to the preoperative 3D ultrasounds evaluation. The graduate intrauterine palpator is a reusable 5Fr instrument that can be insert into the operative channel of all modern miniaturized hysteroscopes. It allows to obtain an objective measure of the septum removed avoiding two steps metroplasty (9).

If a cervical septum is present, the resection should be considered. In fact, some authors suggest that the combined resection can be offered without increasing the risk of cervical incompetence (10).

Currently, two main treatment options are available for uterine septum: metroplasty using miniaturized (5Fr) instruments; metroplasty with standard resectoscope or mini-resectoscope. We will also describe another proposed treatment option: metroplasty using Tissue Removal Devices (TRDs).

METROPLASTY WITH MINIATURIZED INSTRUMENTS

This approach can be performed both in an office setting without anesthesia and/or analgesia and under conscious sedation/general anesthesia. The choice is guided by the extension of uterine septum. Surely, it is advisable to treat in an office setting only small uterine septa, because of the patient discomfort during the septum incision, using electrodes.

Before the advent of mini-resectoscope, this minimally invasive approach was surely important to avoid blind cervical dilation in patients with uterine anomalies, that is not an easy task. Moreover, this technique is indicated for “retouching” septa previously treated under anesthesia.

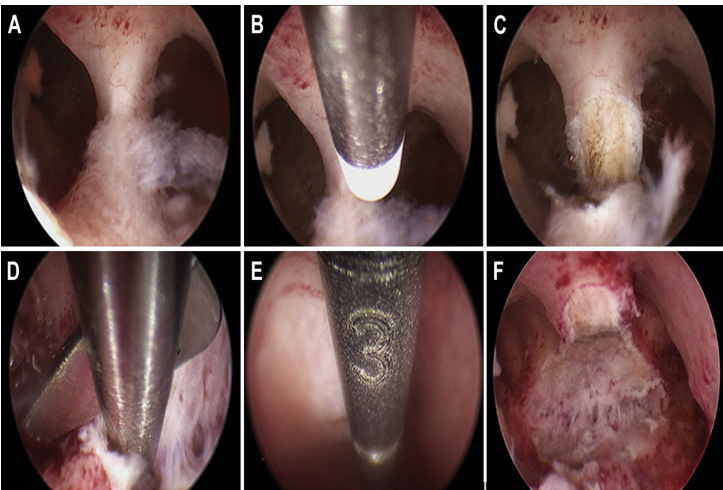


Figure 1. Hysteroscopic metroplasty with miniaturized instruments on a U2a uterus (partial septate uterus). The first 2.5 cm of the septum are resected using a 5F bipolar electrode (A–C) followed by the last 0.5 cm, which are incised using blunt scissors (D). (E) Use of the intrauterine palpator to measure the resected septum length to correlate with the preoperative 3D ultrasounds evaluation. (F) Final view of the uterine cavity (7).

Metroplasty with miniaturized instruments involves a vaginoscopic approach using a 5mm or smaller hysteroscope with a 5Fr operative channel. Saline solution is used as distension medium. The 5Fr instruments used for this surgical procedure are straight bipolar electrodes and miniaturized blunt or sharp scissors. The resection of the septum starts at the septum apex with a bipolar electrode, providing the removal of three quarters of the septum. Then, blunt scissors are used to refine the base of the septum, and the intrauterine palpator is used to measure the length of the removed septum (Fig. 1).

METROPLASTY WITH 26 FR RESECTOSCOPE

Before the advent of 5mm bipolar mini-resectoscope, the use of 26Fr resectoscope was the standard option to treat complete uterine septa. This technique always needs a blind dilatation of the cervical canal with Hegar dilators, that, in case of uterine anomalies, could be difficult and with high risk of uterine perforation.

The resectoscopic technique involves the use of straight cutting loops or a pointed electrode, with anterograde movements of the electrode performed in the median plane of the septum, with the hook oriented transversely (i.e., perpendicular to the septum). During anterograde resection of the septum, the electrode also allows latero-medial

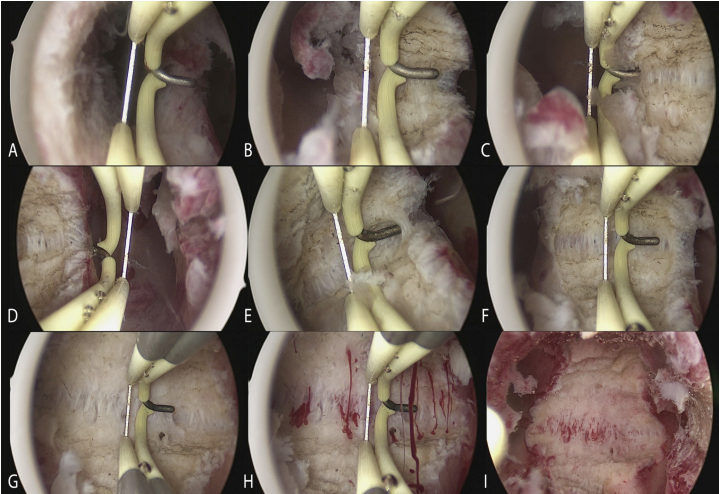


Figure 2. Hysteroscopic metroplasty with 26Fr resectoscope. Anterograde movements of the electrode performed in the median plane of the septum, with the hook oriented transversely (i.e., perpendicular to the septum) (A–B–F–G). However, during anterograde resection of the septum, this electrode also allows latero-medial movements with the hook oriented toward the central portion of the septum (C–D). During resection of the septum, it is useful to engage the fibrotic tissue with the electrode, followed by retrograde resection using the loop (E). In close proximity to the base of the septum, by switching off the supply of liquid distension medium (and therefore reducing intrauterine pressure) incipient bleeding in the myometrial venous sinuses becomes noticeable (H–I) (courtesy of Prof. A. Di Spiezio Sardo).

movements with the hook oriented toward the central portion of the septum. Metroplasty is stopped once both tubal ostia were simultaneously visible in a panoramic hysteroscopic view (Fig. 2).

Another suggestion is to reduce the intrauterine pressure, switching off the supply of distension medium; the incipient bleeding in the myometrial venous sinuses becomes noticeable, and this is described to be one of the methods to know when ending the procedure. This consideration was based on the wrong concept that the septum is composed only by fibrous connective tissue, whereas different studies have shown that it is composed by a muscular component interlaced with connective tissue (11).

Treatment of a septate uterus exclusively based on this rationale carried the risk of undertreatment of the anomaly, which may adversely affect patient reproductive outcomes.

METROPLASTY WITH 15FR BIPOLAR MINI-RESECTOSCOPE

In 2018, the advent of 15Fr (5mm) bipolar mini-resectoscope have completely change the way to

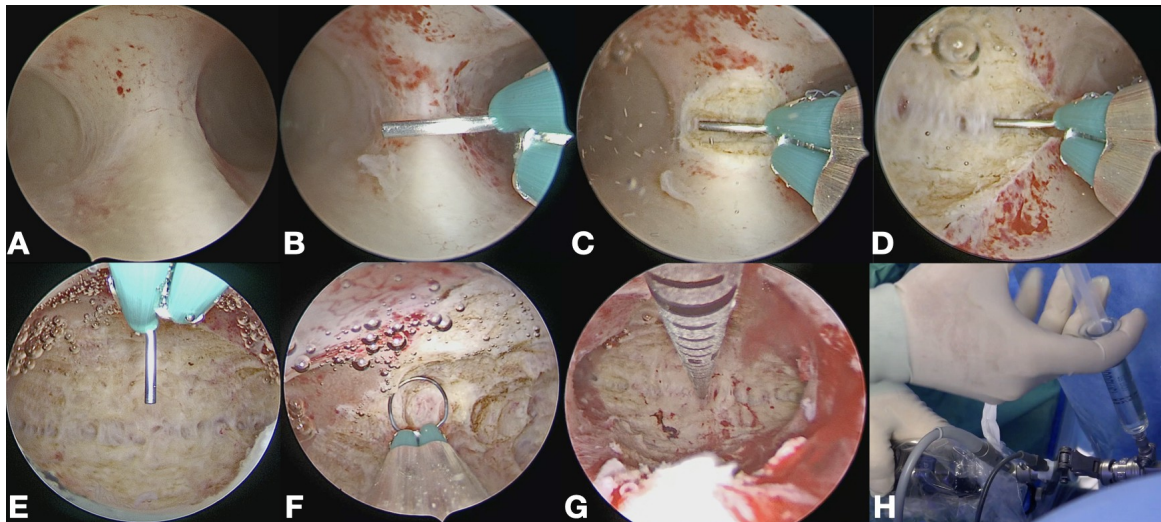


Figure 3. Hysteroscopic metroplasty with 15Fr mini-resectoscope. (A) Hysteroscopic view of the septum. (B-C-D-E) Septum incision with a pointed electrode (Collins loop) from its apex towards the fundus, until both tubal ostia are visualized on the same line. (F) Resection of the fibromuscular tissue that remains at the level of the anterior and posterior uterine wall with a 90° cutting loop. (G) Use of the intrauterine palpator to measure the resected septum length to correlate with the preoperative 3D ultrasounds evaluation. (H) Hyaluronic acid gel injection inside the uterine cavity at the end of the procedure.

treat uterine malformations. In fact, with this tool, surgeons maintain all the advantages of the resectoscope, without the need of cervical dilatation and avoiding the risk of uterine perforation. Moreover, this instrument allows the possibility, at the end of the procedure, to change from the external sheath to an “examination insert” with a 5Fr operative channel, that allows the use of 5Fr instruments, as scissors to refine the septum and intrauterine palpator to measure the resected septum length.

The procedure is performed under conscious sedation and lasts about 20-30 minutes. The first surgical step consists in incising the septum with a pointed electrode (Collins loop) from its apex towards the fundus, until both tubal ostia are visualized on the same line. The second step, according to Fascilla et al., is to resect the fibromuscular tissue that remains at the level of the anterior and posterior uterine wall with a 90° cutting loop, until removal of the central muscular component is achieved (11).

At the end of the procedure, haemostasis is checked. The intrauterine graduated palpator is inserted in the 5Fr channel of the “examination insert” to measure the resected septum length and to correlate this measure to the preoperative 3D ultrasounds evaluation (Fig. 3).

Some authors proposed the injection of hyaluronic acid gel inside the uterine cavity after metroplasty in order to prevent intrauterine adhesions (IUAs). This approach seems to reduce IUAs formations in patients treated for uterine septum (12).

METROPLASTY WITH TISSUE REMOVAL DEVICES (TRD)

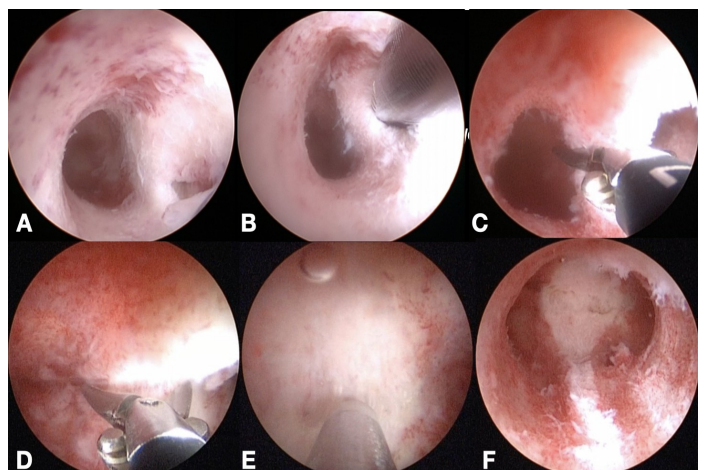


Figure 4. Hysteroscopic metroplasty with TRDs in a patient with complete uterine septum (Class U2bC0V0, according to ESHRE/ESGE Classification). IBS was used to enter the smaller left uterine cavity (A-B). Then, 3mm scissors were inserted in the IBS operative channel to cut the septum (C-D) and IBS was again used to resect the base of the septum (E). (F) Final aspect of the uterine cavity after complete metroplasty (courtesy of Dr. G. Bigatti).

Some authors proposed metroplasty using TRDs. In particular, Intrauterine Bigatti Shaver (IBS) was used in a patient with complete uterine septum (Class U2bC0V0, according to ESHRE/ESGE Classification). IBS was used to enter the smaller left uterine emicavity. Then, 3mm scissors were inserted in the IBS operative channel to cut the septum and IBS was again used to resect the base of the septum (Fig. 4).

In view of the limited number of cases reported, it is too early to make any claims about the efficacy of TRDs to treat uterine septa.

FOLLOW-UP

After 30-40 days from the procedure, an office hysteroscopic control must always be performed: this prevents IUAs formation and allows to control the uterine cavity. There is controversy about the management of a residual septum detected on hysteroscopic follow-up, but this finding is very common, and it can be easily managed with 5Fr miniaturized instruments during office hysteroscopy (Fig. 5).

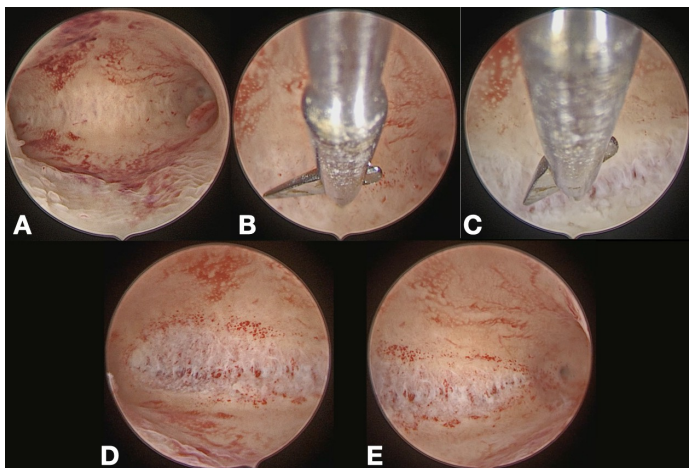


Figure 5. Office hysteroscopic control 38 days after the treatment of a U2b uterus (complete uterine septum) with 15Fr miniresectoscope. (A) Presence of a 4mm fundal indentation. (B-C) Fundal cuts with 5Fr scissors. (D-E) Final view of the uterine cavity

The need for a second surgical step under sedation is infrequent.

After office hysteroscopic control, hormonal therapy can be stopped, and patient may seek pregnancy from the next menstrual cycle. In the secretive phase of the next cycle, patients undergo the definitive post-operative 3D ultrasounds evaluation.

REFERENCES

- Chan YY, Jayaprakasan K, Zamora J, Thornton JG, Raine-Fenning N, Coomarasamy A (2011) The prevalence of congenital uterine anomalies in unselected and high-risk populations: a systematic review. *Hum Reprod Update* 17(6):761–771
- Grimbizis GF, Gordts S, Di Spiezo Sardo A, Brucker S, De Angelis C, Gergolet M, Li TC, Tanos V, Brölmann H, Gianaroli L, Campo R. The ESHRE-ESGE consensus on the classification of female genital tract congenital anomalies. *Gynecol Surg.* 2013 Aug;10(3):199-212. doi: 10.1007/s10397-013-0800-x. Epub 2013 Jun 13. PMID: 23894234; PMCID: PMC3718988.
- Rikken JFW, Verhorstert KWJ, Emanuel MH, Bongers MY, Spinder T, Kuchenbecker WKH, Jansen FW, van der Steeg JW, Janssen CAH, Kapiteijn K, Schols WA, Torrens B, Torrance HL, Verhoeve HR, Huirne JAF, Hoek A, Nieboer TE, van Rooij IAJ, Clark TJ, Robinson L, Stephenson MD, Mol BWJ, van der Veen F, van Wely M, Goddijn M. Septum resection in women with a septate uterus: a cohort study. *Hum Reprod.* 2020 Jul 1;35(7):1578-1588. doi: 10.1093/humrep/dez284. Erratum in: *Hum Reprod.* 2020 Jul 1;35(7):1722. PMID: 32353142; PMCID: PMC7368397.
- Rikken JFW, Kowalik CR, Emanuel MH, Bongers MY, Spinder T, Jansen FW, Mulders AGMJ, Padmeh R, Clark TJ, van Vliet HA, Stephenson MD, van der Veen F, Mol BWJ, van Wely M, Goddijn M. Septum resection versus expectant management in women with a septate uterus: an international multicentre open-label randomized controlled trial. *Hum Reprod.* 2021 Apr 20;36(5):1260-1267. doi: 10.1093/humrep/deab037. PMID: 33793794; PMCID: PMC8058590.
- Linee Guida per l'isteroscopia ambulatoriale da un'iniziativa della "Società Italiana di Endoscopia Ginecologica"(SEGi) <https://www.sigo.it/wp-content/uploads/2015/10/linee-guida-isteroscopica1.pdf>
- Saridogan E, Salman M, Direk LS, Alchami A. Reproductive Performance Following Hysteroscopic Surgery for Uterine Septum: Results from a Single Surgeon Data. *J Clin Med.* 2021 Jan 2;10(1):130. doi: 10.3390/jcm10010130. PMID: 33401655; PMCID: PMC7795865.
- Manuale per un'isteroscopia moderna. Gruppo Isteroscopisti della Scuola Italiana di Chirurgia Mini Invasiva Ginecologica. Cap 19.
- Edström K. Intrauterine surgical procedures during hysteroscopy. *Endoscopy* 1974; 6:175-81.
- Di Spiezo Sardo A, Zizolfi B, Bettocchi S, Exacoustos C, Nocera C, Nazzaro G, da Cunha Vieira M, Nappi C. Accuracy of Hysteroscopic Metroplasty With the Combination of Presurgical 3-Dimensional Ultrasonography and a Novel Graduated Intrauterine Palpator: A Randomized Controlled Trial. *J Minim Invasive Gynecol.* 2016 May-Jun;23(4):557-66. doi: 10.1016/j.jmig.2016.01.020. Epub 2016 Jan 30. PMID: 26829218.
- Wang Z, An J, Su Y, Liu C, Lin S, Zhang J, Xie X. Reproductive outcome of a complete septate uterus after hysteroscopic metroplasty. *J Int Med Res.* 2020 Mar;48(3):300060519893836. doi: 10.1177/0300060519893836. Epub 2019 Dec 19. PMID: 31854214; PMCID: PMC7607289.
- Fascilla FD, Resta L, Cannone R, De Palma D, Ceci OR, Loizzi V, Di Spiezo Sardo A, Campo R, Cicinelli E, Bettocchi S. Resectoscopic Metroplasty with Uterine Septum Excision: A Histologic Analysis of the Uterine Septum. *J Minim Invasive Gynecol.* 2020 Sep-Oct;27(6):1287-1294. doi: 10.1016/j.jmig.2019.11.019. Epub 2019 Dec 5. PMID: 31812613.
- Tafti SZG, Javaheri A, Firoozabadi RD, Ashkezar SK, Abarghouei HF. Role of hyaluronic acid intrauterine injection in the prevention of Asherman's syndrome in women undergoing uterine septum resection: An RCT. *Int J Reprod Biomed.* 2021 Apr 22;19(4):339-346. doi: 10.18502/ijrm.v19i4.9060. PMID: 33997593; PMCID: PMC8106814.

New Concepts in the Treatment of the Septate Uterus

Stefano Bettocchi

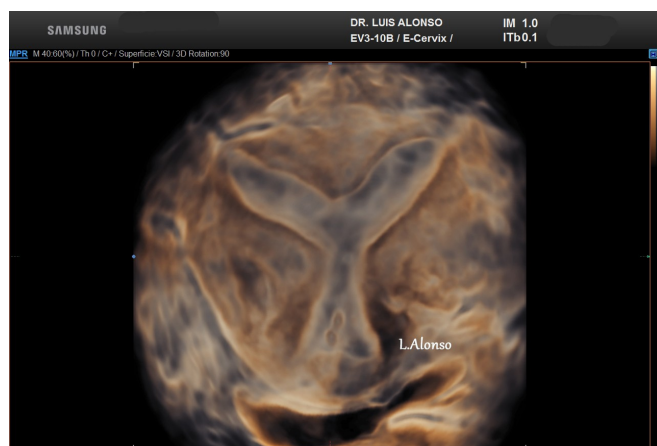
University of Foggia, Italy

Hysteroscopy Newsletter Vol 8 Issue 2

Since the early 90's we advisedly decided to abandon the old beaten path, departing from the previous dogmas and look at the uterine cavity from a completely different perspective with the only aim to come across something completely new.

Thanks to this approach and methodically implementing some great intuitions time after time, we first put aside the traditional and outdated approach to hysteroscopy and nowadays clinicians performing office hysteroscopy worldwide use the vaginoscopic approach: quicker and less painful. Apart from this Copernican revolution we proposed a contemporary approach to almost every concept in the field of hysteroscopy such as myomas, cervical stenosis... and on the other hand we helped to develop increasingly less invasive and effective devices.

In the last few years we strongly believed in a change of perspective in the treatment of one of the most debated uterine pathologies: uterine septum. We were all missing something since, despite extensive research, little information were available about the ultrastructural anatomy of the septum. Some papers showed limited data or poor methodology when collecting samples.



Then again here we are with "a new perspective on an old issue" with a deep insight on septum anatomy. Only describing new features we could investigate those aspects influencing the outcome of metroplasty, in terms of both recurrence and fertility outcomes.

We perform each metroplasty during the early proliferative phase (day 4 to 9) under general anesthesia using a "native" bipolar 15 Fr. Mini-Resectoscope (Karl Storz Co., Tuttlingen, Germany) connected to an advanced bipolar generator (Autocon III 400, Karl Storz Co., Tuttlingen, Germany). Intrauterine pressure is carefully kept stable (around 45 mm/Hg) using a dedicated pump (Endomat, Karl Storz Co., Tuttlingen, Germany).

Usually the septum is initially incised "in a classic fashion" adopting an "L-shape" bipolar electrode (Karl Storz Co., Tuttlingen, Germany) up to the fundal area. The septum is then longitudinally transected into two parts, forming an anterior and a posterior triangle on each uterine wall, with the base on the fundus. When we started to study the fine anatomy of the septum, using the bipolar loop (Karl Storz Co., Tuttlingen, Germany), we systematically resected the two triangles in parallel, uninterrupted, long strips, from the fundus to the apex and then we removed each "chip" immediately after the resection and reassembled the septum in vitro in order to reconstruct the macroscopic tridimensional structure for a complete morphological and histological evaluation.

Thanks to this painstaking analysis we are now able to describe the fine anatomy of the muscle bundles taking part to the septum: in the apex and on the borders the muscle cells are arranged in different-sized nodules circumscribed by thin collagenous septa. Vessels are distributed in the collagen fibers around the muscle cells while only few capillary vessels

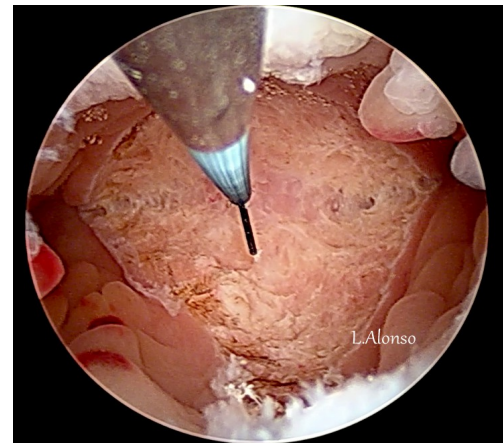
supply the muscle nodules. This pattern remembers the microscopic arrangement of leiomyomas. In the core of the septa, near the base, the muscle bundles show a linear course, with concurrent collagen fibers and vessels.

In our opinion, understanding the histology of the septum was mandatory to determine the best surgical approach to this condition. First of all the septum should no longer be considered as a fibrous notch in the middle of the cavity, but as a real three-dimensional structure with a "myoma-like" component. This component is mostly present at the uterine fundus, where it forms two large circular structures resembling "Mickey Mouse ears", then reduces while caudalizing, and thickens once again at the level of the free distal margin. Furthermore at the cranial portion of the septum and between the "Mickey Mouse ears", we described a notch of "good" muscle near the normal myometrium where the muscle fibers have a parallel distribution.

Once we got rid of previous misconceptions and redefined the concept of the septum as a complex structure based on islands of muscle fibers arranged in a context of collagen tissue we developed and propose a new surgical approach based on four principal steps: first of all we completely incise/resect the "Mickey Mouse ears" and then we resect the apex of the septum until the central muscular core is reached. During this step and given the parallel arrangement of muscular fibers in this area, the fundal area spontaneously flattens and the central muscular core is finally resected.

Apart from adequate anatomical knowledge which is essential for successful clinical practice, our proposal should also persuade the reader from a technical point of view as relies on the implementation in our clinical practice of the 15 Fr. Mini-Resectoscope which itself grants at least two more great advantages. First of all it's a native bipolar system and carries itself all the clear advantages of bipolar energy: the plasma effect of bipolar current allows better cut and coagulation. In the monopolar technique, the current passes through many tissues outside the surgeon's visual control and the risk of thermal injuries at distant organs or tissues, by direct contact of instruments, imperfection of insulation or diffusion of the electric current, is reduced in the bipolar technique.

Everything said up to now represents a new frontier in the modern surgical approach to uterine septum; otherwise large multicentric trials are needed in order to evaluate and re-evaluate the endometrial function after surgery and its impact on fertility, of which we know relatively little or nothing.



Moreover it has minor risk of interference on other electronic equipment (electrocardiogram, pace makers and others) simultaneously connected to the patient. Incidence of overflow syndrome in gynaecology and TUR syndrome in urology varies considerably in the literature, ranging from 0.18% to 10.9%. The use of saline solution for distension media of the uterine cavity is the principal advantage of this technology avoiding hypotonic non-electrolyte solution that can cause fluid overload during the surgical procedure.

Optimised resection current provided by the Karl Storz Autocon III 400 allows a better coagulation during resection with reduced bleeding. Furthermore, the coagulation capacity by itself is extremely more powerful in the bipolar system in comparison with monopolar. This avoids time-consuming re-coagulation after resection for coagulation and minor air bubbles and less bleeding allow a better vision during surgery improving results.

Dilatation of the cervical Os enough to introduce the classic 26 Fr resectoscope, apart from the unnecessary traumatism in a woman in childbearing age, surely distorts normal anatomy compared to what we see with a 4 or 5 millimeters hysteroscope at the time of diagnosis. Using a 5 mm bipolar resectoscope and avoiding dilatation, we preserve normal anatomy in regard to the septum itself and the overall uterine morphology.

Everything said up to now represents a new frontier in the modern surgical approach to uterine septum; otherwise large multicentric trials are needed in order to evaluate and re-evaluate the endometrial function after surgery and its impact on fertility, of which we know relatively little or nothing.

Reproductive Impact of the Septate Uterus

Maria Carrera

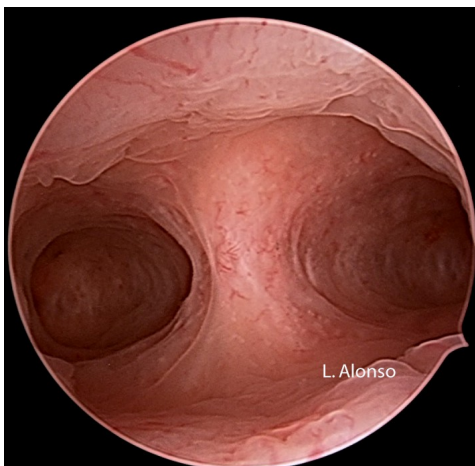
Reproductive Medicine. Hospital Universitario Doce de Octubre. Madrid. Spain

Hysteroscopy Newsletter Vol 8 Issue 2

INTRODUCTION

Congenital uterine anomalies are a complex group of female genital system abnormalities caused by alterations in development, formation or fusion of the Müllerian ducts during fetal life. The prevalence varies depending upon the population studied. In a systematic review published by Chan et al. in 2011 including data from 94 cohort studies, the prevalence in unselected populations was 5.5% (95% confidence interval (CI), 3.5–8.5). The authors did not find a significant increase in prevalence among infertile patients (8.0%; 95% CI, 5.3–12.0, $P=0.239$); although women with a history of miscarriage had a significant increase in prevalence of müllerian anomalies when compared with unselected populations (13.3%; 95% CI, 8.9–20; $P=0.011$). Women with a history of miscarriage in association with infertility also had significantly more anomalies than controls (24.5%; 95% CI, 18.3–32.8; $P=0.001$).

Septate and subseptate uterus, considered as a canalization defect due to the incomplete resorption of the midline septum, are the most frequent congenital anomaly of the uterus accounting for around 35% of all uterine abnormalities diagnosed.



The ultimate mechanism by which a uterine septum is associated with an increased incidence of undesired reproductive and obstetric outcomes is not yet known. In this regard, several underlying mechanisms have been proposed as poor vascularization of the septum with a reduced sensitivity to hormonal changes, a compromise of space with a reduced uterine cavity, morpho-functional differences of the endometrium covering the septum, decreased steroid estrogens receptors, decreased serum cysteine aminopeptidase or decreased neutralization of circulating oxytocin.

SEPTATE AND SUBSEPTATE UTERUS AND REPRODUCTIVE AND OBSTETRIC RESULTS

The relationship between the diagnosis of müllerian anomalies, and specifically, with a diagnosis of septate or subseptate uterus and adverse reproductive and obstetric outcomes has been already established.

Four systematic reviews with meta-analysis have properly addressed this issue. In 2011, Chan et al. published a systematic review with meta-analysis including reproductive and obstetric results from nine studies. Regarding septate and subseptate uterus, these authors found a significant decrease in clinical pregnancy rates (RR, 0.86; 95% CI, 0.77–0.96) and a higher risk of first trimester miscarriage (RR, 2.89; 95% CI, 2.02–4.14). The risk of second trimester miscarriage was increased only in case of septate uterus diagnosis (RR, 3.74; 95% CI, 1.57–8.91). Septate and subseptate uteri were also associated with a higher risk of preterm birth (RR, 2.14; 95% CI, 1.48–3.11) and fetal malpresentation (RR, 6.24; 95% CI, 4.05–9.62).

A second systematic review published by Venetis et al in 2014 included data from 25 studies. The authors found a decreased chance of natural pregnancy (RR 0.86, 95% CI 0.77–0.96) but failed to find an association with decreased chances of success

| Study | Sub-analysis | Clinical Pregnancy | 1 st trim. miscarriage | 2 nd trim. miscarriage | Preterm birth | Fetal mal presentation | C section |
|---------------------------|-----------------|-------------------------------------|-----------------------------------|-----------------------------------|---------------------|------------------------|-------------------|
| Chan 2011 (RR*) | NA [^] | 0.86(0.77-0.96) | 2.89(2.02-4.14) | 3.74 (1.57-8.91) | 2.14 (1.48-3.11) | 6.24 (4.05-9.62) | NA |
| Venetis 2014 (RR) | NA | 0.86 (0.77-0.96) natural gestations | 2.65 (1.39-5.06) | 2.95 (1.51-5.77) | 2.11 (1.51 to 2.94) | - | NA |
| Kim 2021 (OR**) | Subseptate | - | 4.36 (2.64-7.21) | - | 3.15 (1.34-7.4) | 11.42 (3.74-34.86) | 5.91 (1.59-21.95) |
| | Septate | 0.45 (0.21-0.95) | 2.55 (1.33-4.91) | 4.33 (2.52-7.43) | 2.93 (2.01-4.28). | 11.49 (5.24-25.17) | 4.84 (2.33-10.02) |
| Panagiotopoulos 2022 (OR) | NA | - | - | - | 4.06 (2.89-5.70) | 13.76 (5.52-34.32) | 5.19 (1.84-14.62) |

*RR=Relative Risk;**OR=Odds Ratio;^NA=Not Available

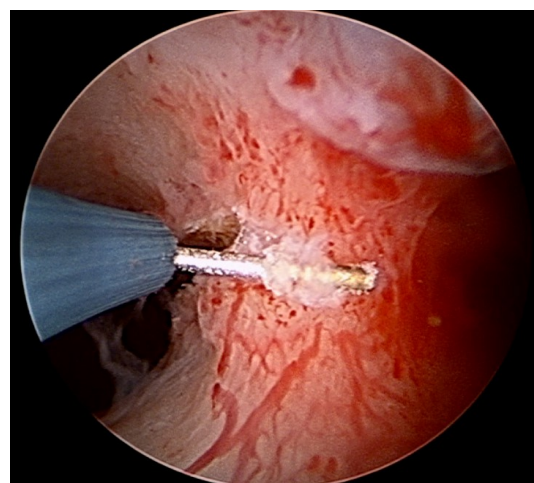
in medically assisted reproduction (MAR) (RR 0.89, 95% CI 0.24-3.29). The risk of first trimester (RR 2.65, 95% CI 1.39-5.06) and second trimester miscarriage (RR 2.95, 95% CI 1.51-5.77) were both significantly increased. The authors also found significantly more chances of preterm birth (RR 2.11; 95% CI, 1.51-2.94) although other adverse obstetric outcomes were not increased.

Two meta-analyses involving a higher number of studies have been written recently. In 2021, Kim et al. included reproductive and obstetric results from 37 studies and found that septate uterus, but not subseptate, was associated with lower chances of clinical pregnancy (OR 0.45; 95% CI 0.21-0.95) and live birth (OR 0.25; 95% CI 0.09-0.75). These authors found that both subseptate (OR 4.36; 95% CI 2.64-7.21) and septate uterus (OR 2.55; 95% CI 1.33-4.91) had an increased risk of first trimester miscarriage. Again, second trimester miscarriage was increased only in cases of complete septum (OR 4.33; 95% CI 2.52-7.43) but not in cases of a partial septum. Regarding obstetric outcomes, preterm birth risk was increased both in subseptate (OR 3.15; 95% CI 1.34-7.4) and septate uterus (OR 2.93; 95% CI 2.01-4.28). Other adverse obstetrics results were significantly increased as fetal malpresentation, with an OR 11.42 (95% CI 3.74-34.86) for subseptate uterus and an OR 11.49 (95% CI 5.24-25.17) in case of septate uterus and cesarean section with an OR 5.91 (95% CI 1.59-21.95) in case of subseptate uterus and an OR 4.84 (95% CI 2.33-10.02) in case of complete septum.

Early this year, Panagiotopoulos et al. included 47 studies in another systematic review with meta-analysis of obstetric complications of congenital uterine anomalies. These authors found a significant increase in preterm birth (OR 4.06; 95% CI, 2.89, 5.70), fetal malpresentation (OR 13.76; 95% CI 5.52-34.32), cesarean section (OR 5.19; 95% CI, 1.84-14.62) and other adverse outcomes.

THE ROLE OF HYSTEROSCOPIC METROPLASTY IN PATIENTS WITH POOR REPRODUCTIVE HISTORY

Grimbizis et al. were the first authors to summarize the improvement on reproductive results after hysteroscopic metroplasty in patients with septate uterus, achieving term delivery rates



around 75% and live birth rates around 85%. Valle et al. , in 2013, in a systematic review concluded that hysteroscopic metroplasty clearly improves obstetric results from previous abdominal metroplasty procedures with rates of viable pregnancies near 80% in patients with previous spontaneous abortions even recurrent pregnancy losses. Venetis et al. in 2014 found a significantly reduced chance of spontaneous abortion in patients treated with hysteroscopic metroplasty (RR 0.37, 95% CI 0.25 to 0.55) compared to untreated patients. But, in 2021, Rikken et al. published the results of a multicentric randomized controlled trial of small sample size. The authors failed to find differences in reproductive outcomes between patients having septum resection and patients without treatment. This study has been criticized due to the small sample size, the length of the recruitment period and the multicentric nature. Krishan et al. in 2021, published a new meta-analysis including seven studies and found a decreased risk of spontaneous abortion (OR 0.25, 95% CI 0.07–0.88) and of fetal malpresentation (OR 0.22, 95% CI 0.06–0.73). in patients treated with hysteroscopic metroplasty compared to controls.

Our group recently published another systematic review with meta.-analysis, Carrera et al., 2021 of eleven studies involving 1589 patients with either complete or partial septate uterus and found that miscarriage risk was significantly reduced with hysteroscopic metroplasty in both patients with complete and partial uterine septum (OR 0.45, 95% CI 0.22-0.90). Also, we found a significant reduction in fetal malpresentation (OR 0.32, 95% CI 0.16- 0.65). Our results are in agreement with those published in previous meta-analyses.

CONCLUSIONS

Both reproductive and obstetric outcomes are significantly worse in patients with a diagnosis of complete or partial uterine septum. Hysteroscopic metroplasty, as has been showed in various systematic reviews, significantly reduces the risk of miscarriage and of fetal malpresentation. Although the quality of the available evidence is limited due to the mainly retrospective nature and the heterogeneity of the primary studies, the hysteroscopic metroplasty should be recommended in patients with a diagnosis of septate uterus and a history of infertility, recurrent pregnancy losses or other related adverse outcomes.

REFERENCES

1. Chan YY, Jayaprakasan K, Zamora J, Thornton JG, Raine-Fenning N, Coomarasamy A. The prevalence of congenital uterine anomalies in unselected and high-risk populations: a systematic review. :11.
2. Grimbizis GF, Camus M, Tarlatzis BC, Bontis JN, Devroey P. Clinical implications of uterine malformations and hysteroscopic treatment results. *Human reproduction update*. 2001;7(2):161–74.
3. Fedele L, Dorta M, Brioschi D, Giudici MN, Candiani GB. Pregnancies in septate uteri: outcome in relation to site of uterine implantation as determined by sonography. *American Journal of Roentgenology*. 1989;152(4):781–4.
4. Fedele L, Bianchi S, Marchini M, Franchi D, Tozzi L, Dorta M. Ultrastructural aspects of endometrium in infertile women with septate uterus. *Fertility and sterility*. 1996;65(4):750–2.
5. Venetis CA, Papadopoulos SP, Campo R, Gordts S, Tarlatzis BC, Grimbizis GF. Clinical implications of congenital uterine anomalies: a meta-analysis of comparative studies. *Reproductive biomedicine online*. 2014;29(6):665–83.
6. Carrera M, Millan FP, Alcázar JL, Alonso L, Caballero M, Carugno J, et al. Effect of Hysteroscopic Metroplasty on Reproductive Outcomes in Women with Septate Uterus: Systematic Review and Meta-Analysis. *Journal of minimally invasive gynecology*. 2021;
7. Valle RF, Ekpo GE. Hysteroscopic metroplasty for the septate uterus: review and meta-analysis. *Journal of minimally invasive gynecology*. 2013;20(1):22–42.
8. Blum M. Comparative study of serum CAP activity during pregnancy in malformed and normal uterus. 1978;
9. Chan YY, Jayaprakasan K, Tan A, Thornton JG, Coomarasamy A, Raine-Fenning NJ. Reproductive outcomes in women with congenital uterine anomalies: a systematic review. *Ultrasound in Obstetrics & Gynecology*. 2011;38(4):371–82.
10. Panagiotopoulos M, Tseke P, Michala L. Obstetric Complications in Women With Congenital Uterine Anomalies According to the 2013 European Society of Human Reproduction and Embryology and the European Society for Gynaecological Endoscopy Classification: A Systematic Review and Meta-analysis. *Obstet Gynecol*. 2022 Jan 1;139(1):138–48.
11. Kim M-A, Kim HS, Kim Y-H. Reproductive, Obstetric and Neonatal Outcomes in Women with Congenital Uterine Anomalies: A Systematic Review and Meta-Analysis. *J Clin Med*. 2021 Oct 20;10(21):4797.
12. Rikken JFW, Kowalik CR, Emanuel MH, Bongers MY, Spinder T, Jansen FW, et al. Septum resection versus expectant management in women with a septate uterus: an international multicentre open-label randomized controlled trial. *Human Reproduction*. 2021 May 1;36(5):1260–7.
13. Krishnan M, Narice BF, Ola B, Metwally M. Does hysteroscopic resection of uterine septum improve reproductive outcomes: a systematic review and meta-analysis. *Archives of gynecology and obstetrics*. 2021;303(5):1131–42.

Cervical Septum's Dilemma

Jose Carugno, Kiara Márquez

University of Miami Miller School of Medicine. Miami. Florida. USA

Hysteroscopy Newsletter Vol 8 Issue 2

INTRODUCTION

The surgical management of uterine malformations is one of the main indications of hysteroscopic surgery. It is difficult to establish the prevalence of this condition due to the different definitions used to describe them and the various methods used for diagnosis. Chang's review of 94 observational studies including a total of 89,861 women reported that the prevalence was 5.5% in the general population, 8.0% in infertile patients, 13.3% in women with history of spontaneous abortions and up to 24.5% in women with abortions and infertility (1).

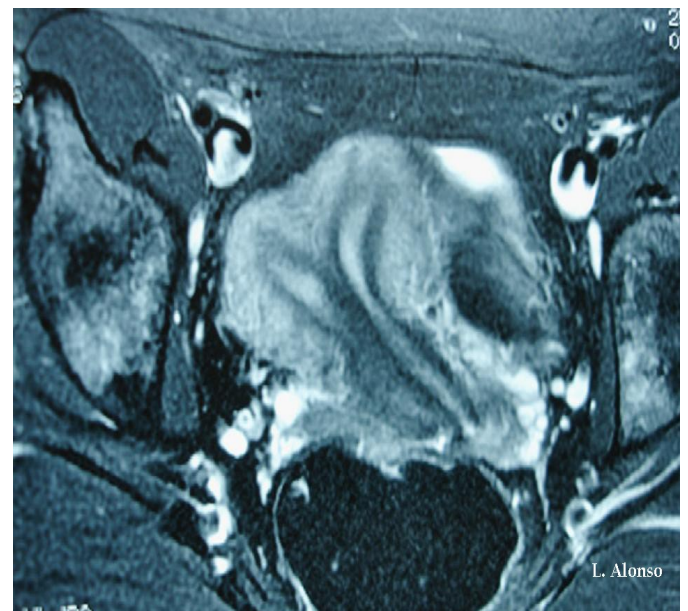
According to the results of the Grimbizis study, the most frequent uterine malformation is septated uterus, which accounts for 34.9% of the total uterine malformations, followed by the bicornuate uterus with 26% and the arcuate uterus with 18.3%. The remaining 20.8% corresponds to all the rest of more uncommon uterine malformations (2).

Similar results were published by Raga (3) who reported that 60% of congenital uterine malformations were septated or arcuate uterus, which represents the most uterine malformation approached by hysteroscopy.

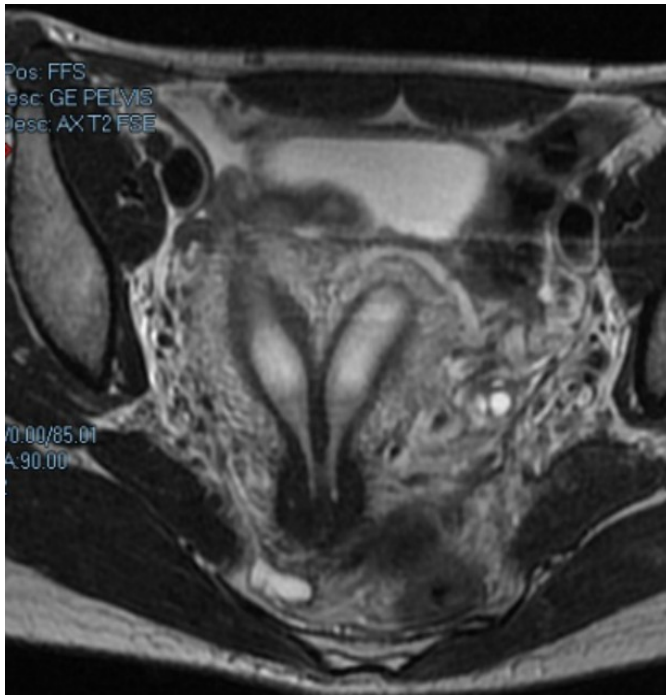
Classically, septated uterus has been divided into complete and partial. The complete septum divides the uterine cavity, reaching up to the internal OS while the partial septum is an "incomplete" division of the uterine cavity. This is classified as class V (complete Va and partial Vb) by the classification of congenital uterine malformations of the AFS.

Occasionally, septated uterus are associated with cervical septum and even a vaginal septum. The first case of septated uterus and vagina was published by McBean (4). Since that publication, there have been less than 300 cases published in the literature.

The presence of double cervix can be associated with different uterine anomalies such as uterus didelphys, bicornuate uterus and septated uterus. The presence of complete septated uterus in cases of double cervix is probably the most frequent association, followed by didelphys uterus, and much less frequent bicornuate uterus. Although a separation of both cervix of more than 1.5 centimeters is more frequent in cases of didelphys uterus, this is not a confirmed rule, and additional diagnostic evaluation must be performed to determine the type of associated malformation (5).



There are several imaging techniques used for the diagnosis of uterine and cervical anomalies, with a different degree of diagnostic accuracy. 2D ultrasound and hysterosalpingography have lower diagnostic accuracy than MRI, which has an accuracy for the diagnosis of Mullerian anomalies between 96-100%. In addition, MRI allows the study of the urinary system, which in



some occasions have also associated malformations. 3D ultrasound has similar diagnostic accuracy than MRI.

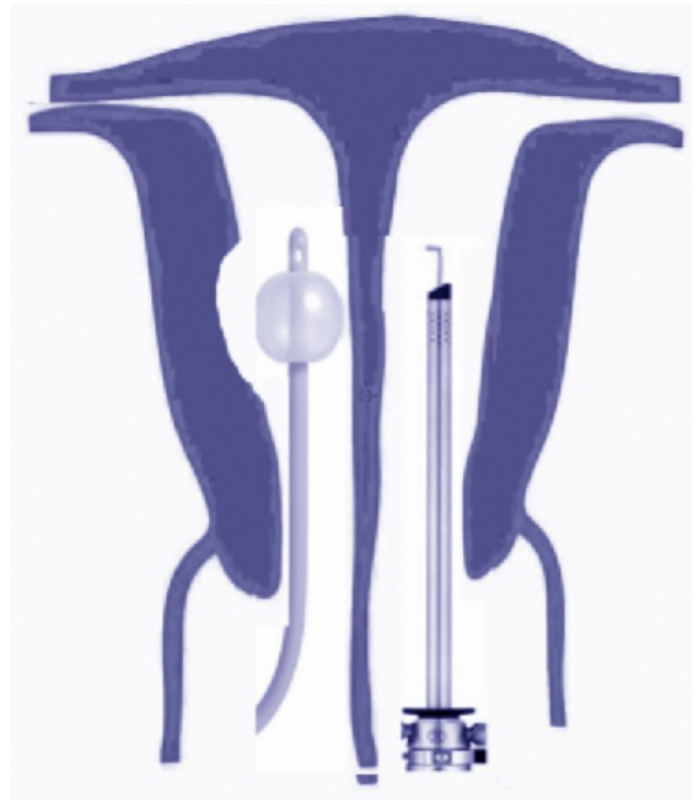
The largest series published of patients with a complete septated uterus, vaginal duplicity and vaginal septum was reported by Heinonen (6). In this work, he described the reproductive outcome and clinical implications of septated uterus. This is a descriptive study of 67 patients in which they observed that this malformation was not related to primary infertility and in terms of obstetric outcomes, the spontaneous abortion rate was 27%, the preterm delivery rate was 12% and the newborn alive rate of 72%. Only 4 of these women underwent metroplasty, 3 by hysteroscopy and 1 patient had Jone's metroplasty.

It is not uncommon to find co-existence of urinary system malformations in these patients. Hainonen reported the presence of renal malformations in 11 patients (20%), being double ureter the most frequent.

The surgical technique with preservation of the cervical septum was described in a series of 21 patients by Rock (7) The description of the technique is as follows: after cervical dilatation, a Foley catheter or a dilator is inserted into one of the cavities that serve as a guide for the section

of the body part of the septum. Subsequently, the resectoscope was inserted with a Collin's loop in the other cavity and the intrauterine septum was incised at the supracervical level.

The arguments favoring to preserve the cervical septum are that it is a vascular structure whose section could result in massive intraoperative bleeding and that the transection of the cervical septum could cause cervical incompetence, which would require performing a cerclage if the patient were to conceive.



The first publication regarding the section of the cervical septum was reported by Vercellini (8). Who performed the section of the cervical septum with Metzenbaun scissors in 7 patients in which they had great difficulty in creating the initial communication between the two endometrial cavities. Later, they compared the results of these patients with another group of 9 patients in whom this intracervical septum was left intact. There were no intraoperative or obstetric complications related to the section of the cervical septum. No cerclage was performed on any of the patients.

There are few randomized studies comparing the outcome of excising the entire septum in patients with cervical duplicity. Parsanezhad (9) compared the results of 28 women with complete uterine septum who had clinical history of poor obstetric outcomes or infertility. The patients were assigned to one of two groups, in one group the intracervical portion of the septum was excised while in the other group the cervical septum was left intact. Both the surgical time and the fluid deficit were greater in the group in which the cervical septum was left intact. In addition, they had two cases of pulmonary edema and 3 cases of massive bleeding in this group. There were no significant differences in obstetric outcomes. 4 of the 15 patients in the group in which the septum was transected had cervical cerclage, whereas it was performed only in 2 of the 13 patients in the group in which the cervical septum was left intact.

In view of these results, the authors recommend transecting the cervical septum in all cases of complete uterine septum, since it makes the procedure safer, faster with similar obstetric outcomes.

Further studies are needed to determine the implications that the transection of the cervical septum may have on patients with this rare uterine congenital malformation.

REFERENCES

- 1- Chan YY, Jayaprakasan K, Zamora J, Thornton JG, Raine- Fenning N, Coomarasamy A. The prevalence of congenital uterine anomalies in unselected and high-risk populations: a systematic review. *Hum Reprod Update*. 2011;17(6):761-71.
- 2- Grimbizis GF, Camus M, Tarlatzis BC, Bontis JN, Devroey P. Clinical implications of uterine malformations and hysteroscopic treatment results. *Hum Reprod Update*. 2001; 7(2):161-74.
- 3- Raga F, Bauset C, Remohi J, Bonilla-Musoles F, Simon C, Pellicer A. Reproductive impact of congenital Müllerian anomalies. *Hum Reprod*. 1997; 12 (10): 2277-81.
- 4- McBean JH, Brumsted JR. Septate uterus with cervical duplication: a rare malformation. *Fertil Steril*. 1994; 62 (2): 415-7.
- 5- Smith, BC , et al. (2014). "Double cervix: clarifying a diagnostic dilemma." *Am J Obstet Gynecol* 211 (1): 26 e21-25.
- 6- Heinonen, P. K. (2006). "Complete septate uterus with longitudinal vaginal septum." *Fertil Steril* 85 (3): 700-705.
- 7- Rock, J.A., et al. (1999). "Hysteroscopic metroplasty of the Class Va uterus with preservation of the cervical septum." *Fertil Steril* 72 (5): 942-945.
- 8- Vercellini, P., et al. (1994). "A modified technique technique for correction of the complete septate uterus." *Acta Obstet Gynecol Scand* 73 (5): 425-428.
- 9- Parsanezhad, M.E., et al. (2006). "Hysteroscopic metroplasty of the complete uterine septum, duplicate cervix, and vaginal septum." *Fertil Steril* 85 (5): 1473-1477.

Robert's Uterus

Laura Nieto Pascual

Hospital Universitario Reina Sofia. Córdoba, Spain

Hysteroscopy Newsletter Vol 8 Issue 2

INTRODUCTION

Robert's uterus is a rare uterine malformation of which there are only a few reported cases. In this type of malformation, it is very important to establish a previous diagnosis as well as an appropriate treatment that allows to reconstruct the morphology and functionality of the uterus.

It was first described by H       Robert under the name "Asymetrical bifiditis with unilateral menstrual retention". It is actually an asymmetric variant of the septated uterus and is characterized by having a complete uterine septum that divides the uterine cavity asymmetrically from the fundus up to the Internal Cervical Os (ICO) resulting in a non-communicating hemi-uterine cavity and another hemiuterine cavity with unicorn uterus appearance, all in a uterus with a normal external morphology.

As a result of the presence of a non-communicating hemi-cavity, hematometra, hematosalpinx and, due to the existence of retrograde menstrual flow, there may also be associated endometriosis peritoneal implants.

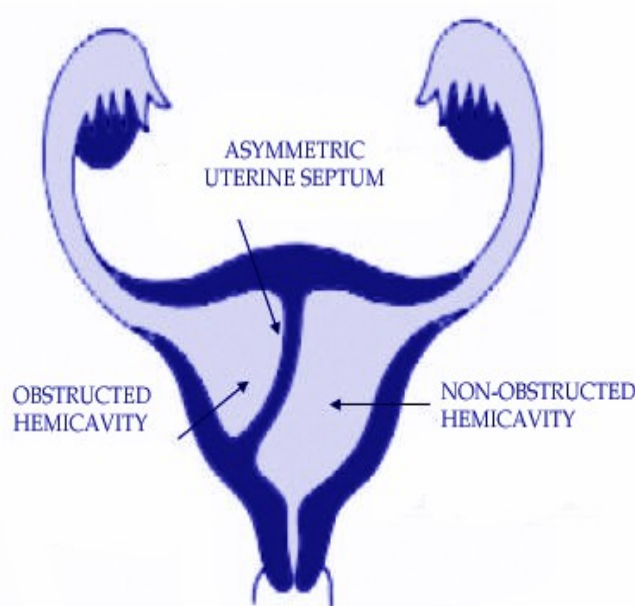
According to the new classification of ESGE-ESHRE, this type of malformation can be defined as U6 or unclassified uterine malformation although some group has defined it as a complete septated uterus (U2b) with unilateral cervical aplasia (C3) and normal vagina (V0)

3 types of Robert's uterus have been described based on the characteristics of the existing hematometra inside the blind hemicavity at the time of diagnosis:

Type I: With gran hematometra

Type II: Without hematometra

Type III: With small hematometra



Usually hematometra and its associated dysmenorrhea are usually of increasing severity over time due to increased tension and size of the blind hemicavity. In cases without hematometra, patients do not usually suffer from severe dysmenorrhea, in these circumstances the most common complaint is recurrent pregnancy loss, since the communicated hemi-uterus behaves like a unicornuate uterus.

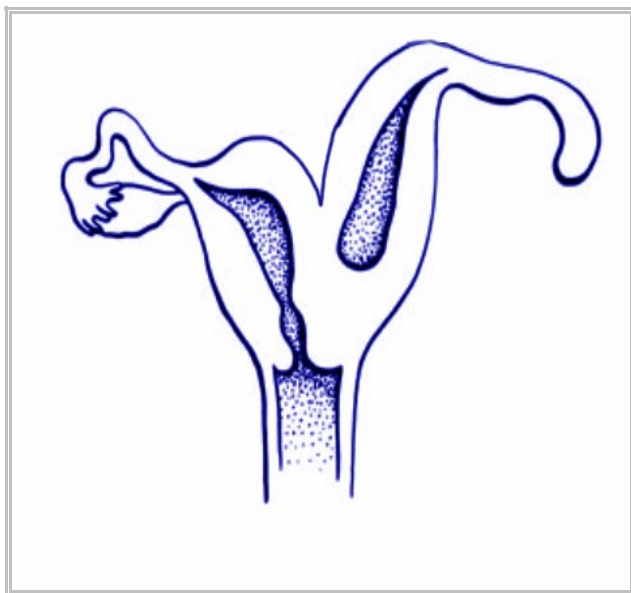
Diagnosing this complex Mullerian malformation is difficult resulting in frequent misdiagnosis, often mistaken for a unicorn uterus with a non-communicating rudimentary cavity.

Within the different imaging tests that can be used to establish the diagnosis, 2D ultrasound has

low sensitivity, usually misdiagnosing it as unicornuate uterus. Using hysterosalpingography it appears as a fusiform image of the unicorn uterus with visualization of a single fallopian tube.

Magnetic Resonance Imaging (MRI) in the coronal view is the best imaging modality to diagnose Robert's uterus, demonstrating the uterine septum, the presence of hematometra in the blind cavity and the existence of a normal uterine contour. 3D ultrasound provides similar results to MRI.

The gold standard for diagnosis is the combination of hysteroscopy and laparoscopy that demonstrate a unicorn uterus in the case of hysteroscopy and the existence of a normal morphology of the uterine contour at laparoscopy.



The way to differentiate while performing a laparoscopy a unicorn uterus from a Robert's uterus is that in Robert's the uterine contour is normal or with a small indentation of 1 cm while the unicornuate uterus has a greater indentation (Larger than 1 cm).

The only treatment available is surgical, having established two surgical options, on the one hand the realization of a hysterotomy of the dilated hemicavity with drainage of the hematometra, thus avoiding the recurrence. The other surgical alternative is metroplasty with communication of the two hemicavities, this communication can be performed by laparoscopic after hysterotomy of the dilated blind hemicavity or by transcervical route, performing a hysteroscopic metroplasty.

Unfortunately, due to miss-diagnosis and confusion with a non-communicating rudimentary horn, often these patients undergo a total resection of the non-communicating hemiuterus, with the functional impact that comes with such a mutilating procedure.

REFERENCES

- Ludwin, A., et al. (2018). "Pre-, intra-, and postoperative management of Robert's uterus." *Fertil Steril* **110**(4): 778-779.
- Shah, N. and P. Chandede (2020). "Hysteroscopic Management of Robert's Uterus." *J Obstet Gynaecol India* **70**(1): 86-88.
- Di Spiezio Sardo, A., et al. (2016). "An Exceptional Case of Complete Septate Uterus With Unilateral Cervical Aplasia (Class U2bC3V0/ESHRE/ESGE Classification) and Isolated Mullerian Remnants: Combined Hysteroscopic and Laparoscopic Treatment." *J Minim Invasive Gynecol* **23**(1): 16-17.
- Ludwin, A., et al. (2016). "Robert's uterus: modern imaging techniques and ultrasound-guided hysteroscopic treatment without laparoscopy or laparotomy." *Ultrasound Obstet Gynecol* **48**(4): 526-529.

Hysteroscopy Newsletter is an opened forum to all professionals who want to contribute with their knowledge and even share their doubts with a word-wide gynecological community



FIND US ON



www.facebook.com/hysteronews



www.twitter.com/hysteronews



[Hysteroscopy newsletter](#)



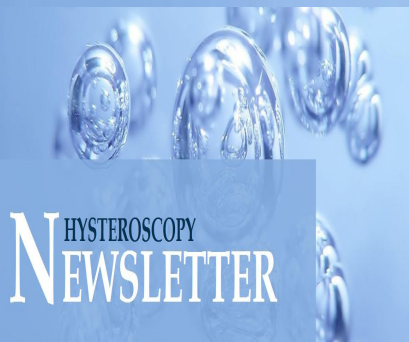[HYSTEROscopy group](#)




[Hysteroscopy newsletter](#)



www.medtube.net










hysteroscopy_newsletter

903 publicaciones 4.092 seguidores 134 seguidos

<http://www.hysteroscopynewsletter.com/>
www.hysteroscopynewsletter.com



PUBLICACIONES

VÍDEOS

GUARDADAS

ETIQUETADAS

