



# the Trocar Official Online Journal of ISGE



**ISGE first female President:**

**Anneli Linnamägi**



**ISSUE 2 Volume 6 (June 2025)**

**Published by ISGE ISSN: 2736-5530**

## The Peer Review Process: Cornerstone of Scientific Integrity or Hindrance to Innovation?

This text does not offer a complete new solution, but would like to remind you that we have to critically back on at any time in order to produce the highest possible objectivity. Especially in times when factual knowledge is partially ignored, we should be able to not nourish high demands on us as a publisher for doubts.

The peer review process is universally regarded as a cornerstone of academic and scientific publishing. It ensures that research is scrutinized, validated, and improved by qualified experts before it is disseminated to the broader scientific community. The system relies heavily on voluntary contributions from scholars who lend their time and expertise without financial compensation. While the system has played a critical role in maintaining the integrity of academic literature, it is increasingly facing scrutiny over issues of bias, inefficiency, and its potential to obstruct innovation—especially in an era where open-access publishing has introduced new financial and structural dynamics.

### The Foundation of Peer Review

At its best, peer review functions as a gatekeeping mechanism that preserves the quality and credibility of scientific output. Ideally, reviewers possess deep knowledge of their field, are experienced in publishing themselves, and are adept at identifying flaws in methodology, interpretation, and statistical analysis. According to the Committee on Publication Ethics (COPE), the process is intended to be objective, constructive, and confidential, and reviewers are expected to disclose conflicts of interest and maintain high ethical standards (COPE, 2017).

A study published in *Nature* (Smith, 2006) affirms that peer review is seen as the “gold standard” in scholarly publishing, but it also acknowledges the limitations and inconsistencies within the system. For instance, research has shown that reviewer recommendations often lack consistency, and papers rejected by one journal are frequently accepted elsewhere with minimal revisions (Rothwell & Martyn, 2000).

### The Question of Objectivity and Bias

The ideal of objectivity is often compromised by implicit biases. Journals typically assign 2 to 3 reviewers to each submission, which in theory should mitigate individual biases. However, this small sample size is hardly sufficient to eliminate systemic biases—such as conservatism in scientific thought or favouritism toward well-known authors or institutions. Innovators presenting new concepts may find their work disproportionately rejected, not due to methodological flaws, but because their ideas challenge entrenched paradigms.

In a well-known case, Nobel laureate Barry Marshall's early research on *Helicobacter pylori* as a cause of stomach ulcers faced rejection from traditional journals, illustrating the reluctance of peer reviewers and editors to accept paradigm-shifting work. Such examples raise the concern that peer review can sometimes act less as a gatekeeper of quality and more as a conservator of orthodoxy.

### The Role of Editors and the Need for Reform?

Editorial boards play a crucial role in managing peer reviews and ensuring that innovative but methodologically sound research is not unfairly excluded. However, the increasing burden placed on volunteer reviewers and editors—particularly in high-impact journals—has led to calls for reform. Some scholars argue for professionalizing aspects of the editorial and review process, especially in light of the high fees associated with open-access publishing.

As noted in a 2021 article in Science, open-access fees can exceed \ \$3,000 per article, raising ethical concerns about who gets to publish and under what circumstances. If journals demand such fees, authors should reasonably expect a professional and unbiased evaluation process in return.

Toward a Professionalized and Transparent System and to address the current challenges, several reform models have been proposed:

1. Reviewer Compensation: As reviewing is unpaid yet time-intensive, some have argued for financial incentives or formal academic credit (Publons and ORCID offer partial solutions by tracking reviewer contributions).
2. Open Peer Review: Transparency in the review process, where reviews and reviewer identities are published, can foster accountability and reduce the potential for biased or unconstructive feedback.
3. Editorial Oversight and Training: Journals could invest in training editors and reviewers to better handle interdisciplinary or unconventional research, ensuring that ideas are evaluated on merit rather than perceived orthodoxy.

### **Conclusion:**

The peer review process remains a vital mechanism for safeguarding the quality of academic publications. However, it is not without flaws. Bias, conservatism, and inefficiencies threaten its objectivity and may hinder scientific innovation. As the publishing landscape evolves—especially under the pressures of open access—it becomes imperative to reconsider how peer review is structured, incentivized, and governed. Professionalizing and reforming the system could help maintain its integrity while fostering a more inclusive and progressive scientific community.

We also work from the review to editing to publication support on a voluntary basis. Still, we enable all members free publication and non-members a low contribution. The Editor Team is working on the review process on monitors to rule out bias as far as possible.

### **References:**

COPE (2017). Ethical Guidelines for Peer Reviewers. Committee on Publication Ethics. Smith, R. (2006). Peer review: a flawed process at the heart of science and journals. *Journal of the Royal Society of Medicine*, 99(4), 178-182.

Rothwell, P. M., & Martyn, C. N. (2000). Reproducibility of peer review in clinical neuroscience: Is agreement between reviewers any greater than would be expected by chance alone? *Brain*, 123(9), 1964–1969.

Science Magazine (2021). The Cost of Open Access: Are Publishers Doing Enough?

Tennant, J. P. et al. (2017). A multi-disciplinary perspective on emergent and future innovations in peer review. F1000Research.

Guenter Noé

Editor in chief



**Introduction: The Peer Review Process: Cornerstone of Scientific Integrity or Hindrance to Innovation?** *Page a -b*  
 By Guenter Noé

**Index Issue 2 Volume 6** *Page i*

**Surgical Approaches in Early-Stage Cervical Cancer: Current Debates, Evidence, and Practical Recommendations** *Page 01 - 08*  
 Loubna Slama

**Saudi Hysteroscopy Guideline** *Page 09 -36*  
 Hesham Ahmed Arab

**Diagnostic Hysteroscopy at the Nabil Choucair Health Center: Indications, Technique, Results** *Page 37 - 47*  
 Omar Gassama

**Microwave Ablation of Diffuse Uterine Adenomyosis: A Novel Minimally Invasive Fertility Preserving Therapeutic Approach** *Page 48 - 55*  
 Sanchari Pal

**Beyond the Pelvis: Multidisciplinary Surgical Management of Extra Pelvic Endometriosis – A Video Case Series report** *Page 56 - 59*  
 Lucia Chaul

**Ureteroneocystostomy in a case of deep infiltrating endometriosis (Case report + Video)** *Page 60 - 62*  
 Hemant Kanojiya, Mukulika Sharma

**A Minimally Invasive Retroperitoneal Approach to Apical Compartment Prolapse Repair via vNOTES Sacral Fixation (Video)** *Page 63 - 64*  
 Rüdiger Klapdor

**Parametrectomy and discoid resection for deep endometriosis of the medial and posterior compartments using the reverse technique (Video)** *Page 65 - 70*  
 Jhanneth Jhovanna Chura Paco

**Spontaneous Rupture of an Unscarred Uterus at 34 Weeks of Pregnancy (Video – case report)** *Page 71 - 73*  
 Meenu Agarwahl

**A Novel Hysteroscopic Approach for FIGO Type 2 Submucosal Leiomyomas (new approach)** *Page 74 - 75*  
 Xiaoming Gong

**DOI List** *Page 76*

**The frontpage shows:** Anneli Linnamägi new ISGE President

# Surgical Approaches in Early-Stage Cervical Cancer: Current Debates, Evidence, and Practical Recommendations

Author: Loubna Slama<sup>1</sup>, Ahmed Mimouni<sup>1</sup>, Zainab Chatbi<sup>1</sup>, Ibtissam Bellejda<sup>1</sup>, Hafsa Taheri<sup>1</sup>, Hanane Saadi<sup>1</sup>

Affiliation: <sup>1</sup> Department of Obstetrics and Gynecology, Mohammed VI University Hospital Center, Faculty of Medicine, University Mohammed First, Oujda, Morocco

## Abstract

The management of early-stage cervical cancer through surgery has been significantly influenced by the LACC trial, which raised concerns about the safety of minimally invasive surgery (MIS) in terms of survival. This review compares outcomes of MIS and open surgery, focusing on tumor size, sentinel lymph node biopsy (SLNB), preoperative conization, and fertility preservation. While the LACC trial highlighted a higher recurrence rate in the MIS group, evidence suggests that MIS may still be effective for smaller tumors (<2 cm) when performed by experienced surgeons. The use of SLNB has gained credibility as a reliable diagnostic tool, and preoperative conization can reduce recurrence risks, particularly for smaller tumors. Fertility-preserving surgeries have shown promising results for young patients with early-stage cervical cancer. The article concludes with a recommendation for individualized surgical strategies, emphasizing open surgery for larger tumors, and MIS for smaller ones, provided the surgeon has the required expertise

**Key words:** cervical cancer; Minimally invasive surgery (MIS); Open radical hysterectomy; LACC trial; Tumor size threshold; Sentinel lymph node biopsy (SLNB); Preoperative conization; Fertility; preservation; Oncological outcome

---

*Corresponding author: Loubna Slama*

*DOI: 10.36205/trocar5.2025005*

*Received: 2025-05-20 – Accepted: 2025-05-29*

---

## Introduction:

### Plain Language Summary:

This article reviews the surgical options for treating early-stage cervical cancer, focusing on two main approaches: minimally invasive surgery (MIS) and open surgery. It highlights findings from the LACC trial, which raised concerns about the safety of MIS, especially for larger tumors. The review suggests that MIS can be effective for smaller tumors, but open surgery may be better for larger ones. The article also discusses the use of sentinel lymph node biopsy and preoperative conization, as well as the importance of fertility preservation for young patients. Personalized surgical strategies are recommended, depending on tumor size and the surgeon's expertise.

### Methods

**Study Design:** This review follows a narrative approach to synthesize current evidence on surgical strategies for early-stage cervical cancer, comparing minimally invasive surgery (MIS) and open surgery. **Literature Search:** Relevant studies were identified through systematic searches in PubMed, Cochrane, and Scopus databases. Keywords included "cervical cancer," "minimally invasive surgery," "LACC trial," "radical hysterectomy," and "fertility preservation."

**Inclusion Criteria:** Studies included were those that compared MIS and open surgery in early-stage cervical cancer, addressing outcomes like recurrence rates, survival, tumor size, and fertility preservation. Only peer-reviewed articles published in English were considered.

**Exclusion Criteria:** Articles focused on advanced cervical cancer or non-surgical interventions were excluded.

**Data Extraction:** Data on oncological outcomes, surgical techniques,

complications, and fertility preservation outcomes were extracted from the selected studies.

**Statistical Analysis:** A qualitative synthesis of the findings was conducted, with no formal statistical meta-analysis due to heterogeneity across studies.

### Results:

#### *Debate: MIS vs. Laparotomy*

Open radical hysterectomy (RH) with pelvic lymphadenectomy has long been considered the gold standard for cervical cancer, delivering high survival rates but with significant short- and long-term complications. Over the years, minimally invasive surgery (MIS), including laparoscopy and robotic surgery, has been adopted in an attempt to reduce complications while maintaining oncological outcomes. MIS was initially endorsed by various international societies, based on evidence of reduced blood loss, quicker recovery, and fewer postoperative complications (4,5). However, the 2018 LACC trial, which included randomized controlled data, revealed a higher recurrence rate in the MIS group compared to laparotomy, shifting the paradigm back toward open surgery for early-stage cervical cancer. Its findings continue to shape clinical practice and fuel debate. The role of robotic-assisted surgery in early-stage cervical cancer continues to expand. Several studies have suggested that robotic platforms may offer improved precision and reduced morbidity compared to conventional laparoscopy. Although long-term oncological equivalence remains under investigation, initial data suggest favorable outcomes in selected patients.



### **The LACC Trial: A Turning Point:**

The LACC trial, a pivotal randomized study published in 2018, evaluated the efficacy of MIS in patients with early-stage cervical cancer. The trial, which enrolled 631 patients, was halted prematurely due to concerns over higher recurrence rates in the MIS group. Key findings included a 10% difference in 4.5-year disease-free survival (DFS) between laparotomy (96.5%) and MIS (86.0%) groups. Despite adjustment for age, tumor size, and lymph vascular invasion, the survival difference remained statistically significant (6). This level I evidence directly challenged the previously held belief that MIS was non-inferior to open surgery, reigniting the debate on the optimal surgical approach.

### **Tumor Size and Its Impact on Survival:**

The size of the cervical tumor plays a significant role in predicting survival outcomes. Several studies have highlighted that smaller tumors (<2 cm) correlate with better survival rates. A Chinese study in 2022 analyzing stage IB1 tumors found no significant difference in the five year survival rate between patients who underwent MIS and open surgery for tumors  $\leq 2$  cm, but those with tumors >2 cm had worse outcomes in the MIS group (7). This suggests that MIS may be more effective in treating smaller tumors, with tumor size serving as an independent predictor of recurrence (8). It should be noted that the Chinese study (Li et al., 2022) was retrospective in design, which introduces potential limitations such as selection bias. Patients undergoing MIS may have had smaller tumors or better baseline characteristics, limiting the generalizability of the survival outcomes.

### **Learning Curve and Its Impact on Survival:**

MIS for cervical cancer requires a steep learning curve. Surgeons need experience to achieve adequate surgical margins and avoid complications. A previous Chinese study found that surgeon experience significantly impacts survival, with more experienced surgeons achieving better outcomes (7). This is consistent with findings from the LACC trial, where surgeons had to have performed at least 10 laparoscopic procedures prior to participation. The learning curve for MIS might explain some of the poor outcomes observed in less experienced hands.

### **Use of Uterine Manipulator in Laparoscopic Cervical Cancer Surgery:**

The use of a uterine manipulator during MIS for cervical cancer has been a topic of debate, with concerns that it may lead to tumor fragmentation and spread. However, recent studies, including a large cohort of 224 patients, found no significant difference in survival between those who used a uterine manipulator and those who did not (9). This suggests that the manipulator does not significantly impact recurrence rates, supporting its continued use in MIS. Recent evidence from the SUCCOR study, a European multicenter observational study, suggests that the use of uterine manipulators is associated with an increased risk of recurrence in MIS for cervical cancer. This study found that patients operated with manipulators had worse disease-free survival compared to those without. Therefore, the choice of manipulator or the decision to avoid its use altogether should be carefully considered in clinical practice. (10).

A 2025 study (Spandidos Publications) showed that laparoscopic surgery without a uterine manipulator and with vaginal cuff closure achieved a 95.7% DFS in 350

patients, suggesting that technical adjustments to MIS protocols can significantly improve outcomes (11).

### **Impact of CO<sub>2</sub> Gas on Survival in Cervical Cancer Surgery:**

During MIS, the use of CO<sub>2</sub> pneumoperitoneum can raise concerns about potential tumor spread due to circulating CO<sub>2</sub>. Studies have indicated that intracorporeal colpotomy during laparoscopy may facilitate tumor dissemination, whilst vaginal colpotomy under CO<sub>2</sub> pneumoperitoneum may reduce this risk. The relationship between surgical technique and tumor spread remains an area for further investigation (12).

### **Biopsy of the Sentinel Lymph Node in Cervical Cancer:**

Lymph node status is a critical prognostic factor in cervical cancer. Sentinel lymph node biopsy (SLNB) offers a less invasive alternative to pelvic lymphadenectomy, reducing complications such as blood loss, lymphocele and nerve injury. Several studies have demonstrated high sensitivity for SLNB, particularly when both technetium and blue dye are used. The AGO study group found an 88.6% detection rate, while the SENTICOL study reported a sensitivity of 92%, supporting SLNB as a reliable technique, particularly in early-stage disease (13,14,15). Various techniques are used for SLNB detection in cervical cancer, including blue dye, technetium-99m (Tc99m), and indocyanine green (ICG). ICG, in particular, has demonstrated superior detection rates and visualization when used with near-infrared imaging systems, and is becoming the preferred method in many centers due to its safety and effectiveness (16).

### **Conization Before Radical Hysterectomy in Early-Stage Cervical Cancer:**

Preoperative cervical conization may improve survival outcomes by reducing tumor size before radical hysterectomy. Several studies have shown that conization before surgery decreases the risk of recurrence, particularly in patients undergoing MIS. A large Korean multicenter study demonstrated significantly improved recurrence-free survival (RFS) in patients who underwent conization, especially those with tumors  $\leq 2$  cm (17). This finding aligns with studies indicating that conization can lead to smaller residual tumor sizes and better outcomes, especially in MIS. It is important to note that prior cervical procedures such as LLETZ or conization do not impair the accuracy or feasibility of sentinel lymph node detection. Studies have shown that SLNB remains reliable even in patients who underwent previous cervical excisions. (18)

### **Fertility Preservation in Early-Stage Cervical Cancer:**

Fertility preservation has become increasingly important in younger patients diagnosed with early-stage cervical cancer. Conservative surgical options, such as cervical conization with lymph node evaluation, offer promising oncological outcomes and improve fertility prospects. A systematic review from 2021 highlighted higher live birth rates and fewer reproductive complications with cervical conization compared to radical procedures like trachelectomy (19). Furthermore, a recent U.S. study showed that less radical fertility-preserving surgeries offer excellent survival outcomes, supporting this approach as a viable option for young women (20).



## **Discussion:**

### ***Key Open Issues:***

#### **1. The LACC Trial:**

While the LACC trial raised concerns about MIS, not all post-LACC studies confirmed inferior oncologic outcomes. A nationwide Danish cohort study found that the introduction of robotic-assisted MIS did not worsen survival or recurrence rates compared to open surgery (21). Similarly, a Memorial Sloan Kettering Cancer Center series reported equivalent survival between MIS and open surgery, with fewer postoperative complications in the MIS group (11.1% vs. 20.3%,  $p=0.04$ ) (22). Additionally, a German multicenter trial ( $n=389$ ) using vaginally-assisted laparoscopic radical hysterectomy showed excellent survival outcomes, with 10-year OS of 95.8%. (23)

#### **2. Tumor Size and Surgery Type:**

One of the critical points that emerges from the literature is the role of tumor size as a determinant of survival outcomes following MIS. While tumors smaller than 2 cm may be safely treated with MIS without compromising survival, tumors greater than 2 cm seem to benefit more from the open surgery approach, where better control over tumor spread is possible. This delineation in surgical approach based on tumor size is still evolving and warrants further investigation in randomized controlled trials (RCTs) to establish clear guidelines.

#### **3. Learning Curve and Surgical Experience:**

Another challenge remains the learning curve associated with MIS, especially when laparoscopic or robotic procedures are involved. As evidenced by the LACC trial and

subsequent studies, the expertise of the surgeon plays a vital role in determining outcomes. A more comprehensive exploration of how surgical experience and institutional volume affect patient survival would provide valuable insights.

#### **4. Preoperative Conization and Fertility Preservation:**

The growing interest in fertility preserving surgery in young women with early-stage cervical cancer presents an important opportunity for further research. The protective role of cervical conization before radical hysterectomy, particularly in patients undergoing MIS, shows promising survival benefits but needs larger-scale studies to confirm these findings across diverse patient populations.

### **Recommendations for Clinicians:**

#### **Tailored Surgical Approach Based on Tumor Size:**

Given the significant differences in survival outcomes based on tumor size, it is recommended that surgeons consider tumor size when deciding between MIS and laparotomy. For patients with tumors  $\leq 2$  cm, MIS remains a safe and effective approach, offering advantages in terms of recovery. However, for patients with tumors  $>2$  cm, open surgery should be considered to minimize recurrence risk and improve survival outcomes.

According to the LAAC trial, a significant proportion of patients with tumors  $>2$  cm required adjuvant therapy postoperatively, highlighting the importance of tumor size not only in surgical planning but also in anticipating the need for postoperative radiation or chemotherapy. Compared to other studies, LAAC showed a higher adjuvant treatment rate in the MIS group, reinforcing the argument for open surgery in

larger tumors. (6) While tumor size remains a key prognostic factor, other histopathological features such as histological subtype, tumor grade, and the presence and severity of lymph vascular space invasion (LVSI) are also critical determinants of recurrence and survival. The SHAPE trial emphasized that these variables should be incorporated into decision-making for surgical radicality and adjuvant treatment.

### **Surgeon Training and Institutional Support:**

To mitigate the risks associated with the learning curve in MIS, it is recommended that surgeons gain experience in a controlled, high-volume setting. Institutions should consider offering specialized training programs to ensure that oncologic surgeons achieve the necessary skill set for complex laparoscopic and robotic procedures. This would enhance the outcomes of MIS in terms of surgical margins and disease control.

### **Preoperative Conization in Early-Stage Cervical Cancer:**

Considering the emerging evidence supporting its role in reducing recurrence and improving survival, preoperative conization should be strongly considered for patients with tumors  $\leq 2$  cm who are undergoing MIS. For patients with tumors  $> 2$  cm, further research is needed to determine whether the same benefits can be realized. Clinicians should also be aware of the role of conization in fertility-preserving surgeries, offering a valuable alternative for younger women who wish to maintain their reproductive potential.

### **Lymph Node Evaluation and Sentinel Lymph Node Biopsy:**

Given the importance of lymph node status in determining prognosis, sentinel lymph node

biopsy (SLNB) should be considered as a viable alternative to full pelvic lymphadenectomy in patients with early-stage cervical cancer, especially in those with tumors  $\leq 2$  cm. SLNB has shown promise in improving lymph node detection rates with lower morbidity. It should be incorporated into standard practice for appropriate patients, with follow-up pelvic lymphadenectomy when SLNB results are inconclusive.

**Future Research Priorities:** To address the current gaps in knowledge, future studies should focus on:

- Conducting multi-center RCTs to establish definitive guidelines on the role of MIS in early-stage cervical cancer based on tumor size and surgeon experience.

- Exploring the role of preoperative conization and its impact on survival outcomes across a larger, more diverse patient cohort.

- Investigating the long-term effects of fertility-preserving surgeries, particularly in relation to oncological control and pregnancy outcomes.

- Further validating the use of SLNB in different tumor stages and assessing its effectiveness in improving both survival outcomes and postoperative recovery.

### **Final Thought:**

The decision between open surgery and MIS for early-stage cervical cancer remains complex, influenced by multiple factors including tumor size, surgeon experience, and the potential for fertility preservation. While MIS offers clear benefits in terms of recovery, open surgery may still be the best option for patients with larger tumors. Ongoing research and technological advances will be key in refining surgical

approaches and improving patient outcomes, ensuring that the optimal treatment path is chosen for each individual.

## Conclusion:

Scope of the Review: This article has reviewed the ongoing debates surrounding the optimal surgical approach for early-stage cervical cancer, with a particular focus on the comparison between minimally invasive surgery (MIS) and laparotomy. As highlighted, several factors such as tumor size, surgeon experience, and preoperative interventions, including conization, have a significant impact on surgical outcomes. The LACC trial has undoubtedly reshaped the landscape of cervical cancer surgery, casting doubt on the superiority of MIS in certain patient populations. However, while MIS continues to be favored for its benefits in reduced blood loss and recovery times, its impact on survival, particularly for larger tumors, remains a point of contention.

## Declarations of interest:

All authors declare no conflicts of interest related to this manuscript

Funding source: This research did not receive any specific grant from funding agencies in the public, commercial, or not-for-profit sectors

## References:

1. Sung H, Ferlay J, Siegel RL, et al.: Global cancer statistics 2020: GLOBOCAN estimates of incidence and mortality worldwide for 36 cancers in 185 countries. *CA Cancer J Clin.* 2021, 71:209-49. 10.3322/caac.21660.
2. Abu-Rustum NR, Yashar CM, Bean S, et al.: NCCN Guidelines® insights: cervical cancer, version 1.2020. *J Natl Compr Canc Netw.* 2020, 18:660-6. 10.6004/jnccn.2020.0027.
3. Lim MC, Lee M, Shim SH, et al.: Practice guidelines for management of cervical cancer in Korea: a Korean Society of Gynecologic Oncology consensus statement. *J Gynecol Oncol.* 2017, 28:e22. 10.3802/jgo.2017.28.e22.
4. Wang YZ, Deng L, Xu HC, et al.: Laparoscopic versus open radical hysterectomy in early-stage cervical cancer: a systematic review and meta-analysis. *J Laparoendosc Adv Surg Tech A.* 2015, 25:990-8. 10.1089/lap.2015.0301.
5. Sert BM, Boggess JF, Ahmad S, et al.: Robot-assisted versus open radical hysterectomy: a multi-institutional comparison of perioperative outcomes and recurrence rates. *Eur J Surg Oncol.* 2016, 42:513-9. 10.1016/j.ejso.2016.01.020.
6. Ramirez PT, Frumovitz M, Pareja R, et al.: Minimally invasive versus abdominal radical hysterectomy for cervical cancer. *N Engl J Med.* 2018, 379:1895-904. 10.1056/NEJMoa1806395
7. Li X, Zhang Y, Zhao L, et al.: Survival outcomes of minimally invasive versus open radical hysterectomy for early-stage cervical cancer: a retrospective cohort study. *Gynecol Oncol.* 2022, 166:75-82. 10.1016/j.ygyno.2022.03.015.
8. Margul DJ, Yang J, Seagle BL, et al.: Cost and outcomes of open, robotic, and laparoscopic radical hysterectomy for stage IB cervical cancer. *J Clin Oncol.* 2018, 36:5504-4. 10.1200/JCO.2018.36.15\_suppl.5504.
9. Nica A, Covens A, Gien LT, et al.: Intrauterine manipulators in minimally invasive surgery for cervical cancer: friend or

foe? *Int J Gynecol Cancer*. 2020, 30:1192-7. 10.1136/ijgc-2020-001345.

10. Chiva L, Zanagnolo V, Carreras J, et al. SUCCOR Study: Effect of Uterine Manipulator on Recurrence in Laparoscopic Surgery. *Int J Gynecol Cancer*. 2021.

11. Hu M, Ji L, Jin L, Shao M. Minimally invasive surgery for cervical cancer. *Oncol Lett*. 2025 Apr 8;29(6):281. doi:10.3892/ol.2025.15027

12. Kong TW, Chang SJ, Piao X, et al.: Patterns of recurrence and survival after abdominal versus laparoscopic radical hysterectomy in patients with early-stage cervical cancer. *J Obstet Gynaecol Res*. 2016, 42:77-86. 10.1111/jog.12853.

13. Poddar P, Maheshwari A.: Controversies and consensus in the surgical management of cervical cancer. *Curr Oncol Rep*. 2021, 23:95. 10.1007/s11912-021-01065-9.

14. Lécure F, Mathevet P, Querleu D, et al.: Validation of the sentinel node concept in cervical cancer: a prospective, multicenter cohort study of 1392 patients. *J Clin Oncol*. 2011, 29:1688-94. 10.1200/JCO.2010.32.0432.

15. Kato T, et al. LAAC trial: Laparoscopic vs. Abdominal Approach and Adjuvant Therapy Rates. *Gynecol Oncol*. 2022.

16. Altgassen C, Hertel H, Akilli H, et al.: Multicenter validation study of the sentinel lymph node concept in cervical cancer: AGO Study Group. *Ann Oncol*. 2008, 19:1588-93. 10.1093/annonc/mdn181.

17. Kim SI, Cho JY, Seol A, et al.: Korean multicenter study of conization before radical hysterectomy (COBRA-R): oncologic and obstetric outcomes. *Gynecol Oncol*. 2023, 170:377-84. 10.1016/j.ygyno.2023.06.012.

18. Plante M, et al. SHAPE trial: Radical versus simple hysterectomy in early-stage cervical cancer. *NEJM*. 2023.

19. Kuznicki ML, Sokol ER, Fader AN, et al.: Fertility-sparing surgery for early-stage cervical cancer: a systematic review and meta-analysis. *Obstet Gynecol*. 2021, 137:1051-63. 10.1097/AOG.0000000000004427.

20. Furey E, Soliman PT, Schmeler KM, et al.: Increasing use of cervical conization with lymph node evaluation for fertility preservation in early-stage cervical cancer. *Am J Obstet Gynecol*. 2023, 229: 383.e1-7. 10.1016/j.ajog.2023.05.013.

21. Jensen PT, Schnack TH, Frøding LP, Bjørn SF, Lajer H, Markauskas A, et al. Survival after a nationwide adoption of robotic minimally invasive surgery for early-stage cervical cancer: A population-based study. *Eur J Cancer*. 2020; 128:47–56. doi: 10.1016/j.ejca.2019.12.020

22. Brandt B, Sioulas V, Basaran D, Kuhn T, LaVigne K, Gardner GJ, Sonoda Y, Chi DS, Long Roche KC, Mueller JJ, Jewell EL, Broach VA, Zivanovic O, Abu-Rustum NR, Leitao MM Jr. Minimally invasive surgery versus laparotomy for radical hysterectomy in the management of early-stage cervical cancer: Survival outcomes. *Gynecol Oncol*. 2020 Mar;156(3):591-597. doi: 10.1016/j.ygyno.2019.12.038. Epub 2020 Jan 7. PMID: 31918996; PMCID: PMC7056548.

23. Köhler C, Hertel H, Herrmann J, Marnitz S, Mallmann P, Favero G, Plaikner A, Martus P, Gajda M, Schneider A. Laparoscopic radical hysterectomy with transvaginal closure of vaginal cuff - a multicenter analysis. *Int J Gynecol Cancer*. 2019 Jun;29(5):845-850. doi: 10.1136/ijgc-2019-000388. PMID: 31155516.

## Saudi Hysteroscopy Guideline

9

**Author:** Hisham Arab<sup>1</sup>, Nadia Kabli<sup>2</sup>, Fatema Alhajeri<sup>3</sup>, Haitham Felimban<sup>4</sup>, Mujahid Bukhari<sup>5</sup>, Assem Kalantan<sup>5</sup>, Mohammad Alyafi<sup>6</sup>

**Affiliation:**

1. Dr Arab Medical Center, Jeddah, Saudi Arabia
2. Dr Samir Abass Hospital, Women Health Center, Jeddah, Saudi Arabia
3. Corniche Hospital, Abu Dhabi, UAE
4. Security Forces Hospital Program (SFHP), Riyadh, Saudi Arabia
5. King Saud University Medical City, Riyadh, Saudi Arabia
6. Faculty of Medicine, King Abdulaziz University, Jeddah, Saudi Arabia.

### Abstract

**Purpose:** To provide Saudi clinicians with guidelines to aide them in the conduct of diagnostic and operative hysteroscopy.

**Methods:** A panel of Saudi experts was put together in 2023 to produce the guideline. The Grading of Recommendations, Assessment, Development and Evaluation was used to approach to summarize the evidence and assess the quality.

**Results:** Findings based on the two uses of hysteroscopy: diagnostic and operative are presented. The goal is to provide clinicians with evidence-based recommendations to apply in different settings.

**Conclusions:** This guideline summarizes the recommendations based on the utilization of the hysteroscope. The recommendations were made by the panel based on a thorough review of the literature and their expert opinion.

**Key words:** hysteroscopy, diagnostic, operative, guideline, recommendation



## **1. Introduction:**

Hysteroscopy is an accurate and minimally invasive procedure used for direct visualization of the uterine cavity, endocervix and vaginal canal. This technique serves both diagnostic and therapeutic purposes in gynecology (1). There have been a number of advances in the technology used to conduct hysteroscopy and the techniques utilized, thus making this procedure less painful and less invasive and allowing medical practitioners to use it in the office setting with minimal patient discomfort and substantial cost reductions (2). The great advantage of utilizing hysteroscopy in gynecology is that it has become a reliable method of diagnosis and treatment due to its accuracy and direct visualization. The only limitation for hysteroscopy is that it requires specific training and directed teaching with a considerable learning curve.

The new golden standard for hysteroscopy appears to be office hysteroscopy; rigorous research has confirmed this method to be safe, cost-effective, easy to apply, and allowing for faster recovery time. Another advantage of office hysteroscopy is that it could be used diagnostically and therapeutically at the same time – “see and treat” option without the need for general anesthesia. Current recommendations call for the utilization of office hysteroscopy as the first-line option for both diagnosis and treatment.

The data on hysteroscopy in Saudi Arabia is limited. A study by Oraif in 2016 assessed patients’ perceptions of and their satisfaction

with diagnostic hysteroscopy with endometrial biopsy conducted in an office setting as compared to a diagnostic hysteroscopy with dilation and curettage performed in the operating room (OR) (3). Women who underwent diagnostic hysteroscopy in the OR setting reported a lower pain score than women who underwent office hysteroscopy, although the mean pain score was quite low on a visual analogue scale (VAS) one to ten, and not different than pain that people experience daily. The office hysteroscopy group reached pre-operative fitness more quickly than the OR group, they did not need to recover from conscious sedation, they were able to return to work and regular activities and to drive much earlier (3). A 2018 prospective study at King Fahd Hospital assessed uterine abnormalities in patients with repeated implantation failure (RIF) using a hysteroscope and reported that hysteroscopy could detect intrauterine pathologies which were missed by other investigative procedures (4). The objective of this guideline is to provide Saudi OBGYN clinicians with the proper recommendations that would aide them in the conduct of diagnostic and operative hysteroscopy while taking into consideration Saudi culture and patient preferences. This guideline has been developed using the Grading of Recommendations, Assessment, Development and Evaluation (GRADE) methodology (5) and relies on evidence from the literature. It has been crafted by a task force of Saudi experts using a multidisciplinary, collaborative approach to offer an updated and validated resource.



## 2. Instrumentation:

A diagnostic or operative hysteroscope differs in the outer diameters (OD) with a range between 2.2 to 10 mm, and its total outer diameter which refers to the sheath and usually ranges between 3.1 to 10 mm. The smaller the diameter of the sheath, the less pain and less need for cervical dilatation and preparation. The working length of a hysteroscope is measured from the eyepiece to the distal tip, and ranges between 160 to 302 mm; the longer the working length the more the person performing the hysteroscopy can reach away from the vagina. Both diagnostic and operative sheaths are fitted with stopcocks or ports for the instillation of distending media. To clear blood and thus improve visualization of the uterine cavity, some operative sheaths have dual ports that provide continuous laminar flow of distending media. In addition, some operative sheaths aspirate pieces of tissue from the uterine cavity. This allows removal of large debris while maintaining cervical dilation. Selected diagnostic hysteroscopes permit targeted biopsies and retrieval of foreign bodies, as well as limited intrauterine surgery. Advanced operative sheaths may have three channels: two for operative instruments such as biopsy instruments, forceps or scissors, and one for instilling distending media (6, 7).

### Cold light source:

A high-quality cold light source, preferably equipped with a Xenon or LED lamp, will

usually yield the best results. A 175-watt light source is considered sufficient for routine procedures. A 300-watt light source is recommended for special applications or those performed with miniature telescopes. A light source operating at higher power levels usually produces more thermal energy, which in turn causes a greater rise in temperature. For standard hysteroscopic procedures, cold light cables with a diameter of 5 mm and a length of 180 cm are used.

### Imaging systems:

The use of an endo-camera is essential in modern hysteroscopy. Different types of video cameras are available, their quality depends on the following technical parameters: resolution, sensitivity (Lux), as well as the quality of the video images. A high signal-to-noise ratio is needed to assure high image quality under extreme situations such as in cases of hemorrhages. Modern High Definition (HD) cameras are recommended to offer a very high resolution and almost natural color reproduction. Video recorders and video printers are recommended, allowing still images, video and audio data to be recorded and archived.

### Hysteroscopes:

Hysteroscopes are available in many forms and their use varies depending on the clinical procedure while taking into consideration patient safety and comfort (Table 1).

**Table 1. Type, description and use of available hysteroscopes**

Type	Description	Use
Rigid hysteroscope	These telescopes are more in use in comparison to flexible telescopes with different viewing angles.	Recommended to use angles 0°, 12°, and 30°. Routinely, the 30° is used for diagnosis, the 12° telescope for surgical procedures involving the use of a resectoscope. The 0° telescope is used in modern shavers and mini resectoscope.
Flexible hysteroscope	This involves the use of a narrow calibre scope (<5 mm) that may also be semi-rigid or flexible. Flexible hysteroscopes provide less intraoperative pain more ease in insertion but poorer image quality in comparison to rigid hysteroscopes.	Useful for diagnostic or operative procedures in women with an irregularly shaped uterus. Currently, the flexible hysteroscope is in limited use.
Diagnostic hysteroscopes	A hysteroscope with a diameter of 2.9mm is most widely used in an office setting, although a smaller diameter of 2-2.2mm has recently become available in the market.	Its use is purely for diagnostic hysteroscopy.
Operative hysteroscopes	These are hysteroscopic systems that allow for diagnostic hysteroscopy while providing the option to perform minor procedures. The telescope is used as in diagnostic hysteroscopy (2.9mm diameter), the sheath has an outer diameter ranging between 3.2 and 5.3mm to permit the passage of surgical instruments.	Surgical use with most operating instruments having a semi-rigid design: scissors, biopsy forceps, and various types of probes, electrodes for unipolar and bipolar coagulation. Minor surgical procedures like small polypectomy or pedunculated uterine leiomyomas.
Resectoscopes	The resectoscope consists of an endoscope with diameters ranging between 2.9 mm and 4 mm – preferably with a 12° viewing angle, combined with a cutting loop, and two sheaths for continuous irrigation and suction of the distension medium. Available instruments cutting loop, as micro-knives, and vaporizing or coagulating electrodes. All these instruments are available for both the 22-Fr and the 26-Fr resectoscope.	Suitable for the resection and removal of abnormal intrauterine tissue (polyp, fibroid, RPOC, isthmocele resection) as well as endometrial ablation and septal dissection.
Mini-resectoscope	Has an outer diameter of 5mm with a 2.9 mm telescope that does not require cervical dilatation to insert it into the uterus.	It is suitable for polyps, septum and isthmocele resection and ablation.
Shavers	It is an open cutting window design tool at the tip. It will usually be assembled as one unit, that contain the irrigation / suction system, that controls the intrauterine pressure and with auto calculation of Fluid Deficit, plus a tissue collecting bag.	Designed to morcellate any intrauterine pathology like fibroids type 0-2, polyps, RPOC and thick endometrium
Ablation devices	First generation under direct visualization of the uterine cavity for endometrial laser ablation (ELA), transcervical resection or ablation of the endometrium using resectoscope loop or rollerball. Second generation is a blind technique of destroying the endometrium, without a direct hysteroscopic visualization using different energy like bipolar –radiofrequency, thermal, microwave and cryotherapy.	Used to destroy the endometrium and is currently used as an alternative technique in cases of heavy menstrual bleeding.
Surgical lasers	Nd-Yag, Argon, CO2, and diode lasers have been promoted to remove a variety of pathologies. It has good characteristics in terms of coagulation. Laser generators are significantly more expensive than electrosurgical equipment.	Diagnosis and treatment of intrauterine pathologies, such as endometrial polyps, submucosal myomas, uterine abnormalities, intrauterine synechiae or isthmoceles.

### Implications for use:

The safety and tolerability of hysteroscopy has rendered it a procedure with a wide range of possible applications, especially that it also allows the collection of tissue samples when needed. There are however some contraindications for hysteroscopy (Table 2).

**Table 2 - Indications and contraindications for Hysteroscopy***Indications for hysteroscopy:*

- Diagnosis of abnormal uterine bleeding in reproductive age women
- Diagnosis of infertility
- Recurrent miscarriage or pregnancy loss
- Post-menopausal bleeding
- Suspicion of endometrial hyperplasia and other endometrial pathologies (endometrial polyps, diagnostic process for endometrial hyperplasia and endometrial cancer)
- Corroboration of histopathology results
- Suspicion of submucosal or intramural fibroids
- Suspicion of congenital uterine anomaly
- Suspicion of intrauterine adhesions
- Corroboration of ultrasound diagnosis of uterine abnormalities
- Repositioning and/or removal of an IUD or other foreign body from the uterine cavity
- Suspicion of retained products of conception
- Suspicion of lesions within the cervical canal
- Endometrial ablation
- Endometrial resection
- Vaginoscopy
- Treatment of symptomatic niche in the cesarean section scar
- Diagnostic and/or operative hysteroscopy, with or without biopsy, before operative procedures in gynecology

*Contraindications for hysteroscopy:*

- Suspected or diagnosed normal viable intrauterine pregnancy
- Active infection of the genital organs, including herpes simplex of the genital area
- Cervical cancer, most endometrial cancers
- Excessive uterine bleeding
- Severe systemic disease

**Distention media:**

Various distention media are utilized to expand the typically collapsed uterine cavity to enable the performance of diagnostic and operative hysteroscopic procedures. In an ideal scenario, the distention medium should provide clear visualization and be rapidly cleared from the body of the patient. It should also be non-toxic, non-hemolytic, isotonic, and less likely to cause allergic

reaction. Distention media could largely be classified into fluid and gaseous categories.

**Gaseous distension media:**

Gaseous distention media is not recommended for use in modern hysteroscopy(8).

### Fluid distension media:

Fluid distension media could be subcategorized based on their viscosity, tonicity, and electrolyte content (8). Normal saline is the safest and most frequently used electrolyte-rich medium in modern-day diagnostic and operative hysteroscopy. The isotonic nature and “physiologic” electrolyte content of this medium would largely eliminate the risk for electrolyte imbalance even if a significant amount of normal saline is absorbed during hysteroscopy. Nonetheless, absorption and/or intraperitoneal spillage of large amounts of electrolyte rich fluid could also lead to complications related to hypervolemia like pulmonary oedema and heart failure (8).

### High viscosity distention media:

High viscosity distention media is not recommended for use in modern hysteroscopy.

### Low viscosity distention media:

Low viscosity distention media could be further categorized into electrolyte-rich and electrolyte-poor media. Normal saline is the safest and most frequently used electrolyte-rich medium in hysteroscopy today. Electrolyte-poor media which include 5% mannitol, 3% sorbitol and 1.5% glycine, allow the use of monopolar electrosurgical hysteroscopes. When absorbed or spilled into the peritoneal cavity however, these could cause a significant drop in serum osmolality and lead to life threatening hyponatremic hypervolemia (9). The development of bipolar electrosurgical hysteroscopes has largely confined the use of such solutions to diagnostic hysteroscopy and to some operative hysteroscopic procedures where bipolar electrosurgical or mechanical tissue removal system is not available (Table 3).

**Table 3. Types of distention media and their use in diagnostic and operative hysteroscopy**

<i>Media*</i>	<i>Hysteroscopic procedure</i>	<i>Electrolyte free</i>	<i>Osmolality</i>	<i>Energy</i>
Normal saline <sup>^</sup>	Diagnostic and operative	No	285mOsm/L Iso-osmolar	Mechanical bipolar laser
Ringer's lactate	Diagnostic and operative	No	Iso-osmolar 279 mOsm/L	
Glycine 1.5%	Operative	Yes	Hypo-osmolar 200 mOsm/L	Monopolar
Dextrose 5%	Operative	Yes	Hypo-osmolar	Monopolar
Sorbitol 3%	Operative	Yes	Hypo-osmolar 165 mOsm/L	Monopolar
Mannitol 5%	Operative	Yes	Iso-osmolar 274 mOsm/L	Monopolar

### **Maintenance of appropriate intrauterine pressure:**

It is essential to establish and maintain a sufficient intrauterine pressure using the distention medium to expand and visualize the usually collapsed endometrial cavity and suppress the occasional endometrial bleeding to ensure a successful hysteroscopic procedure. A starting pressure of 70-80 mmHg is recommended and can later be carefully raised according to the need of the surgeon for a specified period rather than the entire duration of the procedure.

### **Fluid deficit monitoring:**

Accurate and frequent monitoring – every 10 minutes after initiation of the procedure – of the excess fluid absorption is a crucial step to conduct safe hysteroscopic procedures, especially in the more complex and prolonged operative cases, as early recognition of fluid overload enables the team to evade possible complications. This is achieved by the measurement of all the fluid remaining in the used fluid bags and fluid collected from the outflow channel and leaked from the cervix into the bucket, surgical drapes and the floor. The sum is then

subtracted from the total amount of fluid infused into the uterus to get the amount of fluid that leaked into the patient's circulation or peritoneal cavity. It is recommended to use an automated fluid management system which can calculate the exact weight of infused fluids and fluids leaked and come up with an accurate and more precise estimation of the fluid deficit in a continuous fashion.

### **Fluid overload:**

Despite the lack of robust evidence to support the determination of cutoff values to define fluid overload, several entities have defined it as a fluid deficit of more than 1000 ml when a hypotonic distention medium and more than 2500 ml when an isotonic distention medium is used in a healthy young patient (8). A lower threshold should be implemented in older patients and in patients with significant co-morbidities.

### **Complications of hysteroscopy:**

Complications associated with hysteroscopy can be identified early on during the procedure or later after the procedure has been finalized and the patient has been discharged (Table 4).

**Table 4. Complication of hysteroscopy**

<i>Early complications</i>	<i>Late complications</i>
Uterine perforation	Iatrogenic adhesions after hysteroscopy
Heavy bleeding	Pelvic inflammatory disease
Absorption of distending medium; gas embolism; fluid overload	



### 3. Methodology:

#### Committee members:

A committee of seven Saudi experts, mainly gynecologists came together on several occasions to outline this guideline. The group also included patient representatives, and a Saudi Ministry of Health representative. The committee initially determined the questions of interest. The questions were structured using PICO (P: patient, I: Intervention, C: comparison, O: Outcome) methodology. The outcomes of interest for our guideline included diagnostic or operative hysteroscopy techniques, medications, media used, equipment, anesthesia methods, quality of life, any adverse events, and cost.

#### Search strategy:

A thorough search of the literature for the available systematic reviews and meta-analyses in PubMed, Embase, MEDLINE and Cochrane databases was conducted. The search was conducted on June 21, 2024. Keywords used included: hysteroscopy, operative, diagnostic, AUB, sedation, timing, medium, isthmocele, adhesion, fertility, myomectomy, MRI, endometrial sampling, sonogram, implantation failure. The search was limited to articles in English. We also conducted systematic searches for contextual information necessary to develop the full guideline for Saudi Arabia, including searches for information on patients' values and preferences, and costs and resource use specific to the Saudi setting.

#### Evidence to decision:

The GRADE approach for each PICO question was observed, and evidence profiles and tables were developed (5). The information was then shared with the panelists and any additional information or input from panel members was encouraged.

#### Quality of the evidence:

The GRADE working group defines the quality of evidence as the degree of confidence that the estimate of an effect is adequate to support a particular decision, or recommendation (5). The quality of evidence using the GRADE approach was assessed. There are four classifications for the quality of evidence, ranging from high to low. The decision regarding the quality is based on panelists' decisions on methodological aspects of the collected evidence. Evidence that is rated high means that the panelists are very confident that the true effect lies close to that of the estimate of the effect. Moderately rated evidence means panelists are moderately confident in the effect estimate, and that there is a possibility that the true effect and the estimate of the effect are substantially different. Evidence that is rated low means that the confidence in the effect estimate is limited, whereas evidence rated as very low means that there is very little confidence in the effect estimate. In the absence of any conclusive scientific evidence, some practices have nevertheless been recommended based on agreement between all members of the expert panel ("expert opinion").

#### Recommendations:

The evidence was summarized and presented during meetings and online. Discussions regarding the evidence and the recommendations that ensued followed an evidence-to-decision process as detailed in the GRADE methodology, thus allowing proper documentation and deliberation until a consensus was reached. The recommendations were graded and labelled as strong or weak. When the recommendations were strong the committee formulated their recommendations using "we recommend" or "clinicians should" to guide the application of



the recommendation and indicate that it should be used for most patients. When the recommendation was weak, the committee's recommendation used wording to "suggest" and maintain that the recommendation requires further decision-making and discussion.

### **Target audience:**

Our target audience is clinicians, particularly OBGYN clinicians who practice in the Kingdom of Saudi Arabia. Policy makers can also benefit from these recommendations and can refer to them. It is important to remember that when implementing these guidelines, all physicians should utilize their own discretion, considering their individual expertise and the unique characteristics of their practice or institution. This ensures the selection of the most appropriate diagnostic or treatment approach tailored to each particular patient.

## **4. Diagnostic Hysteroscopy**

Diagnostic hysteroscopy, an investigation that is frequently performed in the outpatient setting, is generally safe and brief. Most women can undertake the procedure with or without local anesthesia and find it both convenient and acceptable. Diagnostic hysteroscopy is a valuable tool in obstetrics and gynecology for direct imaging of the contents of the uterus and is commonly used to examine and detect visualization irregularities in the uterine cavity.

### Should office hysteroscopy vs. operative room be used in diagnostic hysteroscopy?

The use of office hysteroscopy has been well established for the diagnostic evaluation of abnormal uterine bleeding (11). The selection of patients for office-based hysteroscopic procedures depends on the physician's understanding of the suspected pathology, lesion size, lesion depth, patients' readiness

to undergo an office-based procedure, physicians' skills and expertise, a thorough assessment of patient comorbidities, and availability of appropriate equipment and patient care. Considerations for performing hysteroscopy in an alternative setting, such as the operating room or ambulatory surgery, ought to be considered for patients who have anxiety or have not tolerated the office-based approach in previous procedures (11). A 20-year-retrospective study, with data from 2675 patients who had vaginoscopic office hysteroscopy, reported hysteroscopy as an efficient and safe mode to investigate pathologies within the uterus and reported an overall patient satisfaction with the process (12). The study compared results from hysteroscopic findings with the respective histology reports to reveal that in cases of normal endometrium, a sensitivity of 60.9%, specificity of 92.1%, Positive Predictive Value (PPV) of 79.07% and Negative Predictive Value (NPV) 82.8% were estimated. A systematic review by Bennett et al in 2019 found no studies that compared the diagnostic accuracy of outpatient hysteroscopy with hysteroscopy performed in the operating room. However, they did conclude that outpatient hysteroscopy is significantly less expensive than operating-room hysteroscopy (13). In general, studies have reported a patient preference for office-based hysteroscopy due to higher patient satisfaction with the procedure and faster recovery. Other possible benefits of office hysteroscopy include patient and physician convenience, avoidance of general anesthesia, less patient anxiety owing to office setting familiarity, cost effectiveness, and more efficient use of the operating room for more complex hysteroscopic cases (14-16).

### Recommendation 1:

The panel recommends the use of outpatient hysteroscopy for diagnostic procedures taking into consideration patient comorbidities, patient acceptability, availability of proper equipment, and physician skills and expertise (strong recommendation, high quality evidence).

#### Should conscious sedation vs. no sedation be used in office diagnostic hysteroscopy?

Pain management during office hysteroscopy could be required, whether the procedure is for diagnostic or operative purposes and due to the utilization of instruments in the genital tract, distention of the uterine cavity and in cases of operative hysteroscopy due to procedural interventions such as biopsy (17, 18). A systematic review and meta-analysis by De Silva et al. in 2021 reported two studies assessing the use of conscious sedation during diagnostic hysteroscopy(19). In both studies intravenous conscious sedation did not show any benefit when compared to other forms of sedation, and in fact, caused increased pain, both during and after hysteroscopy in one of the studies (20, 21). According to the Royal College of Obstetrics and Gynecology, conscious sedation should not be routinely used in outpatient hysteroscopic procedures as it has no advantage in terms of pain control and patient satisfaction as compared to local anesthesia (22). The utilization of conscious sedation could also cause life-threatening complications and thus if it were to be used appropriate monitoring and proper staff skills are mandatory (22).

### Recommendation 2:

The panel recommends the limited use of conscious sedation in outpatient diagnostic hysteroscopy as it has no benefit in terms of pain control and patient's satisfaction (strong

recommendation, moderate quality evidence).

The panel recommends mandatory monitoring and appropriate staff skills if diagnostic hysteroscopy will be conducted under conscious sedation according to the institutional policies and facilities available (strong recommendation, moderate quality evidence).

#### Should a specific timing relative to the menstrual cycle vs. any time impact success of diagnostic hysteroscopy?

Our search of the literature returned no studies evaluating the optimal timing of hysteroscopy. Most guidelines and publications describe the optimal timing for diagnostic hysteroscopy, in premenopausal women with regular menstrual cycles, during the follicular phase of the menstrual cycle after menstruation. Pregnancy should be reasonably excluded before performing hysteroscopy. Hysteroscopy during the secretory phase of the cycle may make diagnosis more difficult because a thickened endometrium may mimic polyps (11, 23, 24). A systematic review in 2007 selected studies that only performed hysteroscopy in the follicular phase of menstruation. Their findings did not show any clinical significance and therefore no evidence-based recommendation on the subject of best timing could be made (25).

### Recommendation 3:

The panel recommends the follicular phase as the optimal timing for diagnostic hysteroscopy, after menstruation, in premenopausal women (strong recommendation, moderate quality evidence).

#### Should initial hysteroscopy vs. ultrasound be used to diagnose etiology of AUB?

Abnormal uterine bleeding (AUB) in women is the single most common reason for gynecological referrals. In more than 40% of the referred patients, polyps and myomas have been reported (26). Pelvic ultrasound has been used to evaluate the uterine cavity for fibroids, endometrial thickness, endometrial homogeneity, and the presence of abnormal vascularity within the endometrium. A systematic review by Van Dongen et al, conducted to assess the accuracy and feasibility of diagnostic hysteroscopy in the evaluation of intrauterine abnormalities in women with AUB, revealed that diagnostic hysteroscopy is both accurate and feasible in the diagnosis of intrauterine abnormalities (25). Another systematic review to determine the accuracy of transvaginal ultrasonography (TVUS), sono hystero-graphy and diagnostic hysteroscopy for the investigation of AUB in premenopausal women, included prospective studies and suggested that TVUS has a higher rate of false negatives for detecting intrauterine pathology compared with diagnostic hysteroscopy. Diagnostic hysteroscopy has excellent diagnostic accuracy for diagnosing submucous fibroids; and performed best when detecting submucous fibroids (27).

#### **Recommendation 4:**

The panel recommends an evaluation plan using transvaginal sonography as the initial screening evaluation, followed by hysteroscopy when needed (strong recommendation, moderate quality evidence).

The panel suggests the use of diagnostic hysteroscopy for the diagnosis of AUB (conditional recommendation, moderate quality evidence).

Should hysteroscopy vs. MRI be used to diagnose etiology of AUB?

Magnetic resonance imaging (MRI), when indicated, is an excellent second-line diagnostic tool for a better non-invasive characterization of the underlying cause of AUB (28). No randomized controlled trials comparing the diagnostic efficacy of hysteroscopy versus MRI for AUB were retrieved. An observational study reported findings from patients who presented with AUB and were referred to the department of radiodiagnosis and underwent USG of the abdomen and pelvis, followed by an MRI of the pelvis. The study analyzed and compared the two methods with the histopathological examination (HPE) of the samples of hysterectomized uterus, polypectomy, myomectomy, and dilation and curettage (D&C) of the endometrium. Among the study population, USG reports showed two patients (4.10%) with polyps, seven patients (14.58%) with adenomyosis, 25 patients (52.08%) with leiomyomas, and 14 patients (29.16%) with malignancies. On MRI examination, three patients (6.25%) were diagnosed with polyps, nine patients (18.7%) with adenomyosis, 22 patients (45.8%) with leiomyomas, and 14 patients (29.16%) were reported to have malignancies. The measure of agreement with the kappa value for MRI and HPE in evaluating the causes of AUB is 1.0 (very good). Whereas the kappa agreement value of USG and HPE in evaluating the causes of abnormal uterine bleeding is 0.903 (acceptable). The sensitivity of USG in diagnosing polyps, adenomyosis, leiomyoma, and malignancy was observed at 66%, 77.78%, 100%, and 100%, respectively. The sensitivity of MRI in diagnosing polyps, adenomyosis, leiomyoma, and malignancy was 100% for each. The study concluded that an MRI is the most effective method for accurate identification of the location, number, and characterization of lesions, extensions, and staging of carcinomas (29).

### Recommendation 5:

The panel suggests the use of MRI for diagnosis of AUB only when further investigations are warranted (conditional recommendation, low quality evidence).

#### Should hysteroscopy vs. SIS be used to diagnose etiology of AUB?

Saline infusion sonogram (SIS) involves the instillation of sterile saline, a negative contrast agent, into the uterus through a hysterosalpingography catheter prior to TVUS. Compared to TVUS, SIS has been reported in premenopausal women to allow easier differentiation of polyps, submucous fibroids, and endometrial lesions that emerge clearly in anechoic saline (30). SIS is accurate in the evaluation of the uterine cavity in pre- and postmenopausal women suffering from AUB. The feasibility of saline contrast hysterosonography is high, although significantly better in premenopausal women compared with postmenopausal women (31).

### Recommendation 6:

The panel suggests the use of SIS as an initial investigation to diagnose the etiology of AUB, before resorting to hysteroscopy when needed (conditional recommendation, moderate quality evidence).

#### Should hysteroscopy vs. endometrial sampling be used to diagnose etiology of AUB?

Among the most frequent indications for endometrial biopsy (EB) in clinical practice include infertility and subfertility, the assessment of the uterine cavity before assisted reproduction technique (ART); and the evaluation of premenopausal and postmenopausal patients with AUB among others (32). A 2015 systematic review, assessing the accuracy of endometrial sampling for the diagnoses of endometrial

cancer, atypical hyperplasia and endometrial disease (endometrial pathology, including benign polyps), searched the literature for studies comparing the results of endometrial sampling in women with postmenopausal bleeding with two different reference standards: blind dilatation and curettage (D&C) and hysteroscopy with histology. A total of 12 studies were detected, reporting on 1029 women with postmenopausal bleeding: five studies with D&C and seven studies with hysteroscopy as a reference test. The weighted sensitivity of endometrial sampling with D&C as a reference for the diagnosis of endometrial cancer was 100% (range 100-100%) and 92% (71-100) for the diagnosis of atypical hyperplasia. Only one study reported sensitivity for endometrial disease, which was 76%. When hysteroscopy was used as a reference, weighted sensitivities of endometrial sampling were 90% (range 50-100), 82% (range 56-94) and 39% (21-69) for the diagnosis of endometrial cancer, atypical hyperplasia and endometrial disease, respectively. For all diagnoses studied and the reference test used, specificity was 98-100%. The weighted failure rate of endometrial sampling was 11% (range 1-53%), while insufficient samples were found in 31% (range 7-76%). In these women with insufficient or failed samples, an endometrial (pre) cancer was found in 7% (range 0-18%). In women with postmenopausal bleeding, the sensitivity of endometrial sampling to detect endometrial cancer, atypical hyperplasia and endometrial disease, including endometrial polyps, is lower than previously thought (33).

### Recommendation 7:

The panel recommends office hysteroscopy for targeted biopsy due to its high diagnostic accuracy and cost-effectiveness (strong recommendation, moderate quality evidence).

The panel recommends EB in postmenopausal women with any kind of AUB or PMB (strong recommendation, high quality evidence).

#### Should hysteroscopy be used in recurrent implantation failure (RIF)?

It has been recently proposed that office hysteroscopy be used for the assessment and possible management of infertility since it is a golden tool for screening intracavity lesions. In 2013, Cenksoy et al. reported that 44.9% of RIF patients had abnormal hysteroscopic findings preceding their IVF cycle, 48.1% became pregnant after hysteroscopy and nearly half of these pregnant women had uterine abnormalities corrected. They found that the implantation rate and CPR were statistically significantly increased after polypectomy and concluded that hysteroscopy has positive prognostic value for patients who experience RIF (34). A meta-analysis by Cao et al reported that hysteroscopy prior to an IVF cycle significantly improves outcomes for patients with RIF, particularly in Asia. These results indicate that visual assessment of uterine morphology by OH with or without corrected abnormalities may be of positive prognostic value for achieving a pregnancy outcome in patients with RIF (35). Another more recent systematic review by Vitale et al in 2023 revealed that the evidence regarding the role of hysteroscopy in boosting fertility in women undergoing ART is evolving through new trials. The evidence shows that diagnostic hysteroscopy substantially improves LBR of patients with at least one failed implantation after embryo transfer. When evaluating CPR instead of LBR, there is moderate- quality evidence showing that performing hysteroscopy before ART improves outcomes, even of women without a history of unsuccessful implantation (36). The role of office hysteroscopy in assisted

reproductive techniques remains controversial, and additional studies are needed to determine if hysteroscopic resection of endometrial polyps has an impact on fertility outcomes.

#### **Recommendation 8:**

The panel suggests the use of office hysteroscopy in recurrent implantation failure to detect uterine abnormalities after preliminary uterine assessment (conditional recommendation, moderate quality evidence)

### **5. Operative Hysteroscopy**

Operative hysteroscopy allows for the ability to treat any observed intrauterine pathology. There is significant overlap in indications for diagnostic and operative procedures and if a procedure is started with diagnostic intent, the “see and treat” approach can be used (37). This approach allows for a seamless transition from diagnostic to operative hysteroscopy if abnormal pathology is noted and if the patient continues to tolerate the procedure. Assuming proper set-up and instrumentation availability, this technique allows for the fewest number of interventions for proper patient care. Gynecologists perform operative hysteroscopy to manage intrauterine conditions like endometrial polyps, uterine fibroids, uterine septa, retained products of conception and adhesions. Other applications include removing foreign objects such as displaced intrauterine devices, performing tubal cannulation, treating isthmocele, and conducting targeted biopsies (11).

#### Should we use normal saline vs glycine in operative hysteroscopy?

Normal saline is often recommended as the distention medium for operative hysteroscopy procedures because it enhances image clarity and reduces the frequency of



vasovagal episodes when compared to carbon dioxide (38). Although the distension of the myometrial wall with saline commonly leads to contractions that patients report as colicky pain of moderate to severe intensity (39). Pain has been reported as the major reason leading to unsuccessful office hysteroscopic interventions (40). Reducing pain and discomfort is therefore a main concern during hysteroscopic procedures.

Our search retrieved no RCTs assessing the use of glycine for operative hysteroscopy. A systematic review and meta-analysis by Baradwan et al, looked at RCTs to assess effectiveness of warmed saline distension medium in the intervention group versus room temperature distension medium in the control group among women undergoing diagnostic and/or operative office hysteroscopy. The review encompassed five RCTs that met the inclusion criteria with a total number of 441 patients. The study found that warm saline was linked to a significant reduction in the VAS pain score during the procedure compared to the control group (mean difference (MD) = -1.12, 95% confidence interval (CI) (-1.80, -0.45),  $p = 0.001$ ). Moreover, the VAS pain score after the procedure was significantly declined among the warm saline group (MD = -0.62, 95% CI (-0.97, -0.27),  $p = 0.005$ ). Interestingly, more patients were significantly satisfied with warm saline distension medium application compared to room temperature group (odds ratio (OR) = 3.71, 95% CI (2.01, 6.86),  $p < 0.001$ ) (41). Another systematic review assessed the impact of distension medium type, pressure, and temperature for both diagnostic and operative office hysteroscopy, primarily on pain, but also on procedural success and duration, image quality, complications, and satisfaction and/or acceptability from both the patient's and operator's perspectives. Normal saline should be the preferred

distension medium for office hysteroscopy. It allows for the efficient practice of “see and treat” services, in which diagnosis can be immediately followed by treatment. It is isotonic, minimizing risks associated with fluid overload, and is able to conduct electricity, essential for the operation of modern, miniature bipolar electrosurgical electrodes and works optimally with modern mechanical tissue removal systems (42).

### **Recommendation 9:**

The panel recommends the use of normal saline distension media for the conduct of office operative hysteroscopy (strong recommendation, moderate quality evidence).

Should office setting vs. operative room (OR) setting be used in operative hysteroscopy?  
Should office vs. operative hysteroscopy be used for polypectomy?

There is a current trend towards shifting the implementation of hysteroscopies from the operating room to the office setting. Office procedures are associated with higher patient satisfaction and faster recovery. Other potential benefits of office hysteroscopy include patient and physician convenience, avoidance of general anesthesia, less patient anxiety related to familiarity with the office setting, cost effectiveness, and more efficient use of the operating room for more complex hysteroscopic cases (11). Hysteroscopic polypectomy is effective and safe as both a diagnostic and therapeutic intervention. There are a variety of methods practiced to remove polyps with hysteroscopy; however, there are no comparative studies for these methods with regards to efficacy or costs, and the method of choice is the one with which the clinician is trained in and most familiar, given that such technology is available. Office hysteroscopic polypectomy has been shown to be safe, well tolerated, and more cost-



effective compared with traditional inpatient hysteroscopic polypectomy. A pragmatic multicenter randomized controlled non-inferiority study to compare the effectiveness and acceptability of outpatient polypectomy with inpatient polypectomy was conducted in 31 UK National Health Service hospitals. Participants were randomly assigned to either outpatient uterine polypectomy under local anaesthetic or inpatient uterine polypectomy under general anesthesia. 73% (166/228) of women in the outpatient group and 80% (168/211) in the inpatient group reported successful treatment at six months (intention to treat relative risk 0.91, 95% confidence interval 0.82-1.02; per protocol relative risk 0.92, 0.82-1.02). Failure to remove polyps was higher (19% v 7%; relative risk 2.5, 1.5 to 4.1) and acceptability of the procedure was lower (83% v 92%; 0.90, 0.84 to 0.97) in the outpatient group. The authors reported that the quality of life did not differ significantly between the groups. Four uterine perforations, one of which necessitated bowel resection, all occurred in the inpatient group. Outpatient polypectomy was non-inferior to inpatient polypectomy. Failure to remove a uterine polyp was, however, more likely with outpatient polypectomy and acceptability of the procedure was slightly lower (43).

### **Recommendation 10:**

The panel suggests the use of outpatient hysteroscopy for operative procedures taking into consideration patient comorbidities, patient support, availability of proper equipment, and physician skills and expertise (conditional recommendation, high quality evidence).

The panel suggests the use of office hysteroscopy for the treatment of endometrial polyps whenever possible with a thorough counselling of patient on risks and

complications (conditional recommendation, moderate quality evidence).

### Should tissue removal system vs resectoscopes be used in polypectomy?

Traditional hysteroscopic resectoscopes utilize the loop electrode to resect polyps, and also electro coagulate the base to stop bleeding. The postoperative recurrence rate is low, so it is widely used in clinical practice. A meta-analysis in 2022 comparing the efficacy of hysteroscopic morcellation to resectoscopy in treatment of patients with endometrial lesions, revealed no statistically significant difference in the surgical success rate between the two groups in the management of endometrial lesions, and there was no statistically significant difference between the two in terms of body fluid deficit either. The study concluded however that hysteroscopic morcellation has better accuracy, effectiveness, and safety. Hysteroscopic morcellation will not cause electrical damage to the patient, no scar formation is caused by heat injury, can better protect the patient's endometrium, can maximize the protection of the remaining normal endometrium and promote its movement, to promote the recovery of the endometrium and uterine cavity shape. This surgical method has fewer postoperative complications and better safety. Compared with traditional electrosurgical resection, hysteroscopic morcellation requires a shorter learning time and it has a shorter learning curve (44). These two treatment modalities have clinical applications, but both have their own shortcomings. While studies have shown the feasibility of this new surgical approach, individual studies lack sufficient capacity to provide accurate estimates due to small sample sizes in terms of surgical success rate, duration of surgery, and patient acceptability. In addition, the effectiveness and safety of the technology also need to be

considered. According to the AAGL guidelines for the management of polyps, there does not appear to be differences in clinical outcomes with different hysteroscopic polypectomy techniques (45).

### **Recommendation 11:**

The panel commends the use of tissue removal system for polypectomy (strong recommendation, moderate quality evidence).

The panel suggests that clinicians carefully assess patient's symptoms and provide thorough counselling to choose the most effective and safe modality for polypectomy (conditional recommendation, moderate quality evidence).

#### Should resectoscope, laser, or tissue collection system be used in retained product of conception (RPOC)?

Benign intrauterine lesions include mainly endometrial polyps, retained products of conception (RPOC), and submucous leiomyoma, which are commonly seen in women of reproductive age. RPOC refers to placental or fetal tissue that can occur with induced abortion during early-term pregnancy, induction of labor during mid-term pregnancy, drug-induced abortion, miscarriage, Cesarean delivery, or full-term normal delivery. Patients often manifest with abnormal uterine bleeding after delivery, which predisposes them to infection and can even affect their fertility (46). To be more specific, the discussion of hysteroscopy resection of RPOC herein is meant for any RPOC in situ for 4-6 weeks. For almost a century, dilatation and blind removal through sharp, blunt, or suction has been used to surgically treat RPOC. However, blind techniques are associated with complications such as heavy bleeding, infections, and uterine perforation. Moreover, persistent RPOC can occur after a

blind D&C. In addition, a common adverse outcome associated with D&C is intrauterine adhesion (IUA) formation.

Goldenberg in 1995 was the first to report the use of hysteroscopy for RPOC, facilitating directed identification and treatment. Over the last 10 years, several studies have been conducted to evaluate the efficacy of hysteroscopy for the treatment of RPOC (47). Lasers represent an alternative energy source to electrosurgery that is gaining interest in gynecologic surgery (48). Several types of lasers have been used in the gynecologic field: the Nd- Yag laser, Argon laser, CO<sub>2</sub> laser, and the recent diode laser. Unfortunately, our search returned no literature assessing the use of lasers for RPOCs.

A systematic review by Vitale et al in 2021 to analyze the effect of hysteroscopic management of RPOC and analyze its effect on surgical and reproductive outcomes reported that the hysteroscopic approach to the patient diagnosed with RPOC is effective and safe, completely resecting the pathologic condition in a single procedure in 91% of the cases, and having low rates of complications, infection, and IUA formation. Moreover, women who tried to conceive after the procedure had a high rate of fertility and live births, with a low rate of subsequent pregnancy loss (49). A study comparing the clinical efficacy of hysteroscopic tissue removal system (TRS) and hysteroscopic electro resection in the treatment of benign intrauterine lesions, concluded that TRS has advantages of a shortened operative time and improvement in reproductive outcomes such as pregnancy rate (46). To date, there is no agreed-upon standard approach to RPOC. Blind D&C is still the most widely used first-line method of managing ultrasound-diagnosed RPOC, but not without risks. The hysteroscopic technique, with targeted

removal of the pathologic condition, minimizes trauma to the healthy endometrium, with both short- and long-term potential benefits. The safety and feasibility of hysteroscopic resection, relative to blind D&C, are increasingly accepted for most forms of intrauterine pathologic conditions. Vitale et al found RPOC leading to IUA formation after hysteroscopic management in only 9 cases out of 1323 procedures (0.07%). These findings suggest the rarity of creating adhesions after hysteroscopic cold loop resection or mechanical removal of RPOC. In fact, the method of pathologic condition removal may influence the risk of de novo adhesions (49).

### **Recommendation 12:**

The panel recommends the use of operative hysteroscopy for the management of RPOC at least 4-6 weeks from miscarriage (strong recommendation, moderate quality evidence). The panel suggests the use of TRS for the management of RPOCs but only after a thorough evaluation of the patient before the procedure (conditional recommendation, moderate quality evidence).

#### Should a resectoscope be used in treatment of uterine septum in recurrent foetal loss?

Septate uterus is a congenital malformation characterized by the failure of resorption of the tissue connecting the two paramesonephric ducts before the 20th embryonic week. Although uterine anomalies were described back in the 1800s by Cruveilhier and Von Rokitansky, there is still no consensus between different societies for the definition of septate uterus (50). Septate uterus is associated with adverse fertility outcomes, a lower natural conception, higher first-trimester miscarriage rate, adverse pregnancy outcomes (preterm delivery < 37 weeks), intrauterine growth restriction, and adverse obstetrical outcomes

(malpresentation at delivery and perinatal mortality) compared to a control group (50). According to a meta-analysis conducted in 2024, comparing every method used for hysteroscopic septoplasty in a network meta-analysis, the use of scissors with this technique has significantly higher clinical pregnancy rate in comparison to resectoscope. As far as miscarriage rate and live birth rate are concerned, no significant differences have been found between the different techniques. Although the risk of adhesion formation after hysteroscopic septoplasty is believed to be low, diverse treatment options such as antibiotics, estrogen, intrauterine balloon or device for the postoperative period have been proposed. According to the ASRM guideline for the treatment of septate uterus, it is recommended to counsel patients with infertility and/or undergoing fertility treatment that resection of septum may or may not be associated with an increase in live births. Given limitations in the literature and the low risk of the procedure, septum incision may be offered to patients in a shared decision-making model.

### **Recommendation 13:**

The panel suggests septum incision using hysteroscopy in patients with a septum and a history of recurrent miscarriage with proper patient counselling (conditional recommendation, moderate quality evidence).

#### Should resectoscope, shaver or laser be used in myomectomy?

Hysteroscopic myomectomy is widely used for the treatment of abnormal uterine bleeding in the setting of submucosal uterine leiomyoma (51). Uterine leiomyomas are benign monoclonal smooth muscle cell tumors of the myometrium and represent the most common pathology of the female

genital tract. Although most myomas are asymptomatic, some, depending on their location, size, and number, can be responsible for pelvic pain, abnormal uterine bleeding, and states of subfertility and infertility (Table 5) (48). Hysteroscopic myomectomy is considered the first-line treatment option in the surgical management of submucosal fibroids, and double-flow bipolar resectoscope remains the gold-standard surgical device to approach submucous myomas (11, 52). The reported complication rate for hysteroscopic myomectomy ranges between 1% and 12%, with rates of 1–5% reported in most studies. The success of hysteroscopic myomectomy is dependent on the type of submucosal leiomyoma and one of the main disadvantages associated with resectoscopic myomectomy is the removal of healthy endometrium and myometrium with extensive thermal damage caused by electrosurgical instruments (11). Etrusco et al in 2023 conducted a systematic review to evaluate the use of diode laser for “see-and-treat” hysteroscopy in the management of intrauterine pathology. Eight studies were included in the qualitative analysis for a total of 474 patients undergoing laser hysteroscopic surgery. Except for leiomyomas, which were already planned for a two-phase intervention, only seven patients

required a second surgical step. Cumulative rates of intraoperative and postoperative complications of 2.7% and 0.6%, respectively, were reported (48). The use of hysteroscopic TRS or intrauterine shavers has the benefit of avoiding approaches based on energy thanks to mechanical morcellation and instant aspiration of the tissue. Most studies have reported the benefits of hysteroscopic tissue removal systems such as shorter operative time, higher total resection rate, and higher patient acceptability (53, 54). In a retrospective comparative study, Bigatti et al in 2014 reported no significant difference in terms of duration of resection between the Integrated Bigatti Shaver (IBS) (Karl Storz SE & Co KG Tuttlingen Germany) versus conventional bipolar resectoscope. The IBS was able to approach all kind of submucosal myomas in a single-step procedure and in a very precise and easy way (55). It appears that diode laser through “see-and-treat” hysteroscopy and shavers are safe and effective during a myomectomy. However, more studies with larger sample size are needed. The gold standard remains double-flow bipolar resectoscope to remove submucous myomas. The best treatment choice depends on the patient’s personal objectives and the efficacy of each therapeutic option.

**Table 5. Myoma classification\* in terms of penetration, size, base and extension into the myometrium**

	Penetration	Size	Base	Third	Lateral wall (+1)
0 points	0-4	Less than or equal to 2cm	Less than or equal to 1/3	Lower	
1 point	5-6	Greater than 2 to 5 cm	Greater than 1/3 to 2/3	Middle	
2 points	7-9	Greater than 5cm	More than 2/3	Upper	
Points	+	+	+	+	=

\*The classification for myomas is based on the degree of penetration of the myoma into the myometrium, the distance of the base of the myoma from the uterine wall, the size of the nodule in cm, and the topography of the uterine cavity (56).

#### **Recommendation 14:**

The panel recommends the use of resectoscopes, lasers or shavers to remove submucous myomas (strong recommendation, high quality evidence).

The panel recommends thorough evaluation of the state of the myoma and proper allocation before selecting the type of surgery (strong recommendation, high quality evidence).

The panel recommends using resectoscopes, shavers or lasers for group I myomas - refer to Table 5 (strong recommendation, high quality evidence).

The panel recommends using two-step hysteroscopy in group II myomas - refer to Table 5 (strong recommendation, high quality evidence).

The panel recommends not using hysteroscopy for group III myomas - refer to Table 5 (strong recommendation, high quality evidence).

Should post-op treatment with IUCD, antiadhesion, balloon catheter be used in prevention and management of Asherman syndrome?

Intrauterine adhesions (IUA) are conditions where intracavitary granulation tissue is formed because of injury to the basalis layer of the endometrium, creating fibrous tissue bridges inside the uterine cavity. In the most severe cases, the uterine cavity may be completely obliterated, without any evidence of a healthy endometrium. Hysteroscopy offers direct visualization of the uterine cavity and allows the lysis of adhesions through mechanical or electrosurgical energy.

#### **Primary prevention of intrauterine adhesions:**

Primary prevention should be considered in the routine clinical practice if intrauterine surgery has been performed 1. minimizing the damage to the normal tissue by optimizing visibility, precisely cutting and minimizing of the operation time, 2. reducing



the thermal effect by electrosurgery and 3. the application of biomaterial and/or barrier agents after procedure, based on uncertainty of ideal treatment for the established IUA and unpredictable outcomes after IUA treatment. Preoperative preparation by medication, namely (gonadotropin-releasing hormone agonist (GnRH agonist), selective progesterone receptor modulator (SPRM), and others are often used before hysteroscopic tissue removal, including hysteroscopic myomectomy. However, Taskin and colleagues found that pretreatment-induced hypoestrogenism did not affect the frequency and severity of IUA formation (57). Strategies of primary prevention of intrauterine adhesions contain at least three parts. The first step for reducing the risk of IUA formation is a delicate surgical technique and the application of minimally traumatic instruments. The second step is careful choice of an energy system for hysteroscopic resection procedure, because it is associated with the development of IUA. As for the third recommended step, it involves the application of barrier methods for primary prevention of IUA. Barrier methods including physical barriers, mechanical barriers, or combination of both.

### **Recommendations for Primary Prevention of Intrauterine Adhesions:**

The panel suggests that the use of primary prevention, IUA depending on the procedure being conducted (conditional recommendation, moderate quality evidence).

### **Management of Intrauterine Adhesions:**

Hysteroscopic lysis of adhesions is considered the gold standard in management of IUAs. It enables accurate diagnosis and classification as well as instant dissection. Techniques of blunt and sharp dissection

under direct visualization for release and excision of adhesions may be performed using cold scissors, electrosurgical instruments or Nd-YAG laser. The more lateral the adhesions and the greater their density, the more difficult the dissection and the greater the risk of complications such as uterine perforation and bleeding.

### **Recommendations for management of IUAs:**

The panel recommends the use of hysteroscopic lysis of adhesions by direct visualization and a tool for adhesiolysis for symptomatic IUAs for experienced hysteroscopists (strong recommendation, high quality evidence).

### **Secondary Prevention of Intrauterine Adhesions:**

A challenging issue that arises when treating patients with moderate or severe IUA is the recurrence of the adhesions, which is typically estimated as occurring in 3%–25% of cases but has been reported in up to 60%. A systematic review and network meta-analysis of randomized controlled trials of intrauterine interventions options for preventing recurrence after hysteroscopic adhesiolysis was conducted by Ruonan Tang et al 2024. Data from 21 randomized controlled trials involving 2406 patients were synthesized, including interventions with balloon, amnion, platelet-rich plasma (PRP), intrauterine device (IUD), hyaluronic acid (HA), platelet-rich fibrin (PRF), and granulocyte colony-stimulating factor (G-CSF). The top 5 interventions for change in AFS scores were: PRP + Balloon (MD = 5.44; 95% CI, 2.63-8.25), Amnion + Balloon (MD = 5.08; 95% CI, 2.71-7.44), IUD + Balloon (MD = 4.89; 95% CI, 2.49-7.30), HA + Balloon (MD = 3.80; 95% CI, 1.78-5.82), and G-CSF + Balloon (MD = 3.84; 95% CI, 1.05-6.63). There were no statistically significant



differences between interventions in the recurrence rate of moderate-to-severe uterine adhesions and the clinical pregnancy rate (58).

### **Recommendations for secondary prevention of IUAs:**

The panel suggests the use of an IUD, stent or catheter to reduce the rate of postoperative adhesion reformation (conditional recommendation, moderate quality evidence).

The panel suggests the use of postoperative hormone treatment using estrogen, with or without progestin following hysteroscopic-directed adhesiolysis (conditional recommendation, moderate quality evidence).

The panel recommends follow-up assessment of the uterine cavity after treatment of IUAs, preferably with hysteroscopy after two to three menstrual cycles following surgery (strong recommendation, high quality evidence).

#### Could a resectoscope vs no resectoscope be used in treatment of isthmocele or niche?

A Cesarean scar defect (CSD) or niche was first described by Poidevin using hysterosalpingography (HSG) in 1961 as a typical small wedge-shaped morphological defect (59). Since then, different studies have described the characteristics of a niche using various imaging techniques, including transabdominal and transvaginal sonography (TVS). In 2019, the European Niche Taskforce published a consensus definition of the niche in Jordans et al. as; “an indentation of the uterine myometrium at the site of the SC scar with a depth of at least 3 mm” and classified the niche into: simple, simple with a branch and complex (59). A multicenter RCT assessed the effectiveness of a hysteroscopic niche resection versus no

treatment in women with postmenstrual spotting and a uterine Cesarean scar defect. A total of eleven hospitals collaborating in a consortium for women's health research in the Netherlands. 103 women reporting postmenstrual spotting after a Cesarean section who had a niche with a residual myometrium of  $\geq 3$  mm, were randomly allocated to hysteroscopic niche resection or expectant management for six months. At follow-up, the median number of days of postmenstrual spotting was four days (interquartile range, IQR 2-7 days) in the intervention group and seven days (IQR 3-10 days) in the control group ( $P = 0.04$ ) compared to eight days at baseline in both groups. Patients in the intervention group also reported a significant decrease in spotting related discomfort (60).

### **Recommendation 15:**

The panel recommends hysteroscopic niche resection for women with a cesarean scar defect (CSD) with a residual myometrium of  $\geq 3$  mm and related symptoms (strong recommendation, moderate quality evidence).

#### Should resectoscope, laser, or tissue collection system be used in Cesarean scar pregnancy (CSP)?

CSP is an early and abnormal implantation of pregnancy on Cesarean section scar. The incidence of CSP has been increased worldwide due to the high rates of Cesarean sections. Without a proper management plan for CSP, risk of maternal morbidity and mortality are high from severe intraabdominal bleeding, uterine rupture, morbidly adherent placenta (MAP), hysterectomy and even death (61). The optimal diagnostic method for CSP is pelvic ultrasound (62), however, in some clinical situations magnetic resonance imaging (MRI) of the pelvis is mandatory for clinical

acuity. A new classification of CSP has been published by Jordans et al (Table 6) (63). Vial et al, reported the two types of CSP as exogenic and endogenic based on pelvic ultrasound result (6). While, Ban et al, reported CSP classification into three types (I, II a, III) and depending on some variable items, i.e. anterior myometrial thickness (AMT), gestational sac diameter, to achieve a good clinical outcome. A systematic review assessing hysteroscopic treatment of CSP included four cohort studies where hysteroscopy was used among five groups totaling 329 patients. The studies used

uterine curettage under hysteroscopic guidance in three treatment groups and operative hysteroscopy via resection in the other two. The efficacy of the treatment ranged among studies from 64.9% to 96.1%. The complication rates were low, with hemorrhage or excessive vaginal bleeding postoperatively reported in five out of 301 cases (1.66%) and hysterectomy in just one patient (0.33%). The review also reported an acceptable mean operative time, intraoperative blood loss and days of hospital stay (64).

**Table 6. Classification of CSP by type and recommended surgical intervention**

Classification	Residual myometrial thickness (mm)	Size of gestational sac (mm)	Recommended surgical intervention
Type 1	More than 3 mm	Regardless of the size in mm	Suction and curettage under ultrasound guidance
Type 2	Between 1-3 mm	2A: 30 mm or less	Hysteroscopic approach
		2B: more than 30 mm	Hysteroscopy & Laparoscopy
Type 3	1 mm or less	3A: 50 mm or less	Laparoscopic approach
		3B: more than 50 mm	Laparotomy approach

### **Recommendation 16:**

The panel suggests the use of hysteroscopy in type I and type IIa CSP (conditional recommendation, low quality evidence). Refer to table on Delphi.

#### What is the role of hysteroscopy in uterine-sparing treatments for AUB -Adenomyosis?

Adenomyosis is a common chronic disease in women of reproductive age, characterized by the presence of ectopic endometrial tissue within the myometrium. The development of

ultrasonography and magnetic resonance imaging has improved the pre-operative diagnosis of adenomyosis. Hysteroscopy has been shown to be effective in identifying superficial adenomyosis. However, its role in the surgical management of adenomyosis requires further confirmation through additional studies (65). The management of adenomyosis has evolved with the introduction of hysteroscopy, offering a less invasive alternative to traditional surgical interventions. Endometrial ablation has been explored as a treatment option for

adenomyosis in several studies, however the literature is lacking. In cases where the diagnosis of adenomyosis is uncertain, hysteroscopy may serve as a helpful adjunct tool. Changes in the endometrium, such as hypervascularization, can be visualized during hysteroscopy, aiding in the diagnosis of adenomyosis. Treatment with endometrial ablation is limited, although it might assist in reducing excessive bleeding (65).

### **Recommendation 17:**

The panel suggests the use of endometrial ablation for the treatment of adenomyosis (conditional recommendation, low quality evidence).

### **Discussion:**

Hysteroscopy is the new gold standard in the future because of its ability to visualize directly the endometrium and perform directed biopsies as indicated. As office-based hysteroscopy becomes more practical and widespread, the technique may become more cost effective. An evaluation plan using transvaginal sonography as the initial screening evaluation followed by endometrial biopsy or, more likely, hysteroscopy is likely to become the standard of care (66). Hysteroscopy as a diagnostic tool permits direct visualization of the cervical canal and uterine cavity, enabling observation of intrauterine abnormalities. An accurate diagnosis may result in surgical or medical treatment directed at the specific pathology and may avoid the need for major surgery. Since Gimpelson and Rappold reported that hysteroscopy combined with guided biopsy was more accurate than dilatation and curettage (67), hysteroscopy is considered an accurate 'gold standard' in uterine cavity evaluation. Despite the lack of adequate information about the diagnostic accuracy, it is used in many studies with and without endometrial sampling as a reference

standard (25, 68-70). The recommendations in this guideline, supported by current literature, emphasize the importance of patient-centered care, technological advancements, and evidence-based practices. With proper training and adherence to established protocols, hysteroscopy remains a cornerstone in the diagnostic and therapeutic armamentarium of gynecology.

### **Conclusion:**

The recommendations made in this guideline should not be viewed as dictates and it should be clear that even the strongest of recommendations may not apply across all patients and conditions. Overall, this evidence-based guideline was set forth by a group of experts in the field with specialties of relevance to hysteroscopy. These recommendations were drafted with the highest medical standards in mind and supported by the Saudi Ministry of Health. Our review of the literature provided us with some answers to our PICO questions and we have summarized our findings and expert opinions in the recommendations included here- in. The literature however is insufficient in some cases and making an informed decision based on the available data was challenging. The literature is also lacking in the region and in Saudi Arabia in particular, with regards to use of hysteroscopic procedures for diagnostic and operative purposes and patient satisfaction.

### **References:**

1. de Wit A. Hysteroscopy: An evolving case of minimally invasive therapy in gynaecology. *Health Policy* 1993; 23(1): p. 113-124.
2. D'Urso V, GF, Incognito GG, Cimino M, Dilisi V, Di Stefano A, Gulisano M, Cannone F, Capriglione S, Palumbo M. Hysteroscopic

Findings and Operative Treatment: All at Once? *J Clin Med* 2023; 12(13).

3. Oraif A. Diagnostic hysteroscopy in a procedure room setting compared to diagnostic hysteroscopy in the operating room. *Int J Reprod Contracept Obstet Gynecol* 2016; 5(12): 4164-4173.

4. Al-Turki HA. Hysteroscopy as an investigation tool in recurrent implantation failure in vitro fertilization. *Saudi Med J* 2018; 39(3): 243-246.

5. Guyatt G, Oxman AD, Akl EA, Kunz R, Vist G, Brozek J, Norris S, Falck-Ytter Y, Glasziou P, DeBeer H, Jaeschke R, Rind D, Meerpohl J, Dahm P, Schünemann HJ. GRADE guidelines: 1. Introduction-GRADE evidence profiles and summary of findings tables. *J Clin Epidemiol* 2011; 64(4): 383-94.

6. Cicinelli E, Parisi C, Galantino P, Pinto V, Barba B, Schonauer S. Reliability, feasibility, and safety of minihysteroscopy with a vaginoscopic approach: experience with 6,000 cases. *Fertil Steril* 2003; 80(1): 199-202.

7. De Angelis C, Perrone G, Santoro G, Nofroni I, Zichella L. Suppression of pelvic pain during hysteroscopy with a transcutaneous electrical nerve stimulation device. *Fertil Steril* 2003; 79(6): 1422-7.

8. AAGL Practice Report: Practice Guidelines for the Management of Hysteroscopic distending Media Replaces Hysteroscopic Fluid Monitoring Guidelines. *JMIG* 2000; 7:167-168. *JMIG* 2013;20(2):137-148.

9. Kaijser J, Roelofs H, Breimer L, Kooi S. Excessive Fluid Overload with Severe Hyponatremia, Cardiac Failure, and Cerebral Edema Complicating Hysteroscopic Myomectomy: A Case Report and Review of the Literature. *Urogynecology* 2007; 13(6).

10. Umranikar S, Clark TJ, Saridogan E, Miligkos D, Arambage K, Torbe E, Campo R, Di Spiezio Sardo A, Tanos V, Grimbizis G; British Society for Gynaecological Endoscopy /European Society for Gynaecological Endoscopy Guideline Development Group for Management of Fluid Distension Media in Operative Hysteroscopy. BSGE/ESGE guideline on management of fluid distension media in operative hysteroscopy. *Gynecol Surg* 2016; 13(4): 289-303.

11. The Use of Hysteroscopy for the Diagnosis and Treatment of Intrauterine Pathology: ACOG Committee Opinion Summary, Number 800. *Obstet Gynecol* 2020; 135(3):754-756.

12. Tsonis O, Gkrozou F, Iram N, Ntritsos G, Dimitriou E, Tzallas A, Daniilidis A, Papoudou-Bai A, Siafaka V, Vrekoussis T, Navrozoglou I, Paschopoulos M. 20 Years of Experience in Office Hysteroscopy: The Largest Retrospective Study in Greece to Date. *CEOG* 2023; 50(6).

13. Bennett A, Lepage C, Thavorn K, Fergusson D, Murnaghan O, Coyle D, Singh SS. Effectiveness of Outpatient Versus Operating Room Hysteroscopy for the Diagnosis and Treatment of Uterine Conditions: A Systematic Review and Meta-Analysis. *J Obstet Gynaecol Can* 2019; 41(7):930-941.

14. Nanayakkara P, Xiao J, Aref-Adib M, Ades A. Increasing the adoption of ambulatory hysteroscopy in Australia - cost comparisons and patient satisfaction. *J Obstet Gynaecol*, 2022; 42(3):509-513.

15. Shields J, Dilday E, Chang S, Walsh T, Kimberly K. Hysteroscopy in the Office vs the Operating Room: A Comparison of Clinical Outcomes, Resource Utilization and Costs. *JMIG* 2018;25(7):S117.

16. Nash R and Saidi S. Outpatient hysteroscopy: Suitable for all? A retrospective cohort study of safety, success and acceptability in Australia. *Aust N Z J of Obstet Gynaecol*, 2024; 64(5):475.
17. Jivraj S, Dass M, Panikkar J, Brown V. Outpatient hysteroscopy: an observational study of patient acceptability. *Medicina (Kaunas)*, 2004; 40(12):1207-10.
18. del Valle C, Solano JA, Rodriguez A, Alonso M. Pain management in outpatient hysteroscopy. *Gynecology and Minimally Invasive Therapy* 2016; 5(4):141- 147.
19. De Silva PM, Carnegy A, Graham C, Smith PP, Clark TJ. Conscious sedation for office hysteroscopy: A systematic review and meta-analysis. *Eur J Obstet Gynecol Reprod Biol* 2021; 266: 89-98.
20. Goswami D, Nisa N, Sharma A, Dadhwal V, Baidya DK, Arora M Low-Dose Ketamine for Outpatient Hysteroscopy: A Prospective, Randomised, Double- Blind Study. *TJ A R* 2020; 48(2):134-141.
21. Sharma JB, Aruna J, Kumar P, Roy KK, Malhotra N, Kumar S. Comparison of efficacy of oral drotaverine plus mefenamic acid with paracervical block and with intravenous sedation for pain relief during hysteroscopy and endometrial biopsy. *Indian J Med Sci* 2009;63(6):244-52.
22. Royal College of Obstetricians and Gynecologists. Best Practice in Outpatient Hysteroscopy. 2011.
23. Zimmer M, Pomorski M, Kamiński P, Doniec J, Huras H, Sieroszewski P, Sikora J, Stojko R, Ludwin A, Radwan M, Fuchs T. Polish Society of Gynecologists and Obstetricians Guidelines for the application of hysteroscopy in gynecology. *Ginekol Pol* 2019;90(8):482-489.
24. Deffieux X, Gauthier T, Menager N, Legendre G, Agostini A, Pierre F; French College of Gynaecologists and Obstetricians. Hysteroscopy: guidelines for clinical practice from the French College of Gynaecologists and Obstetricians. *Eur J Obstet Gynecol Reprod Biol* 2014;178:114-22.
25. van Dongen H, de Kroon CD, Jacobi CE, Trimbos JB, Jansen FW. Diagnostic hysteroscopy in abnormal uterine bleeding: a systematic review and meta-analysis. *BJOG* 2007;114(6):664-75.
26. Engelberg D, Pankratieva E, Liauchonak I. Diagnostic value of hysteroscopy in abnormal uterine bleeding. *Can Fam Physician* 2018;64(6):442-444.
27. Farquhar C, Ekeroma A, Furness S, Arroll B. A systematic review of transvaginal ultrasonography, sonohysterography and hysteroscopy for the investigation of abnormal uterine bleeding in premenopausal women. *Acta Obstet Gynecol Scand* 2003; 82(6):493-504.
28. Viganò S, Smedile A, Cazzella C, Marra P, Bonaffini PA, Sironi S. Abnormal Uterine Bleeding: A Pictorial Review on Differential Diagnosis and Not-So-Common Cases of Interventional Radiology Management. *Diagnostics* 202.;14(8):798.
29. Uhasai K, Naik D, Rathnamma P. Efficacy of MRI Over Ultrasound in Evaluation of Abnormal Uterine Bleeding With Histopathological Correlation. *Cureus* 2023; 15(5): e38560.
30. Tahmasebi F, Stewart S, Mitra A, Morje M, Sayasneh A. Transvaginal Saline Contrast Sonohystography to Investigate Postmenopausal Bleeding: A Systematic Review. *Cureus*,2020;12(8):e10094.
31. de Kroon CD, de Bock GH, Dieben SW, Jansen FW. Saline contrast



hysterosonography in abnormal uterine bleeding: a systematic review and meta-analysis. *BJOG* 2003; 110(10):938-47.

32. Vitale SG, Buzzaccarini G, Riemma G, Pacheco LA, Di Spiezio Sardo A, Carugno J, Chiantera V, Török P, Noventa M, Haimovich S, De Franciscis P, Perez-Medina T, Angioni S, Laganà AS. Endometrial biopsy: Indications, techniques and recommendations. An evidence-based guideline for clinical practice. *J Gynecol Obstet Hum Reprod* 2023; 52(6):102588.

33. van Hanegem N, Prins MM, Bongers MY, Opmeer BC, Sahota DS, Mol BW, Timmermans A. The accuracy of endometrial sampling in women with postmenopausal bleeding: a systematic review and meta-analysis. *Eur J Obstet Gynecol Reprod Biol* 2016; 197:147-55.

34. Cenksoy P, Ficicioglu C, Yildirim G, Yesiladali M. Hysteroscopic findings in women with recurrent IVF failures and the effect of correction of hysteroscopic findings on subsequent pregnancy rates. *Arch Gynecol Obstet* 2013;287(2):357-60.

35. Cao H, You D, Yuan M, Xi M. Hysteroscopy after repeated implantation failure of assisted reproductive technology: A meta- analysis. *J Obstet Gynaecol Res* 2018;44(3):365-373.

36. Vitale SG, Angioni S, Parry JP, Di Spiezio Sardo A, Haimovich S, Carugno J, Alonso Pacheco L, Perez-Medina T, Moawad N, De Franciscis P, Riemma G. Efficacy of Hysteroscopy in Improving Fertility Outcomes in Women Undergoing Assisted Reproductive Technique: A Systematic Review and Meta-Analysis of Randomized Controlled Trials. *Gynecol Obstet Invest* 2023;88(6):336-348.

37. Wortman M. "See-and-Treat" Hysteroscopy in the Management of

Endometrial Polyps. *Surg Technol Int* 2016; 28:177-84.

38. Craciunas L, Sajid MS, Howell R. Carbon dioxide versus normal saline as distension medium for diagnostic hysteroscopy: a systematic review and meta-analysis of randomized controlled trials. *Fertil Steril* 2013;100(6): 1709-14. e1-4.

39. De Iaco P, Marabini A, Stefanetti M, Del Vecchio C, Bovicelli L. Acceptability and pain of outpatient hysteroscopy. *JMIG* 2000; 7(1):71-5.

40. Amer-Cuenca JJ, Marín-Buck A, Vitale SG, La Rosa VL, Caruso S, Cianci A, Lisón JF. Non-pharmacological pain control in outpatient hysteroscopies. *Minim Invasive Ther Allied Technol* 2020; 29(1):10- 19.

41. Baradwan S, Khalil M, Alshahrani MS, Albouq B, AlSghan R, Khadawardi K, Mohamed DF, Yousef DH, Kamal SHM, Abdel Halim HW, Elhawary MAA, Alkholy EA, Elsharkawy MRM, Abdelhakim AM, Abbas AM, Dahshan SA, Alshawadfy A, Soror GI. Warm saline effectiveness for pain relief in office hysteroscopy: A systematic review and meta-analysis of randomized controlled trials. *J Obstet Gynaecol Res* 2022; 48(7):1523-1530.

42. De Silva PM, Stevenson H, Smith PP, Justin Clark T. A Systematic Review of the Effect of Type, Pressure, and Temperature of the Distension Medium on Pain During Office Hysteroscopy. *JMIG* 2021; 28(6):1148- 1159.e2.

43. Cooper NA, Clark TJ, Middleton L, Diwakar L, Smith P, Denny E, Roberts T, Tobert L, Jowett S, Daniels J; OPT Trial Collaborative Group. Outpatient versus inpatient uterine polyp treatment for abnormal uterine bleeding: randomized controlled non-inferiority study. *BMJ* 2015; 350:h1398.

44. Ren F, Huang G, Wang X, Li X, Cai J. Comparison of Hysteroscopic Morcellation Versus Resectoscopy in Treatment of Patients with Endometrial Lesions: A Meta-Analysis. *Med Sci Monit* 2022; 28:e936771.
45. AAGL practice report: practice guidelines for the diagnosis and management of endometrial polyps. *JMIG* 2012, 19(1):3-10.
46. Yong J, Wan Y, Ye M, Yi S, Zeng F, Sun X, Song J, Wang X, Zeng X, Xiao S. Comparative analysis of the clinical efficacy and reproductive outcomes of the hysteroscopic tissue removal system (MyoSure) and hysteroscopic electroresection in the treatment of benign intrauterine lesions. *Int J Gynaecol Obstet* 2023;163(1):115- 122.
47. Goldenberg M, Sivan E, Sharabi Z, Bider D, Rabinovici J, Seidman DS. Outcome of hysteroscopic resection of submucous myomas for infertility. *Fertil Steril* 1995; 64(4):714-716.
48. Etrusco A, Buzzaccarini G, Laganà AS, Chiantera V, Vitale SG, Angioni S, D'Alterio MN, Nappi L, Sorrentino F, Vitagliano A, Difonzo T, Riemma G, Mereu L, Favilli A, Peitsidis P, D'Amato A. Use of Diode Laser in Hysteroscopy for the Management of Intrauterine Pathology: A Systematic Review. *Diagnostics* 2024; 14(3):327.
49. Vitale SG, Parry JP, Carugno J, Cholkeri-Singh A, Della Corte L, Cianci S, Schiattarella A, Riemma G, De Franciscis P. Surgical and Reproductive Outcomes after Hysteroscopic Removal of Retained Products of Conception: A Systematic Review and Meta-analysis *JMIG* 2021; 28(2):204-217.
50. Practice Committee of the American Society for Reproductive Medicine. Evidence-based diagnosis and treatment for uterine septum: a guideline. *Fertil Steril* 2024;122(2):251-265.
51. Loddo A, Djokovic D, Drizi A, De Vree BP, Sedrati A, van Herendael BJ. Hysteroscopic myomectomy: The guidelines of the International Society for Gynecologic Endoscopy (ISGE). *Eur J Obstet Gynecol Reprod Biol* 2022; 268: 121- 128.
52. Zhang S, Di W, Wang Y, Shi J, Yin X, Zhang Y, Zhao A, Campo R, Bigatti G. Hysteroscopic myomectomy with the IBS® Intrauterine Bigatti Shaver: A Retrospective Comparative Analysis of the impact of rotational speed and aspiration flow rate. *Facts Views Vis Obgyn* 2023;15(1):53-59.
53. Yin X, Cheng J, Ansari SH, Campo R, Di W, Li W, Bigatti G. Hysteroscopic tissue removal systems for the treatment of intrauterine pathology: a systematic review and meta-analysis. *Facts Views Vis Obgyn* 2018;10(4):207-213.
54. Georgiou D, Tranoulis A, Jackson TL. Hysteroscopic tissue removal system (MyoSure) for the resection of polyps, submucosal leiomyomas and retained products of conception in an out-patient setting: A single UK institution experience. *Eur J Obstet Gynecol Reprod Biol* 2018; 231:147-151.
55. Bigatti G, Franchetti S, Rosales M, Baglioniet A. Hysteroscopic myomectomy with the IBS® Integrated Bigatti Shaver versus conventional bipolar resectoscope: a retrospective comparative study. *Gynecol Surg* 2014;11(1):9-18.
56. Lasmar RB, Barrozo PR, Dias R, Oliveira MA. Submucous myomas: a new presurgical classification to evaluate the viability of hysteroscopic surgical treatment--preliminary report. *JMIG* 2005; 12(4):308-11.
57. Taskin O, Sadik S, Onoglu A, Gokdeniz R, Erturan E, Burak F, Wheeler JM. Role of endometrial suppression on the frequency of

intrauterine adhesions after resectoscopic surgery *JMIG* 2000;7(3):351-354.

58. Tang R, Zhang W, Xiao X, Li W, Chen X, Wang X. Intrauterine interventions options for preventing recurrence after hysteroscopic adhesiolysis: a systematic review and network meta-analysis of randomized controlled trials. *Arch Gynecol Obstet* 2024;309(5):1847-1861.

59. Klein Meuleman SJM, Min N, Hehenkamp WJK, Post Uiterweer ED, Huirne JAF, de Leeuw RA. The definition, diagnosis, and symptoms of the uterine niche A systematic review. *Best Pract Res Clin Obstet Gynaecol* 2023; 90:102390.

60. Vervoort A, van der Voet LF, Hehenkamp W, Thurkow AL, van Kesteren P, Quartero H, Kuchenbecker W, Bongers M, Geomini P, de Vleeschouwer L, van Hooft M, van Vliet H, Veersema S, Renes WB, Oude Rengerink K, Zwolsman SE, Brölmann H, Mol B, Huirne J. Hysteroscopic resection of a uterine caesarean scar defect (niche) in women with postmenstrual spotting: a randomised controlled trial. *BJOG* 2018; 125(3):326-334.

61. Sánchez-Prieto M, Puy MJ, Barbany N, Graupera B, Pascual MA, Barri- Soldevila P. Conservative Management of Cesarean Scar Pregnancy: A Case Report and Literature Review. *Case Rep Obstet Gynecol* 2022; 2022:1793943.

62. Miller R, Timor-Tritsch IE, Gyamfi-Bannerman C. Society for Maternal- Fetal Medicine (SMFM) Consult Series #49: Cesarean scar pregnancy. *Am J Obstet Gynecol* 2020; 222(5):B2-B14.

63. Jordans IPM, Verberkt C, De Leeuw et al., Huirne JAF. Definition and sonographic reporting system for Cesarean scar pregnancy in early gestation: modified Delphi method. *Ultrasound Obstet Gynecol* 2022; 59(4):437-449.

64. Diakosavvas M, Kathopoulis N, Angelou K, Chatzipapas I, Zacharakis D, Kypriotis K, Grigoriadis T, Protopapas A. Hysteroscopic treatment of Cesarean Scar Pregnancy: A systematic review. *Eur J Obstet Gynecol Reprod Biol* 2022;270:42- 49.

65. Gkrozou F, Vatopoulou A, Skentou C, Paschopoulos M. Diagnosis and Treatment of Adenomyosis with Office Hysteroscopy-A Narrative Review of Literature. *Diagnostics (Basel)* 2023;13(13).

66. Davidson KG, Dubinsky TJ. Ultrasonographic evaluation of the endometrium in postmenopausal vaginal bleeding. *Radiol Clin North Am* 2003; 41(4):769- 80.

67. Gimpelson RJ, Rappold HO. A comparative study between panoramic hysteroscopy with directed biopsies and dilatation and curettage. A review of 276 cases. *Am J Obstet Gynecol* 1988; 158(3 Pt 1):489- 92.

68. Bernard JP, Lécuru F, Darles C, Robin F, de Bievre P, Taurelle R. Saline contrast sonohysterography as first-line investigation for women with uterine bleeding. *Ultrasound Obstet Gynecol* 1997;10(2):121-5.

69. Turner RT, Berman AM, Topel HC. Improved demonstration of endometrial polyps and submucous myomas using saline-enhanced vaginal sonohysterography. *J Am Assoc Gynecol Laparosc* 1995; 2(4): 421-5.

70. Créquat J, Pennehouat G, Cornier E, Naouri M, Thebault Y, Madelenat P. (Evaluation of intra-uterine pathology and tubal patency by contrast echography). *Contracept Fertil Sex* 199321(11):861-4.

## Diagnostic Hysteroscopy at the Nabil Choucair Health Center: Indications, Technique, Results

Author: Omar Gassama<sup>1</sup>, Mor Cisse<sup>1</sup>, Fatou Cise<sup>1</sup>, Lamine Gueye<sup>1</sup>, Fatoumata Bintou Diakhite<sup>1</sup>, Babacar Biaye<sup>1</sup>, Alassane Diouf<sup>1</sup>

Affiliation: <sup>1</sup> Department Obstetrics and Gynaecology, Aristide Le Dantec, Teaching hospital, Cheikh Anta Diop University, Dakar, Senegal

### Abstract

The objective of this study is to evaluate the socio-demographic characteristics of the patients, the indications, technique and results of diagnostic hysteroscopy at the Nabil Choucair health center Daker, Senegal.

### Material and Methods

This is a prospective, descriptive, cross-sectional study carried out at the Nabil Choucair health center in Dakar, Senegal, from July 01, 2023 until August 01, 2024, a period of 13 months. The study concerns 155 women who underwent a diagnostic hysteroscopy with exhaustive sampling. Hysteroscopy was performed on the ninth day of the menstrual cycle in cycling women and at any time in postmenopausal women. Hysteroscopy was performed by vaginoscopy. Parameters studied included socio-demographic characteristics, indications, technique and results. Data entry and analysis were performed using Epi info 7 software.

### Results

During the study period, 155 diagnostic hysteroscopies were performed. The mean age of the women was 35 years, varying between 20 and 73 years. In our series, the 30-39 age group (40%) was the most represented, followed by the 20-29 age group (29.1%). The women were married (94.5%) and lived mainly in the Dakar region (97.2%). Indications were dominated by infertility (50.9%). Other indications were cycle disorders (20.9%), endo cavitary pathologies on ultrasound (12.7%), recurrent abortion (11.8%), postmenopausal abnormal uterine bleeding (AUB) (5.5%). Hysteroscopy was abnormal in 71.8% of cases. Lesions found were endometrial polyps (36.4%), submucosal myomas (14.5%) and uterine synechiae (10%). The most frequently reported

complication was pain, ranging from simple discomfort to intense pain. Pain was reported by 17 patients (15%), with a visual analogue scale (VAS) score of 5.

## Conclusion

Hysteroscopy is an essential examination in the management of endocavitary gynaecological pathologies and the exploration of infertility. Its ease of use in conjunction with vaginoscopy should make it an extension of the gynecological examination in certain situations.

**Key words:** Diagnostic hysteroscopy, Vaginoscopy, Infertility, Endo-uterine pathologies, Senegal

---

*Corresponding author: Omar Gassama*

*DOI: 10.36205/trocar5.2025007*

*Received: 2025-03-17 – Accepted: 2025-04-07*

---

## Introduction:

Modern hysteroscopy is the fruit of almost 200 years of evolution, first enabling to see inside the uterine cavity and then to perform surgical procedures previously performed by laparotomy (1). The first endoscope enabling us to see inside the uterine cavity by reflecting external light was developed by the German Bozzini between 1804 and 1807. The first hysteroscopic examination on a live patient was performed by Pantaleoni in 1869 on a patient presenting with post-menopausal bleeding (2). Subsequent modifications have led to modern endoscopes. Hysteroscopy is an examination involving direct visualization of the interior of the uterine cavity using an optic passed through the cervical canal. It can be performed for diagnostic or therapeutic purposes. It is an examination that can be considered on an outpatient basis. Improved endoscopes with smaller outer diameter (now thinner, in the order of 15 French - 4,9 mm) and the use of gentle distension media such as saline under atmospheric pressure make this procedure simple and painless in

the vast majority of cases, enabling it to be widely used in outpatient clinics, with excellent patient acceptability (3). In addition, it offers the advantage of direct visualization of the uterine cavity and endometrium, enabling biopsies of suspicious anomalies to be taken during the procedure (4, 5). The technique is also useful for diagnosing abnormalities of the cervico-isthmus canal (false tract, recesses, niches, synechiae), endometrial hypertrophy or atrophy, endometrial congestion suggestive of endometritis, vascular dystrophy and small intra-cavitary lesions (polyps, submucosal myomas, synechiae). Hence its importance in the management of infertility and the etiological investigation of recurrent abortions. Thanks to advances in hysteroscopic instrumentation, the physician is now able not only to assess abnormal uterine bleeding (AUB), but also to plan treatment, which can considerably reduce the number of unnecessary major surgical interventions (6,7). Nevertheless, like any invasive procedure, hysteroscopy can give rise to complications, but these are rare and in the vast majority of cases minor (7).



Hysteroscopy has therefore become an indispensable complementary examination in gynecology, and the gold standard for diagnosing endo-uterine anomalies for some. In Senegal, numerous studies have been carried out to investigate the practice of hysteroscopy in our context. according to Diop et al of 168 hysteroscopies performed in 2019 at the CHU Aristide le Dantec, 72.47% of cases were found to have endo uterine lesions (8). In view of this impact on the diagnosis of gynecological pathologies; we were interested in the practice of diagnostic hysteroscopy at the Nabil Choucair health center (CSNC) in the Dakar health region during the period from July 2023 to August 2024.

## **Material and Methods:**

### **1.1 Type and duration of study**

A prospective study was conducted over a 13-month period from July 2023 to August 2024.

### **1.2 Study population**

The study population consisted essentially of women who consulted for diagnostic hysteroscopy during the period from July 2023 to August 2024.

#### **1.2.1 Inclusion criteria**

Included in the study were all patients who underwent diagnostic hysteroscopy during the study period.

#### **1.2.2 Exclusion criteria**

Patients whose files were incomplete and those whom we were unable to contact were not included in the study.

### **1.3 Data collection**

Data were collected using a survey form containing the following parameters: civil

status, history, indications, results, complications and technique used (see appendix). Data were obtained from a register completed by the physician.

### **1.4 Studied variables**

The variables studied were socio-demographic characteristics, patient history, indications, technique, results and complications.

### **1.5 Data entry and analysis**

Data entry and analysis were performed using Epi info 7 software. It comprised two parts: descriptive analysis and analytical analysis. Mean values and standard deviations were calculated for quantitative variables, and headcounts and percentages for qualitative variables. The analytical study consisted of an analysis of the different outcomes and complications according to history and indication. The Chi 2 test was used to compare proportions. The difference was statistically significant when the p-value was strictly less than 0,05.

### **1.6 Technique**

Vaginoscopic hysteroscopy is a “non-contact” technique considered to be the standard for ambulatory hysteroscopy. It is an atraumatic approach which considerably reduces the pain stimulus generated by the cervix and vagina through the use of the Pozzi's tenaculum forceps and speculum, as well as the manipulation of the instrument. The hysteroscope used is the one with rigid optics.

In the practice at the Centre de Santé Nabil Choucair in Dakar, vaginoscopy is the preferred method, and involves several stages.

- First stage: vaginal examination, to assess vaginal trophicity, the posterior vaginal cul-

de-sac and, above all, the orientation of the uterine cervix.

- Second step: the hysteroscope is gently introduced with the dominant hand, while the non-dominant hand opens the posterior vaginal fork. The hysteroscope is oriented towards the posterior vaginal cul-de-sac.

- Third step: the hysteroscope is withdrawn 1 to 2 cm from the posterior vaginal cul-de-sac and straightened in front of the external orifice of the uterine cervix, which is easy to see when diagnostic hysteroscopy is performed for unexplained vaginal bleeding, as a bloody discharge is noted, or for the visualization of cervical mucus.

- Fourth step: characterized by crossing of the internal os. At this point, the patient feels a sudden pain due to innervation of the endocervix, the glandular crypts of the endocervix can be observed.

- Fifth step: this consists of moving from the cervical-isthmic canal towards the uterine fundus, appreciating the ease and difficulty of advancing into the uterine cavity.

- Sixth step: this is an essential stage, and marks the start of the hysteroscopic exploration, with assessment of the uterine fundus, the anterior and posterior surfaces of the uterine cavity, the right and left lateral walls of the uterus, and the right and left tubal ostia. The endometrium and cervico-isthmic anatomy can also be assessed.

- Seventh step: the hysteroscope is withdrawn a few centimetres for a panoramic view of the uterine cavity.

- Eighth step: retrograde view of the uterine cavity, tubal ostia, cervico-isthmian canal, internal and external cervical orifices.

- Ninth step: the results are explained to the patient, and a report is drawn up.

During the sixth step, a biopsy may be performed in the case of isolated endometrial pathology or pathology associated with endometrial pathology.

## Results:

### 2.1 Frequency

During this period, 3914 patients underwent a gynaecological consultation at the Nabil Choucair health center. Of these, 155 had undergone diagnostic hysteroscopy. This represents a proportion of 3.96% hysteroscopies.

### 2.2 Socio-demographic characteristics

#### 2.2.1 Age

The mean age of the patients was 35 years, with extremes from 20 and 73 years. The 30-39 age group (40%) was the most represented, followed by the 20-29 age group (29.1%). Patients aged 30-39 accounted for 40% of cases (figure 1).

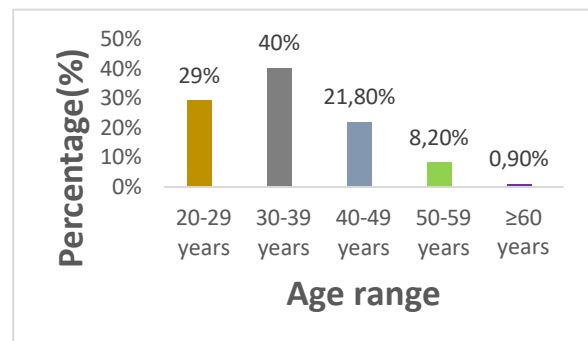


Figure 1: Age distribution of patients in years

#### 2.2.2 Marital status

In our series, all patients (94.5%) were married, singles (4.5%) and widows (1%).

#### 2.2.3 Background

##### 2.2.3.1 Gynecological and obstetrical history

- Sexual activity

In our study, 89.1% of patients were sexually active and 10.9% were menopausal.

#### - Menstrual cycle

The menstrual cycle was regular in 60.9% (n=67) of women.

The mean length of the menstrual period was 6 days, with extremes of 3 and 20 days.

#### - Contraception

In our study, only 15.5% of patients were on contraception. The pill was the main contraceptive method used (33.3%).

#### - Gestation

The average number of pregnancies was two, with extremes from 0 to 8. Nulligravidae represented the majority (36.4%, n=40), followed by paucigravida (23.6%, n=26). 20 % were primigravidae and multigravida

#### - Parity

The mean parity was  $1 \pm 1.8$ , with extremes from 0 to 8 deliveries. The median was one delivery. Nulliparous women accounted for 49.1% (n=54), followed by primiparous women 20% (n=22).

#### - Abortions

Concerning abortions, 34.5% (n=39) had a history of abortion, of which 30.9% (n=34) had had at least two.

### 2.2.3.2 Medical and surgical history

#### - Medical history

In this series, 14 patients (12.7%) had a medical history, arterial hypertension being the main one (50%, n=7).

#### -Surgical history

In this series, 17.3% (n=19) had a surgical history, and caesarean section was the main medical history reported (52.4%, n=11).

### 2.3 Indications for hysteroscopy

Infertility work-up 50.9% (n=56) was the main indication for hysteroscopy. Abortion assessment accounted for 11.8% of indications, (Fig 2).

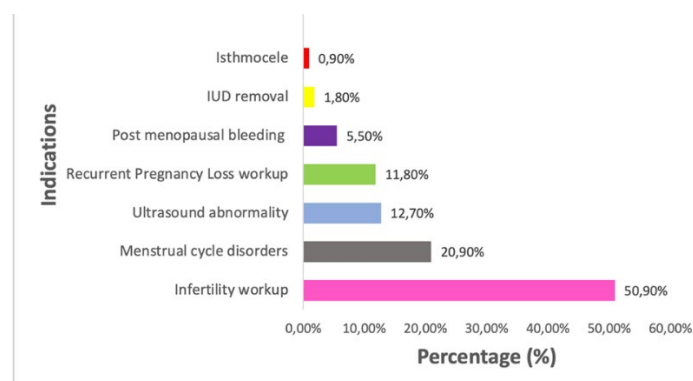


Figure 2: Distribution of patients according to hysteroscopy indications

### 2.4 Results of hysteroscopy

Hysteroscopic findings were abnormal in 71.8% of cases, and were mainly dominated by the presence of polyps (36.4%) and myoma characteristics (Fig 3, Fig 4, Fig 5).

It should also be noted that cervical preparation with Misoprostol was required in 3 patients (1.93%) prior to hysteroscopy, due to cervical spasm.

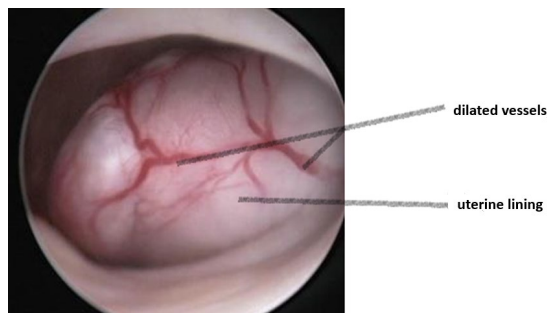


Fig 3: Submucosal fibroid

Hysteroscopy findings myoma (14.50%) as shown in figure 3.

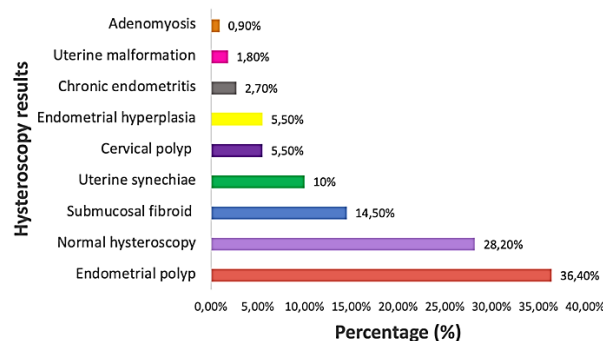


Figure 4: Distribution of patients according to the hysteroscopic findings

The hysteroscopic findings were mainly dominated by the presence of polyps (36.4%) a specimen is shown in figure 5.

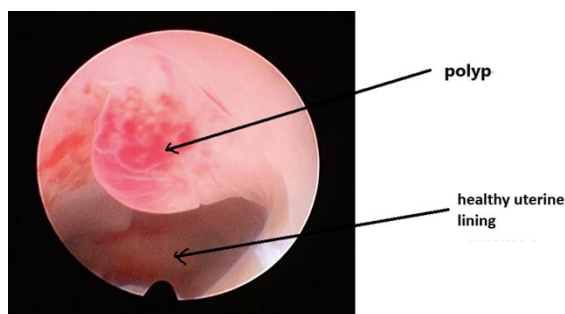


Figure 5: Uterine polyp

**2.4.1 Associated gestures during hysteroscopy** Associated procedures were performed on six patients (4.5%), with two biopsy curettages and two IUD removals.

## 2.4.2 Complications of hysteroscopy

Complications were noted in 19 (n=21) patients. Pain was the main complication (15.4%). Pain according to the mean VAS score was five, with extremes between 3 and 9.

## Discussion:

### 3.1 Frequency

During the study period, 155 patients underwent diagnostic hysteroscopy out of a total of 3914 gynaecological consultations, representing 3.96%. This frequency is relatively low compared with European series (9,10). This can be explained by the fact that hysteroscopy is not widely available in our region, due to the high cost for the population.

### 3.2 Socio-demographic characteristics

Our study concerned 155 patients who had undergone diagnostic hysteroscopy. Hysteroscopy was performed in both sexually active and postmenopausal women. However, the percentage of sexually active women was much higher, 89.1% versus 10.9%. The mean age in our series was 35, with extremes from 20 and 73. Patients aged between 30 and 39 accounted for the majority of cases (40%). Our results are similar to those reported by Diop 2021, Balde et al 2018 and Diallo et al 2013 (8,10, 11). In Kinshasa, DRC, according to the results of Nzau-Ngoma et al, the mean age was 35.7 years (12).

### 3.3 Gynaecological and obstetrical history

The average pregnancy rate was two, with extremes between one and eight. Nulligravidae accounted for 36.4% of cases. The average parity was one, with extremes between zero and eight. Nulliparous women

accounted for almost half of all patients, 49.1% (n=54).

### 3.4 Indications for hysteroscopy

More than half the women (50.9%, n=56) in this study had undergone a hysteroscopy for infertility, and the majority (69.1%) were aged between 20 and 40 years. According to several authors, it is important to explore the uterine cavity when assessing infertility, as numerous intra-uterine lesions can be found. Hysteroscopy is currently one of the most reliable means for the correct exploration of the uterine cavity (13,14,15,16). A retrospective study of 145 patients included in an in vitro fertilization program, in whom hysteroscopy had been systematically performed, showed 45% pathology. These lesions consisted mainly of endometritis, polyps and myomas, and dystrophic mucosa (17). Cycle disorders accounted for 26.3% of cases, and AUB for 43.5% (n=10) in women of childbearing age. Hysteroscopy is a useful diagnostic tool in the investigation of patients aged 40 and under with AUB, since it enables the detection of an intra-cavity lesion that is most often unidentifiable at endometrial biopsy. It therefore seems preferable to recommend diagnostic hysteroscopy rather than endometrial biopsy in the investigation of abnormal uterine bleeding in these women (18). Metrorrhagia was also found in postmenopausal women (5.5%, n=6). In 2019, at the CHU Le Dantec, menometrorrhagia constituted the majority of indications with 56.5% all ages combined (8). In cases of AUB in postmenopausal women, hysteroscopy can identify intrauterine lesions (19, 20). In cases of recurrent AUB or endometrial thickness greater than 4 mm in post-menopausal women, further uterine investigations (hysteroscopy and histology) are recommended (21). The endometrial pathology most frequently found during

hysteroscopy in women aged between 45 and 80 is the endometrial polyp (22). The search for the aetiology of recurrent abortions accounted for 11.8% of indications. Uterine anomaly is one of the main causes of recurrent miscarriage, in addition to age, genetics, phospholipid antibody syndrome and sperm quality. Studies have shown that congenital uterine anomalies occur in 4.3% of the general population of fertile women and in 12.6% of patients with recurrent pregnancy loss. Hysteroscopic evaluation of the uterine cavity is therefore recommended in these patients (23).

Hysteroscopy was performed following an abnormal ultrasound. Hysteroscopy was used to identify the various types of lesions. The main advantages of diagnostic hysteroscopy are direct visualization of the cervical canal and uterine cavity, and the possibility of targeted biopsies and even minor surgery (24). In 0.9% (n=1) of cases, it was performed for postoperative uterine control in a woman with a symptomatic isthmocele following Caesarean Section (CS).

### 3.5 Hysteroscopic technique

At the Nabil Choucair health center, the technique used is vaginoscopy. This is the technique recommended by several authors to minimize complications (16-17). In a study comparing vaginoscopy with the standard technique, the success rates of the techniques were comparable (95.5% vs. 96.3%), but the median time required to perform vaginoscopy (135 seconds) was significantly shorter than for standard hysteroscopy (190 seconds). The median pain score was also significantly lower than for standard hysteroscopy (18). In this series hysteroscopy was performed without anesthesia, during the first phase of the cycle. The use of Misoprostol for cervical preparation was not systematic. Vaginal Misoprostol reduces cervical resistance in women undergoing



hysteroscopy and facilitates the procedure, with only mild side effects (19). No antibiotic prophylaxis was used. Saline was used as a distension medium. Hysteroscopy was performed on an outpatient basis, and no hospitalization was observed. These different techniques were recommended to reduce the frequency of per- and post-hysteroscopic complications (9,19,20). A prospective study of 530 in-office diagnostic mini-hysteroscopies performed on infertile patients demonstrated that the use of an atraumatic insertion technique, an aqueous distension medium and the new generation of mini-hysteroscopes, enabled hysteroscopy to be performed without any form of anaesthesia and with high patient compliance. The high number of abnormal findings (28.5%), the absence of complications and the low failure rate (2.3%) indicate that in-office diagnostic mini-hysteroscopy should be a first-line diagnostic procedure (21).

The failure rate was 2.72% in this series. Hysteroscopy could not be performed in three women due to cervical spasm. In two of these women, cervical preparation with Misoprostol was performed, enabling successful hysteroscopy. High success rates of over 90% are consistently reported for such outpatient procedures in the various reviews. The most common failure rates reported in the literature are due to pain and the inability to visualize the uterine cavity correctly due to cervical stenosis (22). Vasovagal episodes have also been reported (23). A retrospective observation of 512 hysteroscopies from January 2016 to November 2018 had shown an office hysteroscopy failure rate of around 12% (n=16). Severe pain due to cervical stenosis, previous surgery on the uterus, menopause and marked retroflexion of the uterus were the main reasons for failure reported (22). Furthermore, operator experience appears to

be a key factor both for accurate endometrial assessment and for reducing failure rates (24, 25).

### 3.6 Hysteroscopic findings

Hysteroscopy was abnormal in 71.8% of cases. The abnormalities found were mainly endometrial polyps, submucosal myomas, uterine synechiae and endometrial hypertrophy. The percentage of endometrial polyps was 36.4%. And this finding concerned both menopausal and sexually active women. Submucosal myomas accounted for 14.5% of cases. These are the two most common hysteroscopic anomalies in cases of infertility (26). Uterine synechiae were found in 10% of women. Five women had a history of curettage and two had a history of pelvic surgery. This confirms that uterine synechiae are most often of post-traumatic origin, occurring in 90% of cases in the post-partum or post-abortum period (19). According to Schenker and Margalioth, among the 1856 cases of Asherman syndrome found in a review of the literature, pregnancy was the dominant predisposing factor found in 90.8%, with 66.7% of synechiae occurring after post-abortal curettage, 21.5% after post-partum curettage, and 2% after CS (27). Hysteroscopy is by far the best tool for diagnosing intrauterine adhesions and assessing their severity in real time (28).

In 5.5% of cases, there was endometrial congestion. At CHU Le Dantec endometrial hypertrophy was the most common anomaly, with 93 cases (60.1%) (8).

In this series, only 1.8% (n=2) of women had a uterine malformation, most frequently a septate uterus. In addition to a septate uterus, one of these women had a bicornuate uterus. Diagnostic hysteroscopy plays an essential role in the diagnosis and management of congenital anomalies of the

genital tract. Combined with clinical examination and imaging, it is a valuable tool for evaluating and correcting these anomalies (29).

### 3.7. Related procedures during hysteroscopy

Following diagnostic hysteroscopy, procedures were performed on 4.5% (n=5) of patients. Two successful intrauterine device (IUD) removals were performed. It was confirmed that hysteroscopy can indeed be used to remove IUDs that are difficult to remove. It is an effective method, generally well tolerated, with low morbidity (30). Out of 12 women who consulted for IUD wire migration, the IUD was found by hysteroscopy in the uterine cavity in 10 cases and successfully removed. Vaginoscopy can also be used to remove intra-vaginal foreign bodies more safely (31).

Uterine biopsy was performed in two women with suspicious lesions, including endometrial hypertrophy and adenomyosis. Hysteroscopic endometrial biopsy is often recommended. It enables targeted sampling when there is a localized abnormality (32). A polypectomy was performed in a 26-year-old nulligravida woman who had consulted for AUB. Hysteroscopy revealed an endometrial polyp, which was successfully resected.

### 3.8 Complications

Vaginoscopy is a speculum- and tenaculum-free hysteroscopic technique offering the greatest patient comfort and the lowest pain levels (29). The approach used to insert the scope, as well as the diameter of the hysteroscope and distension of the uterine cavity, are of extreme importance in minimizing patient discomfort during an ambulatory examination. One of the major problems with endoscopes is passage through the cervical os (28).

In our series, complications were rare and in the majority of cases minor. In 17 cases the patients reported pain. The majority were moderate, of the discomfort type, with an average VAS of five. Only one case of severe pain was reported in a 52-year-old G8P2 patient with a history of post-abortion curettage who had consulted us for post-menopausal AUB, and in whom the hysteroscopy was in favour of uterine synechia.

### Conclusion:

Diagnostic hysteroscopy is undoubtedly an essential complementary examination in gynaecology. Today, it is recognized as the gold standard in endo-uterine exploration. Its diagnostic value lies in its ability to directly explore the uterine cavity.

### References:

1. Russell JB. History and development of hysteroscopy. *Obstet Gynecol Clin North Am.* 1988; 15:1-11.
2. Siegler AM. The early history of hysteroscopy. *J Am Assoc Gynecol Laparosc.* 1998; 5:329-32.
3. Centini G, Troia L, Lazzeri L, Petraglia F, Luisi S. Modern operative hysteroscopy. *Minerva Ginecol.* 2016; 68:126-32.
4. March CM. Hysteroscopy. *J Reprod Med.* 1992; 37:293-311; discussion 311-312.
5. Okohue JE. Overview of Hysteroscopy. *West Afr J Med.* 2020; 37:178-82.
6. Serden SP. Diagnostic hysteroscopy to evaluate the cause of abnormal uterine bleeding. *Obstet Gynecol Clin North Am.* 2000; 27:277-86.

7. Kužel D, Hrazdírová L, Mára M, Fanta M, Hrušková H, Kubínová K. [Office hysteroscopy - management and results]. *Ceska Gynekol.* 2012; 77:308-13.
8. Diop B. Pratique de l'hystérocopie diagnostique à la clinique gynécologique et obstétricale du CHU le Dantec. [Mémoire pour l'obtention du diplôme d'étude spécialisée en gynécologie obstétrique] Dakar: Université Cheikh Anta DIOP; 2021 N°0300
9. Deffieux X, Gauthier T, Ménager N, Legendre G, Agostini A, Pierre F. Prevention of complications of hysteroscopy: recommendations for clinical practice. *Eur J Obstet Gynecol Reprod Biol.* 2013; 42:1032-49.
10. Diallo FB. Bilan de l'hystérocopie au center hospitalier de ROI BAUDOUIN: à propos de 313 cas (Dakar-Sénégal). [Thèse de doctorat en médecine] Dakar: Université Cheikh Anta DIOP; 2013 N°48638
11. Balde F. Bilan d'activités hystérocopiques au centre hospitalier national de Pikine. Du 1er Janvier 2017 au 31 Décembre 2018. [Mémoire pour l'obtention de diplôme d'études spécialisées en gynécologie obstétrique]. Université Cheikh Anta Diop de DAKAR. 2020 N° 0014
12. Mindombe Moleko P, Lumingo Lusakueno A, Biawila Lusila B, Kusuman A, Odimba Mpoy J, Kintoki Makundika O, Ndesanim Otem C, Nzau-Ngoma E. Hysteroscopic findings in patients presenting with abnormal uterine bleeding in a Congolese population of Kinshasa The Trocar 2024;1(5): 01-16 doi:10.36205/trocar5.2024001
13. Ben Abid H, Fekih M, Fathallah K, Chachia S, Bibi M, Khairi H. Hystérocopie en cabinet avant la première fécondation in vitro. A randomized controlled trial. *J Gynecol Obstet Hum Reprod.* 2021;50:102109.
14. Pundir J, Pundir V, Omanwa K, Khalaf Y, El-Toukhy T. Hysteroscopy prior to the first IVF cycle: a systematic review and meta-analysis. *Reprod Biomed Online.* 2014;28:151-61.
15. Deffieux X, Gauthier T, Ménager N, Legendre G, Agostini A, Pierre F. Prévention des complications de l'hystérocopie: recommandations pour la pratique clinique. *Journal de Gynécologie Obstétrique et Biologie de la Reproduction.* 2013; 42:1032-49.
16. De Silva PM, Carnegy A, Smith PP, Clark TJ. Vaginoscopy for office hysteroscopy: A systematic review & meta-analysis. *Eur J Obstet Gynecol Reprod Biol.* 2020; 252:278-85.
17. Cholkari-Singh A, Sasaki KJ. Hysteroscopy safety. *Curr Opin Obstet Gynecol.* 2016;28:250-4.
18. Preutthipan S, Herabutya Y. A randomized controlled trial of vaginal misoprostol for cervical priming before hysteroscopy. *Obstetrics & Gynecology.* 1999; 94:427-30.
19. McGurgan PM, McIlwaine P. Complications of hysteroscopy and how to avoid them. *Best Pract Res Clin Obstet Gynaecol.* 2015; 29:982-93.
20. Campo V, Campo S. [Exigences et complications de l'hystérocopie]. *Minerva Ginecol.* 2007; 59:451-7.
21. Genovese F, D'Urso G, Di Guardo F, Insalaco G, Tuscano A, Ciotta L, et al. Failed diagnostic hysteroscopy: Analyse de 62 cas. *Eur J Obstet Gynecol Reprod Biol.* 2020; 245:193-7.

22. Murdoch JA, Gan TJ. Anesthesia for hysteroscopy. *Anesthesiol Clin North Am*. 2001; 19:125-40.
23. Valli E, Zupi E, Marconi D, Solima E, Nagar G, Romanini C. Outpatient diagnostic hysteroscopy. *J Am Assoc Gynecol Laparosc*. 1998; 5:397-402.
24. Buzzaccarini G, Alonso Pacheco L, Vitagliano A, Haimovich S, Chiantera V, Török P, et al. Pain Management during Office Hysteroscopy: An Evidence-Based Approach. *Medicina (Kaunas)*. 2022;58:1132.
25. Agostini A, Franchi F, Bretelle F, Roger V, Cravello L, Blanc B. Place de l'hystérocopie diagnostique dans le bilan de l'infertilité. *EMC - Gynécologie-Obstétrique*. 2005; 2:163-6.
26. Féghali J, Bakar J, Mayenga JM, Ségard L, Hamou J, Driguez P, et al. Systematic hysteroscopy before in vitro fertilization. *Gynecology Obstetrics & Fertility*. 2003; 31:127-31.
27. Beaumont M-C, Laberge PY, Bérubé S, Bazin S, Blanchet P. Hysteroscopic findings in women aged 40 and under with abnormal uterine bleeding. *Journal SOGC*. 2000; 22:1036-40.
28. van Dongen H, de Kroon CD, Jacobi CE, Trimbos JB, Jansen FW. Diagnostic hysteroscopy in abnormal uterine bleeding: a systematic review and meta-analysis. *BJOG*. 2007; 114:664-75.
29. Taylor PJ, Gomel V. Endometrial ablation: indications and preliminary diagnostic hysteroscopy. *Bailliere's Clin Obstet Gynaecol*. 1995; 9:251-60.
30. Hamdaoui N, Boubli L. La gestion des effets secondaires sous traitement hormonal de la ménopause: saignements utérins anormaux. *RPC Les femmes ménopausées du CNGOF et du GEMVi. Gynecology Obstetrics Fertility & Senology*. 2021; 49:474-84.
31. Wieser F, Albrecht A, Kurz C, Wenzl R, Nagele F. [Ambulatory hysteroscopy in evaluation of postmenopausal bleeding]. *Wien Klin Wochenschr*. 1999; 111:289-93.
32. Costa H de LFF, Costa LOBF. [Hysteroscopy in menopause: analysis of the techniques and accuracy of the method]. *Rev Bras Gynecol Obstet*. 2008;30:524-30.

## Microwave Ablation of Diffuse Uterine Adenomyosis: A Novel Minimally Invasive Fertility Preserving Therapeutic Approach

Author: Sanchari Pal 1; Jay Mehta<sup>1</sup>; Vismay Pandya 1

Affiliation: <sup>1</sup> Shree Fertility and Healthcare Mumbai, India

### Abstract

#### Introduction:

Adenomyosis is a chronic gynecological disorder characterized by invasion of endometrial glands and stroma within the myometrium, frequently resulting in debilitating pelvic pain, menorrhagia, and impaired fertility.

#### Objective:

This study aims to evaluate the safety, efficacy, and clinical outcomes of ultrasound-guided microwave ablation (MWA) to manage diffuse adenomyosis in a cohort of 100 patients, focusing on symptom relief, uterine volume reduction, and complication rates.

#### Method:

A prospective, single-arm clinical study of 100 women aged 28–50 years with diffuse adenomyosis was conducted. All patients underwent MWA under general anesthesia with ultrasound guidance. Symptom severity was measured using the Visual Analog Scale (VAS) for pain and the Pictorial Blood Loss Assessment Chart (PBAC) for menstrual bleeding. Uterine volume was evaluated using transvaginal ultrasound. Follow-up assessments were conducted at one, two-, and six-months post-procedure.

#### Results:

At 6 months, dysmenorrhea VAS scores showed an average reduction of 78%, and 92% of patients reported significant improvement in menorrhagia. The average reduction in uterine volume was 30% at 2 months and 40% at 6 months. No major complications were observed. Minor adverse effects included transient pelvic discomfort in 6% of cases.

#### Conclusion:

Ultrasound-guided MWA is a minimally invasive, uterus-preserving intervention that



demonstrates significant symptom relief and reduction in uterine volume in patients with diffuse adenomyosis.

**Key words:** Uterine adenomyosis, microwave ablation, MWA in adenomyosis, USG guided microwave ablation, fertility preserving treatment in adenomyosis

---

*Corresponding author: Sanchari Pal*

*DOI: 10.36205/trocar5.2025008*

*Received: 2025-04-27 – Accepted: 2025-05-15*

---

## **Introduction:**

Adenomyosis is a benign uterine disorder characterized by the infiltration of endometrial tissue into the myometrium, leading to a diffusely enlarged uterus and the disruption of normal uterine architecture. Clinically, it presents with symptoms such as dysmenorrhea, heavy menstrual bleeding, chronic pelvic pain, and, in some cases, subfertility or infertility. The condition is estimated to affect up to 20–30% of women in the general population and is most commonly diagnosed in women between the ages of 30 and 50 (1). However, recent advancements in imaging have shown that adenomyosis may be underdiagnosed, especially in younger women and those with overlapping symptoms of fibroids or endometriosis. Traditionally, the gold standard for diagnosing adenomyosis was histopathological evaluation following hysterectomy. However, the advent of high-resolution transvaginal ultrasound (TVUS) and magnetic resonance imaging (MRI) has enabled non-invasive diagnosis with increasing accuracy. On ultrasound, features such as myometrial cysts, a heterogeneous myometrium, and a thickened junctional zone are commonly used criteria (2). Management options for adenomyosis are typically categorized into medical, surgical, and minimally invasive therapies. Medical

treatment primarily includes hormonal agents such as progestins, combined oral contraceptives, and GnRH analogs (3). While these treatments may provide temporary relief, symptoms frequently recur upon cessation. Definitive surgical treatment by hysterectomy remains a commonly performed procedure, particularly in women who have completed childbearing. However, hysterectomy is not an ideal solution for women who wish to preserve fertility or avoid major surgery (3,4). Minimally invasive techniques such as uterine artery embolization (UAE) and high-intensity focused ultrasound (HIFU) have emerged as uterus-preserving alternatives. Although effective in certain cases, UAE may result in uterine ischemia, while HIFU is limited by the depth and vascularity of the lesion, operator experience, and patient selection (5). Microwave ablation (MWA) has gained attention as a newer thermal ablation modality. MWA utilizes electromagnetic energy to create localized tissue necrosis through dielectric heating (5). Unlike radiofrequency ablation, MWA allows higher temperatures over larger volumes and is less affected by tissue impedance. This technique has been well studied in liver and renal tumors and is now being adapted for gynecological applications. This study evaluates the application of ultrasound-

guided MWA in a cohort of 100 women diagnosed with diffuse adenomyosis. The aim is to provide real-world data on clinical outcomes, including symptom relief, uterine volume reduction, and procedural safety, thereby supporting its role as a viable alternative to hysterectomy.

## Material and Methods:

### 1.1 Study Design and Participants

This prospective observational study was conducted at a tertiary care center between January 2022 and June 2023. A total of 100 women aged between 28 and 50 years with clinically and radiologically confirmed diffuse adenomyosis were included. Diagnosis was based on transvaginal ultrasound (TVUS) findings such as a globular uterus, asymmetrical myometrial thickening, myometrial cysts, and hyperechoic striations. Patients provided informed consent and ethical approval was obtained from the institutional review board.

### 1.2. Inclusion and Exclusion Criteria

Inclusion criteria were:

1. age between 25 and 50 years
2. symptomatic diffuse adenomyosis refractory to medical treatment
3. no desire for immediate conception
4. willingness to undergo general anesthesia

Exclusion criteria included:

1. focal adenomyosis or concurrent large fibroids (>5 cm)
2. suspected malignancy
3. pregnancy
4. uterine length on ultrasound more than 12 cm
5. contraindications to general anesthesia.

### 1.3. Microwave Ablation Protocol

A careful selection of symptomatic patients with diffuse uterine adenomyosis was made. Under general anesthesia, patient was placed in lithotomy position and standard laparoscopic port entry was made. Intraoperative picture was assessed. Areas of most uterine density were assessed laparoscopically. Simultaneously, an intraoperative transvaginal ultrasound probe was inserted to map the areas of adenomyosis. Under USG guidance, the microwave ablation needle was inserted into the uterus percutaneously and the hyperechoic needle tract followed on USG to ensure that the needle is well away from the endometrium.



Figure 1: Microwave Ablation probe with attachment cord. Note the insulated probe tip.

Once the desired area is reached, ablation power was set between 40–60 W (rarely, up to 80 watts in case of diffuse adenomyosis),

and each cycle lasted 5-7 minutes depending on the lesion size and impedance feedback. Multiple overlapping ablations were performed as needed to cover the entire affected area. A period of probe cooling was maintained in between ablating two regions wherein probe temperature was brought back to 18 degrees Celsius using an internal circulation (within the ablation probe) of chilled normal saline. Throughout the ablation procedure, temperature was continuously recorded on the Canyon device and ablation was stopped if temperatures reached above 30 degrees. Ice packs and saline irrigation were used to protect adjacent organs from thermal spread. Throughout the procedure, the uterus was lifted up from the adjacent bowel and viscera, supported by two Alli's forceps inserted through the two lateral ports.

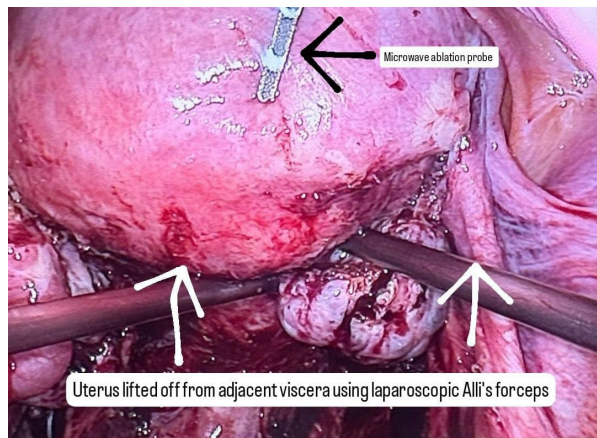


Figure 2: Intraoperative photo of microwave ablation probe during the procedure.

The MWA system utilized was Canyon Medical Inc. KY-2000A, operating at a frequency of 2.45 GHz with power output adjustable up to 100 W.



Figure 3: The Canyon KY 2000A MWA system. Note that the wattage is set at 100 Watts, the total time is at 7 minutes and the run time at the time of taking this picture is 6 minutes and 47 seconds. Probe temperature as recorded is 21.5 degrees Celsius.

#### 1.4. Postoperative Management and Follow-Up

Patients were observed for 24 hours post-procedure. Approximately, 10% of patients complained of cramping post-operative pain. Non-steroidal anti-inflammatory drugs (NSAIDs) were administered for pain control. Follow-up was scheduled at 1, 3, and 6 months. Assessments included:

- Pain assessment using the Visual Analog Scale (VAS)
- Menstrual blood loss quantified via Pictorial Blood Loss Assessment Chart (PBAC)
- Uterine volume calculated using ultrasound:  

$$V = 0.523 \times L \times W \times H$$
- Complication monitoring (e.g., infection, thermal injury)

Symptom improvement was defined as a  $\geq 50\%$  reduction in VAS or PBAC scores. Imaging was performed at each follow-up visit to assess volume changes and resolution of adenomyotic zones.

## Results:

### 2.1. Patient Demographics and Baseline Characteristics

The study included 100 women with a mean age of  $38.4 \pm 5.7$  years. The average duration of symptoms prior to intervention was  $3.6 \pm 1.2$  years. All patients reported dysmenorrhea, and 92% reported menorrhagia. The average baseline VAS score for pelvic pain was  $8.2 \pm 1.1$ , while the mean PBAC score was  $365 \pm 54$ . Mean uterine volume at baseline was  $180 \pm 45 \text{ cm}^3$ .

### 2.2. Procedural Details

MWA was successfully performed in all 100 patients (technical success rate: 100%). The mean number of ablation zones was  $4.2 \pm 1.1$ , and average ablation time was  $26 \pm 7$  minutes per patient. No intraoperative complications such as bowel injury or uterine perforation were encountered.

### 2.3. Clinical Outcomes

At 1-month follow-up, VAS scores decreased to  $4.1 \pm 0.9$  and continued to decline to  $3.0 \pm 0.7$  at 3 months and  $1.8 \pm 0.6$  at 6 months. PBAC scores showed parallel improvements, with a 65% reduction observed by 6 months. At 6 months, 92% of patients had at least a 50% reduction in symptom severity, with 67% reporting near-complete resolution of dysmenorrhea.

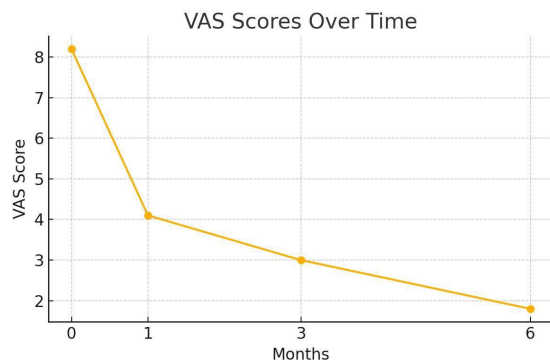


Figure 4: VAS scores over time

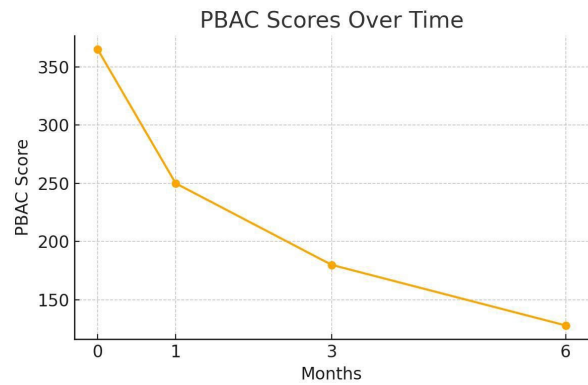


Figure 5: PBAC scores over time

### 2.4. Uterine Volume Reduction

Mean uterine volume decreased by 30% at 2 months and 40% at 6 months. No patient required a repeat ablation or surgical intervention during the follow-up period.

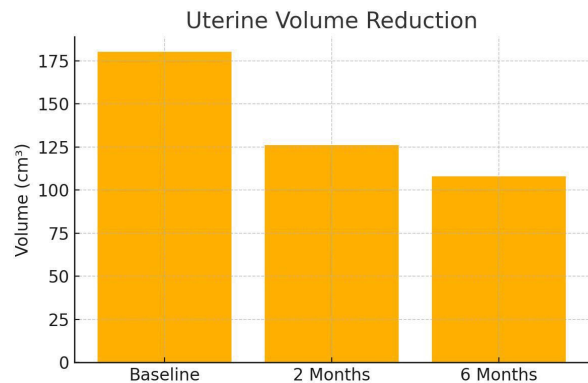


Figure 6: Uterine volume reduction with time

### 2.5. Complications and Safety

No major complications were reported. Around 10% of patients complained of cramping post-operative pain during immediate post-op Day 1 which was easily resolved with mild dose of analgesics like NSAIDs. Minor adverse effects were noted in 6% of patients, including transient pelvic pain and low-grade fever. These resolved spontaneously or with symptomatic treatment within 48–72 hours. Around 17% of patients reported mild watery discharge



vaginally up to one month post-surgery which could potentially be extrusion of the tissue destroyed by heat necrosis during ablation. In most cases, this complaint also typically resolved spontaneously within 6-8 weeks postoperatively. No active intervention was required. No cases of any vaginal infection were noted.

### Discussion:

This prospective study evaluates the use of microwave ablation for treating diffuse adenomyosis in a relatively large patient cohort. The results confirm the hypothesis that ultrasound-guided MWA can be a safe, effective, and minimally invasive option for women who wish to preserve their uterus while obtaining durable symptom relief. Compared with other uterine-sparing treatments such as UAE and HIFU, MWA offers several advantages (6,7). The precision of ultrasound guidance allows for targeted delivery of thermal energy, minimizing damage to surrounding tissues. Unlike UAE, which relies on embolic agents and induces ischemia in the entire uterine body, MWA focuses only on adenomyotic zones, preserving normal myometrial function. HIFU, while non-invasive, has limitations such as long treatment durations and dependence on favorable acoustic windows, which may not be available in all patients. The observed uterine volume reductions and symptom improvements are consistent with findings from smaller case series and pilot studies. Our data aligns with recent studies by Zhou et al. and Wang et al., where microwave ablation demonstrated significant pain and bleeding relief with a low rate of complications (7). Mechanistically, MWA causes tissue necrosis through rapid dielectric heating, creating uniform ablation zones that are less dependent on tissue impedance. This advantage may contribute to the consistently favorable outcomes seen

in this study. The absence of serious complications supports its safety in clinical settings. Nonetheless, certain limitations must be acknowledged. First, the study lacked a control group, and long-term outcomes beyond 6 months remain unknown. Additionally, the absence of fertility-related outcomes limits conclusions for women desiring future pregnancies. A randomized controlled trial with extended follow-up would provide more robust evidence. Microwave ablation (MWA) induces tissue necrosis through dielectric heating: microwave-frequency electromagnetic waves cause rapid oscillation of polar molecules (primarily water) within tissues, generating frictional heat and resulting in coagulative necrosis of the cells (7,8). The MWA antenna is inserted directly into the target uterine tissue under imaging guidance, creating a localized electromagnetic field that heats the adenomyotic lesion from within. Unlike radiofrequency ablation, which is limited by rising tissue impedance as tissues desiccate and by heat-sink effects from blood flow (9), microwave energy can continue depositing thermal energy regardless of tissue charring and is less affected by perfusion. Consequently, MWA reaches higher temperatures more quickly and produces larger, more homogenous ablation volumes than radiofrequency methods, enabling more complete destruction of ectopic endometrial tissue. This mechanism is particularly advantageous for diffuse adenomyosis, as multiple or broad areas of the myometrium can be ablated in a controlled manner, reducing lesion volume and alleviating symptoms while preserving the overall uterine structure. Notably, MWA is a uterus-sparing approach—patients avoid hysterectomy—and clinical reports have shown significant symptom relief without impairment of ovarian function following MWA treatment for adenomyosis. Despite



these therapeutic benefits, MWA is associated with certain adverse effects in gynecologic applications. Short-term post-ablation symptoms commonly include pelvic pain or cramping and vaginal bleeding or discharge as necrotic tissue is evacuated (9). Minor procedure-related injuries such as superficial skin burns at the probe entry site or transient nerve irritation have also been reported. Infection is a notable risk: if excessive thermal damage extends to or disrupts the endometrium, patients may develop endometritis or pelvic infection, and cases of post-ablation intrauterine infection have been documented. Longer-term effects include scar formation and pelvic adhesions – a particular concern in diffuse disease where large areas are ablated. Such adhesions can cause chronic pelvic pain or complicate future surgeries; for example, one case report described extensive post-MWA adhesions between the uterus and adjacent organs, which led to bowel obstruction, infection, and a urinary fistula after a subsequent hysterectomy. Although serious complications are rare, they can include unintended thermal injury to adjacent bowel or bladder (potentially causing perforation or fistula) as well as uterine perforation with hemorrhage. One clinical study (10) reported minor complications in 51.7% of cases and a ~5% incidence of major complications with MWA, underscoring that while the procedure is generally safe, meticulous technique and appropriate patient selection are critical to minimizing risks. Lastly, a note on pre-operative hormonal therapy. We have not used any pre-operative hormonal therapy in any of our cases. Some cases were referred to us from our Indian colleagues, wherein they were started on GnRH analogues or Norethisterone acetate (controlled release formulations) by the primary gynecologist to treat symptoms. However, we did not note any surgical differences while performing MWA on patients without pre-operative

hormonal therapy when compared to patients with pre-operative hormonal therapy.

### **Conclusion:**

Microwave ablation appears to be a highly promising therapeutic modality for diffuse adenomyosis, offering significant symptom relief with minimal complications. Its uterus-sparing nature and real-time guidance make it an appealing alternative to hysterectomy for women with symptomatic disease. Our findings support the integration of MWA into the therapeutic algorithm for adenomyosis, especially in cases refractory to medical management. Further longitudinal studies are warranted to assess the durability of symptom control, the impact on fertility, and comparative efficacy with other interventional modalities.

### **References:**

1. García-Solares J, Donnez J, Donnez O, Dolmans MM. Pathogenesis of adenomyosis: Invagination or metaplasia? *Fertil Steril*. 2018;109(3):371–379.
2. Taran FA, Stewart EA, Brucker S. Adenomyosis: Epidemiology, risk factors, clinical phenotype and surgical and interventional alternatives to hysterectomy. *Geburtshilfe Frauenheilkd*. 2013;73(9):924–931.
3. Dueholm M. Transvaginal ultrasound for diagnosis of adenomyosis: A review. *Best Pract Res Clin Obstet Gynaecol*. 2006;20(4):569–582.
4. Bergeron C, Amant F, Ferenczy A. Pathology and physiopathology of adenomyosis. *Best Pract Res Clin Obstet Gynaecol*. 2006;20(4):511–521.
5. Grimbizis GF, Mikos T, Tarlatzis BC. Uterus-sparing operative treatment for

adenomyosis. *Fertil Steril*. 2014;101(2):472–487.

6.Fan TY, Wang QH, Wang Y, et al. Ultrasound-guided percutaneous microwave ablation of adenomyosis: Preliminary results. *Int J Hyperthermia*. 2019;36(1):617–623.

7.Zhou M, Chen J, Wu C, et al. Clinical evaluation of ultrasound-guided microwave ablation in the treatment of adenomyosis. *BJOG*. 2021;128(5):881–888.

8.Ji Y, Zhang Y, Yan L, et al. Short- and long-term outcomes of high-intensity focused ultrasound treatment for symptomatic adenomyosis. *J Ultrasound Med*. 2016;35(7):1435–1440.

9.Wang Y, Chen J, Zhang Y, et al. A comparison of microwave ablation and uterine artery embolization for the treatment of adenomyosis. *JMIG*. 2020;27(6):1358–1364.

10.Peng J, Zheng L, Chen Y, et al. Ultrasound-guided percutaneous microwave ablation for symptomatic adenomyosis: A feasibility study. *Int J Hyperthermia*. 2022;39(1):344–350.

## Beyond the Pelvis: Multidisciplinary Surgical Management of Extra Pelvic Endometriosis – A Video Case Series report

**Author:** Lucia Chaul<sup>1</sup>, Ana Gabriela Siera Brozon<sup>1</sup>, Ramiro Cabrera Carranco<sup>1</sup>, Alicia Estrada<sup>1</sup>, William Kondo<sup>2</sup>, Armando Menocal<sup>3</sup>

**Affiliation:** <sup>1</sup> Female Pelvic Surgery Department, Doyenne High Quality and Multidisciplinary Treatment Center for Endometriosis, Mexico City, Mexico.

<sup>2</sup> Centro Medico Hospitalar Sugisawa, Brasilia, Brazil

<sup>3</sup> Star Medica Morella, Morella, Mexico

### Abstract

Endometriosis is a complex disease characterized by the presence of endometrial-like tissue outside the uterine cavity. While commonly affecting the pelvic organs, extra pelvic endometriosis (EPE) is a rare but clinically significant condition that requires specialized surgical expertise. The estimated prevalence of EPE is approximately 12% of all endometriosis cases, with the diaphragm being the most common site, affecting 1-1.5% of patients with endometriosis. Less frequent locations include the spleen (<0.5% of cases), pancreas, and pericardium (extremely rare, with isolated case reports). This video article presents four cases of extra pelvic endometriosis, all of which were operated on by our multidisciplinary team: (1) splenic endometriosis requiring splenectomy, (2) diaphragmatic and pericardial endometriosis, (3) diaphragmatic endometriosis, and (4) a ten cm retroperitoneal endometriotic cyst posterior to the pancreas. The article highlights the necessity of a multidisciplinary surgical approach, including gynaecologists, colorectal surgeons, CT and HPB surgeons. Given the complexity of extra pelvic lesions, a surgeon with expertise in endometriosis is crucial for achieving complete excision while preserving organ function. Additionally, this article aims to demonstrate that, although infrequent, extra pelvic endometriosis exists and should be considered in the differential diagnosis when patients present with atypical symptoms. Mapping the disease according to symptoms is essential to achieving a comprehensive diagnosis of deep endometriosis.

This video article illustrates the complexity and surgical management of extra pelvic endometriosis (EPE) through four representative cases. It highlights the importance of clinical suspicion based on symptoms, strategic use of advanced imaging, and the fundamental role of a multidisciplinary team in achieving complete disease excision. Despite its rarity, EPE must always be considered in patients with cyclical symptoms in atypical locations.

### **Key words:**

Magnetic Resonance Imaging (MRI), Cardiothoracic (CT), Hepatopancreatobiliary (HPB), Gastrointestinal (GI), Ultrasound (US), Histopathological (HP), Multidisciplinary (MD), extra pelvic Endometriosis (EPE)

---

*Corresponding author: Lucia Chaul*

*DOI: 10.36205/trocar5.2025009*

*Received: 2025-04-20 – Accepted: 2025-04-25*

---

### **Introduction:**

Endometriosis affects approximately 10% of reproductive-aged women, with extra pelvic manifestations reported in up to 12% of cases. Among the most frequently described sites of extra pelvic endometriosis (EPE), diaphragmatic involvement accounts for 1–1.5%, whereas splenic, pancreatic, and pericardial locations are exceedingly rare. Due to its infrequency and wide spectrum of clinical presentations, EPE is frequently misdiagnosed or overlooked, often resulting in delays in appropriate treatment. Effective management of EPE requires a comprehensive surgical approach and the coordination of a multidisciplinary team to ensure both safe and complete disease excision. Crucially, accurate diagnosis depends not only on advanced imaging but also on a high index of clinical suspicion. In the absence of gynecologic symptoms, EPE may mimic other systemic conditions, and imaging studies are often only pursued when the treating physician is guided by a careful symptom-based evaluation.

This study highlights the importance of systematically considering extra pelvic manifestations in the diagnostic workup of patients with non-specific or cyclic symptoms in atypical anatomical regions. By integrating symptom-guided mapping and collaborative surgical planning, clinicians can move toward a more complete and timely diagnosis of deep endometriosis, including its extra pelvic forms.

### **Patients and Methods:**

All patients underwent standardized preoperative imaging, including:

- Transvaginal and abdominal ultrasound.
- MRI with extra pelvic extension.
- Postoperative histopathological confirmation
- Each surgery was performed by a high-complexity multidisciplinary team, including:
- Expert gynecologic endometriosis surgeons
- Colorectal surgeons

- Cardiothoracic surgeons (CT)
- Hepatopancreatobiliary (HPB) surgeons

### Case Presentations:

Case 1: A 34-year-old patient with splenic endometriosis presenting with cyclic left upper quadrant pain, dyspnoea, bloating, and anaemia. MRI with abdominal extension was performed, revealing a well-defined cystic lesion in the spleen with imaging characteristics consistent with endometriosis.

Case 2: A 40-year-old patient with diaphragmatic and pericardial endometriosis, presenting with cyclic chest pain. Initial transabdominal ultrasound revealed hyperechoic foci along the left diaphragmatic line. MRI confirmed left diaphragmatic involvement.

Case 3: A 36-year-old patient with diaphragmatic endometriosis, presenting with cyclic right upper quadrant pain, referred shoulder pain, and respiratory discomfort. Ultrasound examination showed hyperechoic foci along the diaphragmatic line. MRI confirmed the presence of diaphragmatic endometriotic lesions.

Case 4: A 38-year-old patient with a 10 cm retroperitoneal endometriotic cyst located posterior to the pancreas, initially suspected to be a pancreatic pseudocyst. The patient presented with epigastric pain, mainly when lying down, nausea, early satiety, and intermittent vomiting. MRI with abdominal extension was performed, revealing a well-circumscribed cystic lesion suggestive of endometriosis.

### Outcomes:

No intraoperative complications across cases  
Hospital discharge <72 hours in all patients

- Histological confirmation of EPE in all lesions

- Significant symptom improvement reported at 6-month follow-up
- No recurrence reported at latest follow-up

### Discussion:

EPE presents unique diagnostic and therapeutic challenges. The incidence of extra pelvic involvement varies, with the most affected sites being the diaphragm and gastrointestinal tract; while splenic, pancreatic, and pericardial endometriosis remain exceedingly rare. Complete surgical excision remains the gold standard for symptom relief and disease control, emphasizing the necessity for an endometriosis expert with a thorough understanding of both pelvic and extra pelvic disease manifestations.

A multidisciplinary approach is crucial, involving:

- Gynecologists specialized in endometriosis for overall disease assessment and pelvic management.
- Colorectal surgeons for bowel involvement.
- Cardiothoracic surgeons for thoracic endometriosis cases.
- Hepato-pancreatobiliary (HPB) surgeons for pancreatic and splenic cases.

The complexity of these cases underlines the need for a comprehensive surgical strategy tailored to the individual patient. Without expertise in extra pelvic endometriosis, incomplete excision or unnecessary radical procedures may compromise outcomes. Additionally, this study highlights the importance of symptom-based disease mapping. Given that EPE can mimic various pathologies, a structured approach to



diagnosis is essential. Patients with cyclical pain in atypical locations should undergo targeted imaging and evaluation for possible extra pelvic endometriosis. Without proper recognition of these symptoms and a multidisciplinary approach, many cases may remain undiagnosed or misdiagnosed.

### Conclusion:

Given the rarity and complexity of extra pelvic endometriosis (EPE), surgeons and gynaecologists specializing in endometriosis must expand their diagnostic and surgical expertise beyond the confines of the pelvis to ensure optimal patient outcomes. Successful management requires not only technical proficiency but also the integration of a multidisciplinary team - including colorectal, hepatopancreatobiliary, and cardiothoracic surgeons - aligned according to the specific anatomical involvement. Accurate diagnosis depends on symptom-guided evaluation rather than incidental imaging findings. In patients presenting with cyclic pain in non-pelvic locations, a deliberate and structured approach to clinical mapping is essential. Without it, EPE may go undetected or be misattributed to other pathologies, delaying appropriate treatment. This video article serves as a call to heightened clinical awareness and multidisciplinary collaboration. By recognizing atypical symptom patterns, applying targeted imaging strategies, and engaging expert surgical teams, healthcare professionals can significantly improve diagnostic accuracy, surgical outcomes, and long-term quality of life for women affected by extra pelvic endometriosis.

### References:

1.Vigueras Smith A, Cabrera Carranco R, Kondo W, Ferreira H. Diaphragmatic endometriosis minimally invasive treatment: a feasible and effective approach. *J Obstet*

*Gynaecol.*2020;40(2):1-11.:10.1080/01443615.2019.1702934.

2.Jubanyik KJ, Comite F. Extra pelvic endometriosis. *Obstet Gynecol Clin North Am.*1997;24(2):411–40.  
<https://pmc.ncbi.nlm.nih.gov/articles/PMC7542014>

3.Ceccaroni M, Clarizia R, Bruni F, Ruffo G, Scioscia M, Minelli L. Surgical treatment of diaphragmatic endometriosis: 6-year experience.*JMIG.*2019;26(7):1257–1266.[https://www.jmig.org/article/S1553-4650\(19\)31256-7/abstract](https://www.jmig.org/article/S1553-4650(19)31256-7/abstract)

3.Gupta R, Narayan S, Rajesh S. Extra pelvic endometriosis: a rare entity. *J South Asian Feder Obst Gynae.* 2017;9(2):149–154.  
<https://www.jsafog.com/doi/pdf/10.5005/j-p-journals-10006-1168>

4.Horton JD, Dezee KJ, Ahnfeldt EP, Wagner M. Abdominal wall endometriosis: a surgeon's perspective and review of 445 cases. *Am J Surg.*2008;196(2):207–212.  
<https://pubmed.ncbi.nlm.nih.gov/31618674>

5.Ceccaroni M, Roviglione G, Malzoni M, Petrillo M, Scioscia M, Minelli L. Total laparoscopic treatment of diaphragmatic endometriosis: technique, feasibility, and safety. *JMIG* 2020;27(2):353–354.  
<https://pubmed.ncbi.nlm.nih.gov/32053018>

6.Nezhat C, Lindheim SR, Backhus L, Vu M, Vang N, Nezhat C. Thoracic endometriosis syndrome: a review of diagnosis and management. *JOGC.* 2016;38(5):452–460.  
[https://www.jogc.com/article/S0849-5831\(16\)31411-2/](https://www.jogc.com/article/S0849-5831(16)31411-2/)

## Ureteroneocystostomy in a case of deep infiltrating endometriosis (Case report + Video)

Author: Hemant Kanojiya <sup>1</sup>, Mukulika Sharma <sup>1</sup>

Affiliation: <sup>1</sup> Gynaecological Endoscopy Unit Excell Endocare, Mumbai, India

### Abstract

Endometriosis is a gynecological condition characterized by ectopic implantation of endometrium-like tissue. While pelvic endometriosis is a common variety, in certain rare cases urinary tract involvement may be coexistent, especially in cases of deep infiltrating endometriosis. The clinical picture may vary from asymptomatic presentation to hematuria to renal failure arising from obstruction of the ureter. Here a surgical demonstration of laparoscopic ureteral reimplantation is demonstrated in a case of deep infiltrating endometriosis with silent right sided hydroureteronephrosis

**Key words:** Deep endometriosis, ureteral endometriosis, ureteral reimplantation, ureteroneocystostomy, hydroureteronephrosis

*Corresponding author: Mukulika Sharma*

*DOI: 10.36205/trocar5.2025010*

*Received: 2025-02-18 – Accepted: 2025-03-30*

### Introduction:

Endometriosis is a common, benign gynecological disease affecting about 10% of the females in the reproductive age group (1). Even though endometriosis foci are benign, these are characterized by an aggressive and infiltrating growth (2). Urinary tract involvement is a very rare but serious form of

infiltrating endometriosis because of the risk of urinary tract obstruction and loss of renal function (3).

### Case report:

The case of a 40-year-old female with history of one caesarean section is presented. The patient had complaints of severe

dysmenorrhea and chronic pelvic pain for past two years which was non-responsive to medical management, including a levonorgestrel intrauterine device. She had no bowel or bladder disturbances. Sonography incidentally detected a bladder nodule at the vesico-ureteric junction (VUJ) with gross right sided hydroureter with likely a neoplastic origin. Magnetic resonance imaging (MRI) confirmed the lesion as an endometriotic implant with a Grade 3 right sided hydroureter. Pre-operative cystourethroscopy displayed a bladder mucosal nodule in close proximity to the right ureteral orifice. The patient underwent a total laparoscopic hysterectomy with right sided salpingo-oophorectomy with excision of pelvic endometriotic implants followed by a cystotomy and excision of the nodule involving the right VUJ and terminal two cm of the ureter and the creation of a ureteroneocystostomy. Anteriorly, the nodule did obliterate the Yabuki space penetrating deep up to the bladder mucosa (as confirmed by cystoscopy). The right ureter was grossly dilated. Laterally, the nodule was in close proximity to the internal iliac artery. The ureter was dissected from its normal location at the pelvic brim up to the diseased area. The entire nodule with the involved parametrium was removed by meticulous dissection. An ureteroneocystostomy could be performed by direct ureteral reimplantation and a psoas hitch procedure was not required as a tension free anastomosed could be achieved due to the adequate mobilization of the bladder and the ureter. After four days of post-operative monitoring, the patient was discharged with a zero-pain score. At three month follow up, sonography showed resolution of hydroureter with no urinary complaints and repeat cystourethroscopy displayed a patent and functional reimplanted ureteric orifice. This is a unique case of ureteral endometriosis with the endometriotic nodule

infiltrating at the right vesico-ureteric junction. It required excision of the right sided vesico-ureteric junction and terminal portion of ureter affected by intrinsic endometriosis and reconstruction of bladder with ureteroneocystostomy.

### Discussion:

An estimated 0.3 to 12% of women diagnosed with endometriosis also have urinary tract involvement (2). Around 50% of women with urinary tract endometriosis may be asymptomatic (4), which can lead to silent death of the kidney. Hence, it is imperative to perform sonographic monitoring and MRI guided mapping of endometriotic implants including the urinary tract. Early diagnosis and appropriate treatment will prevent complications such as hydroureter, hydronephrosis and eventual loss of renal function (5). MRI is very useful for guiding laparoscopy, and allows for the adequate evaluation of the location, size, and sub peritoneal lesion extension of deep pelvic endometriosis, providing key information for both the diagnosis and treatment planning (6). Surgical excision of the endometriotic nodules and restoration of anatomy is necessary. The surgical approach varies depending on the site and extent of bladder or ureteral involvement. Ureterolysis alone is indicated for minimal, extrinsic, non-obstructive ureteral endometriosis (7). In cases of obstructive ureteral endometriosis, surgical intervention may vary as a segmental excision and end-to-end anastomoses or a ureteroneocystostomy with or without a bladder-psoas hitch procedure or a complete uretectomy.

A pre-operative cystourethroscopy can be performed to confirm the location of a bladder nodule, if detected on sonography or MRI. If the distance between the edge of the endometriotic lesion and the inter-ureteric ridge is less than two cm, an

ureteroneocystostomy is typically performed in order to reduce the risk of ureteral obstruction and fistula formation (8). An efficient surgical plan tailor-made to the patient's diagnosis and extent of the disease with a meticulous surgical implementation can provide an optimal therapeutic outcome.

### Conclusion:

Endometriosis is a complex disease that challenges a gynecologist. Due to its varied presentation, we must be vigilant for urinary tract endometriosis especially in females with silent hydronephrosis. An appropriate treatment plan and the surgeon's expertise play a pivotal role in achieving a good clinical outcome in such rare cases of infiltrating endometriosis.

### Abbreviations:

VUJ- Vesico-ureteric junction

MRI- Magnetic resonance imaging

### References:

1. Leone Roberti Maggiore U, Chiappa V, Ceccaroni M, et al. Epidemiology of infertility in women with endometriosis. *Best Pract Res Clin Obstet Gynaecol.* 2024;92:102454. doi:10.1016/j.bpobgyn.2023.102454.
2. Tchartchian G, Fabricius PG, Bojahr B, De Wilde RL. Laparoscopic Ureteral Reimplantation in Endometriosis: A Severe Case. *Surg J (N Y).* 2017;3(4):e167-e173. Published 2017 Nov 27. doi:10.1055/s-0037-1607296.
3. Trigui M, Ouanes Y, Chaker K, Zehani A, Chelly I, Nouira Y. Bladder endometriosis: A serious disease. *Urol Case Rep.* 2023;48:102400. Published 2023 Apr 11. doi:10.1016/j.eucr.2023.102400.
4. Seracchioli R, Mabrouk M, Montanari G, Manuzzi L, Concetti S, Venturoli S. Conservative laparoscopic management of urinary tract endometriosis (UTE): surgical outcome and long-term follow-up. *Fertil Steril.* 2010;94(3):856-861. doi:10.1016/j.fertnstert.2009.04.019.
5. Leonardi M, Espada M, Kho RM, et al. Endometriosis and the Urinary Tract: From Diagnosis to Surgical Treatment. *Diagnostics (Basel).* 2020;10(10):771. Published 2020 Sep 30. doi:10.3390/diagnostics10100771.
6. Di Dier K, De Backer A. Deep Pelvic Endometriosis. *J Belg Soc Radiol.* 2021;105(1):44. Published 2021 Sep 14. doi:10.5334/jbsr.2533.
7. Barra F, Scala C, Biscaldi E, et al. Ureteral endometriosis: a systematic review of epidemiology, pathogenesis, diagnosis, treatment, risk of malignant transformation and fertility. *Hum Reprod Update.* 2018;24(6):710-730. doi:10.1093/humupd/dmy027.
8. Berlanda N, Vercellini P, Carmignani L, Aimi G, Amicarelli F, Fedele L. Ureteral and vesical endometriosis. Two different clinical entities sharing the same pathogenesis. *Obstet Gynecol Surv.* 2009;64(12):830-842. doi:10.1097/OGX.obo13e3181c4bc3a.

## A Minimally Invasive Retroperitoneal Approach to Apical Compartment Prolapse Repair via vNOTES Sacral Fixation (Video)

Author: Rüdiger Klapdor<sup>1</sup>, Julian Dittmann<sup>1</sup>, Dorothea Lewitz<sup>1</sup>, Sami Shihada<sup>1</sup>

Affiliation: <sup>1</sup> Department of Gynecology and Obstetrics, Albertinen Krankenhaus  
Hamburg, Germany

### Abstract

#### Objective:

To demonstrate a minimally invasive technique for apical compartment prolapse repair using a vaginal retroperitoneal approach for sacral fixation.

#### Design:

Step-by-step surgical demonstration, accompanied by detailed descriptions of each procedural step.

**Key words:** Laparoscopy, vNOTES, Retroperitoneal, Urogynecology, Gynecologic Operations

---

*Corresponding author: Rüdiger Klapdor*

*DOI: 10.36205/trocar6.vid25005*

*Received: 2025-03-28 – Accepted: 2025-04-18*

---

### Introduction and setting:

While several minimally invasive techniques have been established for prolapse repair, sacral suspension remains the gold standard due to its anatomical correct fixation and

high success rates. Vaginal approaches are associated with faster recovery and reduced postoperative pain. However, standard vaginal surgery offers limited access to the sacral promontory.



Vaginal Natural Orifice Transluminal Endoscopic Surgery (vNOTES) expands surgical possibilities by allowing access to the sacrum via the vaginal route. In this technique, vNOTES is utilized to perform a sacral fixation through a retroperitoneal corridor, minimizing blood loss and avoiding intraabdominal manipulation. It is a mesh-free procedure and uses sutures for apical fixation. A retroperitoneal promontofixation using vNOTES was previously described by Baekelandt et al (1). They performed a complete para and retro rectal dissection and combined apical fixation with a Manchester-Fothergill procedure. In this video we used a direct approach to the os sacrum with minimal dissection. Results of a vaginal sacropexy using a monofilament suture was described in 2017 showing promising results. vNOTES facilitates the access significantly.

### **Surgical Steps:**

1. Posterior colpotomy (2-3cm) and right pararectal space dissection
2. Insertion of the vPATH (7 cm) port (Applied medical, Rancho Santa Margarita, CA, USA)
3. Laparoscopic identification of key anatomical landmarks
4. Placement of a non-absorbable suture (Maprolene 1, Catgut, Markneukirchen, Germany) into the anterior longitudinal ligament
5. Suture fixation to the posterior cervix
6. Extracorporeal knot tying and closure of the vaginal incision

### **Conclusion:**

This retroperitoneal vNOTES approach enables anatomically correct, minimally invasive prolapse repair of the central compartment. It combines the benefits of

sacral fixation with the advantages of a vaginal route, including reduced postoperative morbidity and expedited recovery. Further comparative studies are needed to evaluate long term results of this procedure.

### **References:**

1. Baekelandt J, Stuart A. Old meets new: vNOTES retroperitoneal promontory fixation in conjunction with the uterus preserving Manchester procedure. *J Gynecol Obstet Hum Reprod.* 2023 Oct;52(8):102628. doi: 10.1016/j.jogoh.2023.102628. Epub 2023 Jul. 5. PMID: 37419184.
2. Klapdor R, Grosse J, Hertel B, Hillemanns P, Hertel H. Postoperative anatomic and quality-of-life outcomes after vaginal sacrocolporectopexy for vaginal vault prolapse. *Int J Gynaecol Obstet.* 2017 Apr;137(1):86-91. doi: 10.1002/ijgo.12095. Epub 2017 Feb 2. PMID: 28099751.

## Parametrectomy and discoid resection for deep endometriosis of the medial and posterior compartments using the reverse technique (Video)

**Author:** Jhanneth Jhovanna Chura Paco<sup>1</sup>, Ramiro Cabrera<sup>2</sup>, Lucia Chaul<sup>2</sup>, Alvaro J Ovando<sup>1</sup>, Armando Menocal<sup>1</sup>, William Kondo<sup>3</sup>.

**Affiliation:**

- <sup>1</sup> Gynecological Endoscopic Service, Morelia Womens Hospital, México
- <sup>2</sup> Female Pelvic Surgery Department, Doyenne High Quality and Multidisciplinary Treatment Center for Endometriosis, Mexico City, Mexico
- <sup>3</sup> Hospital Medical Center Sugisawa, Curitiba, Brazil

### Abstract

Deep endometriosis located in the middle and posterior compartments involves the parametrium, which contains nerve structures, uterine vessels, and the ureter. Therefore, a preoperative evaluation and endometriosis mapping are imperative. The parametrectomy and discoid resection technique for deep endometriosis, performed using the reverse technique in a 37-year-old patient without reproductive desire, allows for a systematic approach with the preservation of critical structures. The use of fluorescence minimizes postoperative complications and provides Good surgical outcomes.

For many years, surgical techniques have been the subject of study in cases of deep infiltrative endometriosis affecting the medial and posterior compartments, due to the various structures involved and the dysfunctions that may arise after excisional procedures. As a result, endometriosis surgery has evolved toward the preservation and identification of critical structures.

**Key words:** Deep Endometriosis (DE), Parametrectomy, #Enzian, Fluorescence, Dyspareunia.

### Learning Objective:

Implement surgical strategies in parametrectomy for deep endometriosis, focusing on neurovascular preservation, identification of critical structures, and prevention of postoperative complications.

## **Introduction:**

Endometriosis is defined as the presence of ectopic endometrial glands and stroma, or the resulting fibrosis, infiltrating the peritoneum by at least five mm (1). Among the most frequent locations associated with debilitating pain, pelvic organ dysfunction, and reduced quality of life is the dorsolateral parametrium, due to its anatomical relationship with the neuro-pelvis (2).

The lateral parametrium can be defined as an area connective tissue composed of areolar tissue that surrounds the visceral branches of the hypogastric vessels as they travel toward the uterus and vagina (3).

The lower hypogastric plexus is formed by a multitude of splanchnic nerves originating from the sacral plexus, the sympathetic trunk, and the lower hypogastric nerve. During the evolution of endometriosis surgery, numerous postoperative neurogenic disorders were described, which led to the shift toward preserving nerve structures to date (4). Endometriosis affecting the parametrium can extrinsically affect the ureter, being clinically asymptomatic in up 30% of patients, or it may be associated with non-specific symptoms. However, in a minority of cases, progressive upper urinary tract obstruction leads to asymptomatic renal function loss due to progressive extrinsic compression of the ureteral wall by the endometrial tissue (5).

The parametria can be considered the “neurological electrical unit” of the pelvic viscera. The formation of the pelvic plexus

arises from sacral roots S2-S3-S4. Through the union of the pelvic splanchnic nerves and the hypogastric nerves. The preservation of the fibers can prevent pelvic floor dysfunctions (6).

In relation to the anatomical classification of parametrectomy, deep parametrectomy type 1 (DP1) is located medial to the presacral fascia and cranial to the middle rectal artery. Deep parametrectomy type 2 (DP2) is caudal to the middle rectal artery, and deep parametrectomy type 3 (DP3) is lateral to the hypogastric fascia (7).

## **Patient and Methods**

The case of 37-years-old patient, Gravida 1, Para1, with a clinical history of chronic pelvic pain, dyspareunia, dysmenorrhea, and dyschezia is presented. Endometriosis mapping was performed using MRI to assess lesions in the lateral and posterior compartments due to the clinical symptoms. Significant findings included:

Diffuse posterior uterine adenomyosis, a 3,4 cm adenomyoma, a 38x27 mm retro cervical nodule with extension to the uterine torus and posterior vaginal fornix retraction. An endometriotic lesion of 26 mm on the anterior wall of the rectum with involvement of the muscular layer. #ENZIAN v2021: Po, O 1/2, T 3/3, A1, B2/3, C2 FA (Fig 1-2)

The patient gave consent for scientific publication of this video, contributing to the scientific literature and surgical advancement.

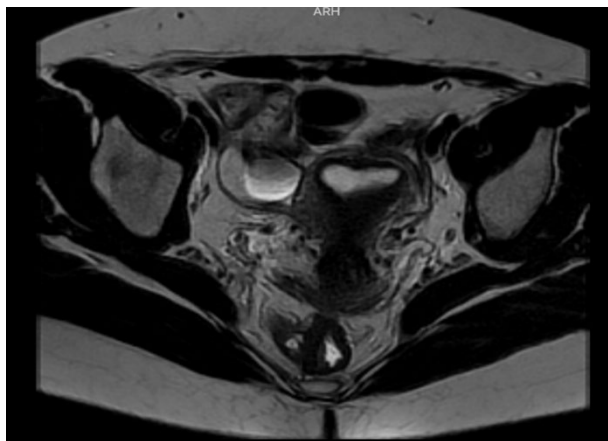


Figure 1. Retraction of the uterosacral ligaments due to an endometriosis nodule in the medial compartment of the pelvis.

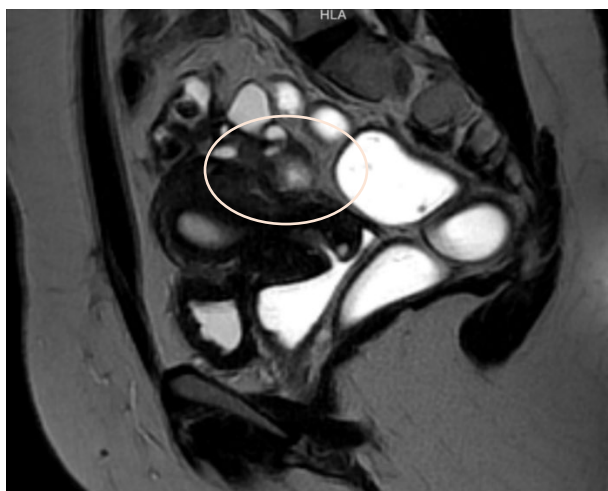


Figure 2. Rectal nodule composed of adhesive bands affecting up to the muscular serosa 12 cm from the anal margin.

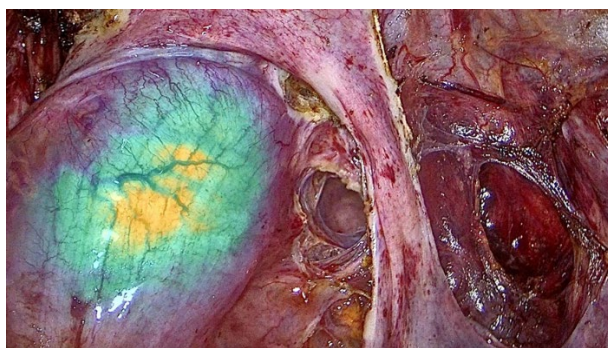

Figure 3. Rectal mobilizer with fluorescence.

### Surgical Technique:

Under general anesthesia, the patient is placed in the Lloyd-Davies position. Cystoscopy is performed with the insertion of an open-end ureteral catheter, through which fluorescent solution is injected. A trans umbilical incision is made for the insertion of a 10 mm main trocar, and pneumoperitoneum is established at 12 mmHg. Accessory five mm trocars are placed in the right iliac fossa and the left suprapubic area. A 30 degrees laparoscope is used to perform a panoramic inspection of the abdominopelvic cavity.

Findings: The uterus is adherent to the anterior rectal wall via the mesorectum. The ovaries are adherent to the posterior uterine wall, with the presence of the “kissing ovaries” sign. The right ureter is adherent to an ipsilateral parametrial implant. Both ureters are visualized using the fluorescence filter system.

Using ultrasonic and bipolar energy, pelvic peritonectomy is performed from lateral to medial, following the reverse technique. This includes bilateral transection of the round ligaments, and dissection of the vesico-uterine space as well as the bilateral medial para-vesical spaces. The anterior leaf of the broad ligament is dissected to identify the two Latzko spaces, followed by visualization of the origin of the two uterine arteries, the obliterated umbilical artery, and the superior vesical vessels. The mesorectum adherent to the posterior uterine wall is dissected until the rectovaginal septum is reached, free of endometriotic involvement. The Okabayashi space is dissected bilaterally to preserve the neural structures of the inferior hypogastric plexus, until the left margin of the rectovaginal septum is identified. The right parametrium is dissected, revealing an extensive periureteral endometriotic nodule measuring approximately two- three cm.

This is excised using ultrasonic energy, followed by ureterolysis.

The dissection of the mesorectum continues, and an anterior colpotomy is performed until the rectovaginal septum is exposed. The rectovaginal nodule is dissected, and the posterior colpotomy is completed.

The surgical specimen is extracted vaginally. The rectal nodule is identified with a suture marker placed 12 cm from the anal verge. A circumferential mesorectal dissection is performed, and a discoid resection is carried out using a 29 mm circular stapler. Reinforcement sutures are placed on the intestinal serosa with 3-0 Monocryl, and intestinal perfusion is confirmed via fluorescence. A pneumatic leak test confirms the absence of leakage. Finally, vaginal cuff closure is performed with 1 Vicryl™ suture.

The total surgical time for parametrectomy and discoid resection for deep endometriosis in the medial and posterior compartments, combined with hysterectomy using the reverse technique, was 99 minutes. During the procedure, advanced technology was employed to identify and preserve structures such as the ureters, which were compromised by bilateral parametrial nodules.

### **Discussion:**

The importance of preserving neural structures has evolved over the years in the surgical management of deep endometriosis, as numerous cases of pelvic floor dysfunction have been reported in postoperative patients with endometriosis involving the lateral and posterior compartments. For this reason, nerve preservation may help prevent bladder and rectal dysfunction and reduce the risk of diminished vaginal lubrication and arousal in women. Several studies have evaluated the causes of pelvic floor dysfunction after surgery for endometriosis. Consequently,

surgical approaches to lesions in the lateral and posterior compartments have become a critical point of investigation. Although endometriosis is a benign disease, it affects multiple structures and organs. Therefore, modern surgical approaches must aim to preserve critical structures such as nerves and/or vessels of adjacent organs to avoid future complications (12).

The main difference between conventional endometriosis surgery and the reverse technique lies in the approach to the lesion: the reverse technique begins dissection from healthy peripheral tissue toward the lesion, allowing the surgical team better visualization of key neurovascular structures. Given the pathophysiology of the disease - with its strong neurovascular affinity and tendency to infiltrate surrounding structures, along with anatomical distortion and fibrotic inflammatory changes - this approach has shown reduced intraoperative risks and improved postoperative recovery (8,9,10,11).

The total surgical time for parametrectomy and discoid resection for deep endometriosis in the medial and posterior compartments, combined with hysterectomy using the reverse technique, was 99 minutes. During the procedure, advanced technology was employed to identify and preserve structures such as the ureters, which were compromised by bilateral parametrial nodules (11,13).

Minimally invasive surgery today offers greater safety, especially with the use of fluorescence to identify vital structures and/or confirm adequate vascular perfusion in cases of intestinal involvement requiring segmental resection (14).

A thorough preoperative evaluation with endometriosis mapping is essential, as it provides the pelvic surgeon with a comprehensive view of the affected sites and helps define the surgical strategy - such as the



use of fluorescence to identify critical structures and verify intraoperative vascular flow. In addition, the use of a rectal mobilizer with fluorescence helps delineate the exact location of the rectal nodule with greater precision Fig 3. (14).

The reverse surgical technique enhances surgical access, and its systematic steps make it a reproducible method.

### Conclusion:

Endometriosis surgery with parametrectomy and identification of critical points using technological support minimizes postoperative complications. This likely standardised, step-by-step technique standardises the procedure and indirectly reduces surgical times, thus favouring the procedure and ultimately leading to better outcomes for patients.

### References:

1. Ianieri MM, Mautone D, Ceccaroni M. Recurrence in Deep Infiltrating Endometriosis: A Systematic Review of the Literature. *J Minim Invasive Gynecol. JMIG*. 2018 Jul-Aug; 25 (5) : 786-793. doi: 10.1016/j.jmig.2017.12.025.
2. Ianieri MM, Raimondo D, Rosati A, Cocchi L, Trozzi R, Maletta M, Raffone A, Campolo F, Beneduce G, Mollo A, Casadio P, Raimondo I, Seracchioli R, Scambia G. Impact of nerve sparing posterolateral parametrial excision for deep infiltrating endometriosis on postoperative bowel, urinary, and sexual function. *Int J Gynaecol Obstet*. 2022; 159(1): 152 - 159. doi: 10.1002/ijgo.14089. Epub 2022 Jan 20.
3. Mabrouk M, Raimondo D, Arena A, Iodice R, Altieri M, Sutherland N, Salucci P, Moro E, Seracchioli R. Parametrial Endometriosis: The Occult Condition that Makes the Hard Harder. *J Minim Invasive Gynecol*. 2019 Jul-Aug; 26(5):871-876. doi: 10.1016/j.jmig.2018.08.022.
4. Possover M. Pathophysiologic explanation for bladder retention in patients after laparoscopic surgery for deeply infiltrating rectovaginal and/or parametric endometriosis. *Fertil Steril*. 2014 Mar; 101(3):754-8. doi: 10.1016/j.fertnstert.2013.12.019. Epub 2014 Jan 11. PMID: 24424366.
5. Barra F, Scala C, Biscaldi E, Vellone VG, Ceccaroni M, Terrone C, Ferrero S. Ureteral endometriosis: a systematic review of epidemiology, pathogenesis, diagnosis, treatment, risk of malignant transformation and fertility. *Hum Reprod Update*. 2018 Nov 1; 24(6):710-730. doi: 10.1093/humupd/dmy027. PMID: 30165449.
6. Ceccaroni M, Clarizia R, Roviglione G, Ruffo G. Neuro-anatomy of the posterior parametrium and surgical considerations for a nerve-sparing approach in radical pelvic surgery. *Surg Endosc*. 2013 Nov; 27(11):4386-94. doi: 10.1007/s00464-013-3043-z. Epub 2013 Jun 20. PMID: 23783554.
7. Ianieri MM, Alesi MV, Querleu D, Ercoli A, Chiantera V, Carcagnì A, Campolo F, Greco P, Scambia G. Anatomical-based classification of dorsolateral parametrectomy for deep endometriosis. Correlation with surgical complications and functional outcomes: A single-center prospective study. *Int J Gynaecol Obstet*. 2024 Dec; 167(3):1043-1054. doi: 10.1002/ijgo.15781. Epub 2024 Jul 19. PMID: 39031095.
8. Kondo W, Bourdel N, Jardon K, Tamburro S, Cavoli D, Matsuzaki S, Botchorishvili R, Rabischong B, Pouly JL, Mage G, Canis M. Comparison between standard and reverse laparoscopic techniques for rectovaginal

endometriosis. *Surg Endosc.* 2011 Aug;25(8):2711-7. doi: 10.1007/s00464-011-1635-z. Epub 2011 Mar 18. PMID: 21424199.

9. Kondo W, Ribeiro R, Zomer MT, Hayashi R. Laparoscopic Double Discoid Resection with a Circular Stapler for Bowel Endometriosis. *J Minim Invasive Gynecol.* 2015 Sep-Oct;22(6):929-31. doi: 10.1016/j.jmig.2015.04.021. Epub 2015 Apr 29. PMID: 25937595.

10. Kondo W., & De Nadai, L. Advanced reverse technique in laparoscopic excision of severe bowel endometriosis. *Fertil Steril.* 2019; 112(4): e239–e240.

11. Cabrera R, Tessmann Zomer M, Larrain D, Bourdel N, Canis M, Kondo W. Laparoscopic Reverse Technique for Posterior Rectovaginal Deep Endometriosis Nodule Step by Step. *J Minim Invasive Gynecol.* 2020 Mar-Apr;27(3):577-578. doi: 10.1016/j.jmig.2019.07.018. Epub 2019 Jul 25. PMID: 31352071.

12. Ceccaroni M, Clarizia R, Bruni F, D'Urso E, Gagliardi ML, Roviglione G, Minelli L, ert.2021.03.014. Epub 2021 Apr 8.

PMID: 33840452.4. Ruffo G. Nerve-sparing laparoscopic eradication of deep endometriosis with segmental rectal and parametrial resection: the Negrar method. A single-center, prospective, clinical trial. *Surg Endosc.* 2012 Jul;26(7):2029-45. doi: 10.1007/s00464-012-2153-3. Epub 2012 Jan 26. PMID: 22278102.

13. Benoit L, Dabi Y, Bazot M, Thomassin-Naggara I, Ferrier C, Puchar A, Owen C, Touboul C, Darai E, Bendifallah S. Parametrial endometriosis: A predictive and prognostic factor for voiding dysfunction and complications. *Eur J Obstet Gynecol Reprod Biol.* 2022 Sep; 276:236-243. doi: 10.1016/j.ejogrb.2022.07.035. Epub 2022 Aug 4. PMID: 35961258.

14. Kanno K, Aiko K, Yanai S, Sawada M, Sakate S, Andou M. Clinical use of indocyanine green during nerve-sparing surgery for deep endometriosis. *Fertil Steril.* 2021 Jul;116(1):269-271. doi: 10.1016/j.fertnst

## Spontaneous Rupture of an Unscarred Uterus at 34 Weeks of Pregnancy (Video – case report)

Author: Meenu Agarwal<sup>1</sup>, Paulomi Patra<sup>1</sup>, Anuja Pingale<sup>1</sup>

Affiliation: <sup>1</sup> Department of Obstetrics and Gynecology, Ruby Hall, Pune India

### Abstract

Uterine rupture is a rare life-threatening obstetric emergency associated with poor fetal and maternal outcome, hence needs emergency surgery and prompt management. It is usually associated in cases that have history of trauma, prolonged induction or augmentation of labor, obstructed labor. Surgical history predisposing to uterine rupture includes caesarean section, myomectomy, hysteroscopy with unrecognized uterine perforation, or history of abortions.

In the presented case the patient was 34 weeks pregnant, G2P1, Previous obstetrical history: full term normal vaginal birth, no previous surgeries, no medical disorders. She was not in labor. On arrival she was in constant pain and giddiness without any episode of per vaginal bleeding, with absent fetal heart sounds. On vaginal examination the cervical os was closed with no effacement. Though the first impression was HELPP Syndrome as the ultrasound examination (US) showed ascites but in view of normal blood pressure (BP) and tachycardia a suspicion of hemoperitoneum or unrevealed injury was thought of and a computed tomography (CT) was asked for. A provisional diagnosis of uterine rupture was made as the CT showed irregular uterine wall margins with extravasation of contrast dye and hemoperitoneum, associated with a drastic fall in hemoglobin levels. She was immediately shifted to operation theatre, laparotomy was performed, uterine defect sutured, blood and blood products transfused intra-op, successfully preserving her uterus.

**Key words:** Uterine rupture, preserving uterus

---

*Corresponding author: Meenu Agarwal*

*DOI: 10.36205/trocar6.vid25007*

*Received: 2025-03-09 – Accepted: 2025-03-24*

---

### Case Report:

Mrs. A P, 24 yrs old lady 2nd gravida, resident of Satara, who was in her 34th. week of pregnancy with obstetric history of singleton vaginal delivery three years back and no other past surgical history (unscarred uterus) was admitted with acute onset of abdominal pain and multiple vomiting episodes in the emergency ward. Initially she was admitted in local hospital with similar complaints, managed conservatively, and then referred to our hospital for better management. On admission she had moderate pallor, blood pressure (BP) 98/60 and Pulse 154/min. On examination the uterus was mildly tense and per vaginal examination closed os. Sonography was done, that revealed an Intra Uterine Fetal Death (IUFD) along with moderate ascites and hetero-echoic collection along left anterolateral upper abdominal wall suggestive of hematoma. A day prior, a sonography was. done at outside the hospital, revealed normal fetal parameters for 34 weeks of pregnancy. Though it was a confusing diagnosis as the first thing to come to mind was an HELPP Syndrome, but she had tachycardia and the BP was normal with normal Liver function tests. This raised a suspicion of active internal bleeding and hence a CT scan of the abdomen and the pelvis was done urgently, the report did reveal an irregular left lateral wall of the uterus with extravasation of I.V contrast, with significant hemoperitoneum, raising the suspicion of a ruptured uterus. There was also a significant drop of Hemoglobin from 8.4 (a day prior) to 5.5 (on admission). Hence after proper counselling and taking due consent for a probable need to perform a hysterectomy, an emergency laparotomy was performed under General Anesthesia. The Hemoperitoneum was confirmed, around 2000 ml blood was suctioned out. A fresh stillborn male fetus of 2.1 kg was delivered by

transverse incision Cesarean Section (LSCS). The uterus was found to have a large tear involving all three layers along the left posterolateral wall with irregular margins. 10x10 cm large blood clot was seen posterior to the tear. Few laceration marks were also seen along the posterior wall. Two-pints of Packed Cell Volume (PCV) were transfused intraoperatively. The ruptured site was sutured by vicryl 1-0 in 2 layers, along with the LSCS incision site. The uterus was well contracted and could be preserved. Post operatively the patient was vitally stable, monitored in ward, discharged on Post Operative Day (POD) five. Her follow up period was also uneventful.

Video clip demonstrating the amount of blood loss and active bleeding from the post lateral wall leading to a large blood clot in the contained post retroperitoneal space and hemoperitoneum.

### Discussion:

Uterine rupture in an unscarred uterus is highly unexpected and thus often the diagnosis gets delayed and missed at times. The patient is considered a low-risk case and hemorrhage is unrevealed since blood gets collected intra-peritoneally through the tear. The condition is usually associated with cases that have a history of trauma, prolonged induction or stimulation of labor, or over stretching of uterine wall in obstructed labor, contracted pelvis or in malpresentations. Surgical history predisposing to uterine rupture includes CS, myomectomy, hysteroscopy with unrecognized uterine perforation, a history of abortions followed by Dilatation and Curettage (D&C) or a history of instrumental vaginal deliveries in the past, to enumerate a few. In the case presented no such associated factors could be identified, thus giving us a false sense of security. However prompt actions were initiated by the team, saving the mother's life

and conserving the uterus. The patient was discharged on POD five in a vitally stable condition. Her follow up period was uneventful.

### **Conclusion:**

A pregnancy following a CS or myomectomy gets a better care and surveillance as compared to that after an uneventful vaginal birth. The rupture of an unscarred uterus causes significantly more maternal and neonatal morbidity than the rupture of a scarred uterus. Most ruptures involving unscarred uteri can be traced to one of the following etiologies: (1) trauma, (2) a genetic disorder associated with uterine wall weakness, (3) a prolonged induction or augmentation of labor, or (4) overstretching of the uterine wall. However, in this case no risk factor could be suspected that could lead to such an outcome. Hence each pregnancy

should be treated with utmost attention and care, any episode of acute onset of severe abdominal pain with diffuse tenderness in the abdomen or loss of perception of fetal movements should not be ignored, all these symptoms together should raise the suspicion of a concealed uterine rupture.

### **References:**

- 1.Nkwabong E., Kouam L., Takang W. spontaneous uterine rupture during pregnancy: case report and review of literature. African Journal of Reproductive Health. August. 2007;11(2)
- 2.Albrecht K, Lam G. Preterm spontaneous uterine rupture in a Non-labouring Grand Multipara: A case report. J Obstet Gynaecol Can. 2008;30(7):586–89. doi: 10.1016/S1701-2163(16)32892-4.



## A Novel Hysteroscopic Approach for FIGO Type 2 Submucosal Leiomyomas (new approach)

Author: Xiaoming Gong<sup>1</sup>

Affiliation: <sup>1</sup> Woyi ObGyn Medical Group China

### Abstract

The author presents a so far non evaluated procedure assisting hysteroscopic myoma resection introducing a drill for traction.

**Key words:** hysteroscopy, drill, experimental approach

---

*Corresponding author: Xiaoming Gong DOI:*

*10.36205/trocar6.2025011*

*Received: 2025-03-18 – Accepted: 2025-04-04*

---

For FIGO type 2 submucosal leiomyomas, traditional hysteroscopic resection techniques pose significant challenges due to the deep myometrial embedment of the tumors, which increases the difficulty of resection compared to type 0 or 1 leiomyomas. Large type 2 tumors further elevate risks of complications such as water intoxication, uterine perforation, or incomplete resection.

To address these challenges, a specialized hysteroscopic myoma drill inspired by laparoscopic myoma drills was developed. Unlike laparoscopic counterparts, this device retains only the drill head and incorporates a flat grip and threading aperture at the tail end (Figure 1).



Figure 1. Specially designed hysteroscopic myoma drill.

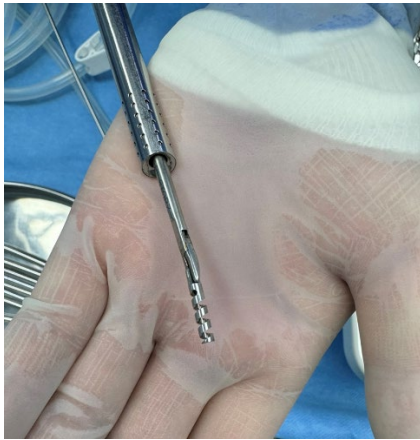

Figure 2. A 3mm needle holder grasping the myoma drill via the cold-knife hysteroscope

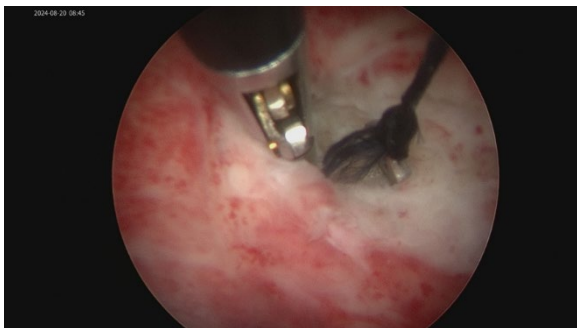

Figure 3. Anchoring and traction of the leiomyoma using the myoma drill.

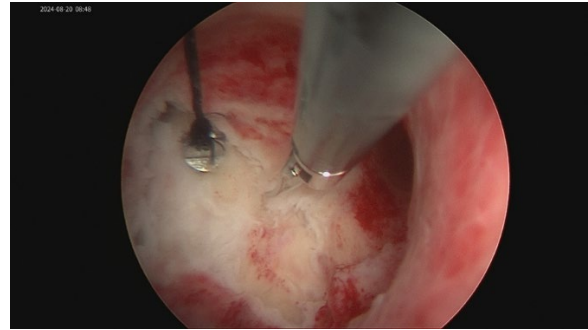


Figure 4. Dissection of the leiomyoma with scissors or forceps following traction. Surgical Technique:

1. Anchor Placement: A 7-0 silk suture is threaded through the drill's aperture. Using a 3mm needle holder via the cold-knife hysteroscope channel, the drill is inserted into the uterine cavity, rotated to engage the tumor, and secured (Figure 2).

2. Traction and Dissection: The suture is gently pulled to externalize the leiomyoma. A 3mm dissector or scissors is then introduced to dissect the tumor from the myometrium in a laparoscopic-like manner (Figure 3-4).

3. Fragmentation and Extraction: Once the majority of the tumor is mobilized, it is fragmented into smaller pieces using scissors. The cervix is dilated as needed, and fragments are extracted with a ring forceps. This innovative approach significantly reduces the complexity of type 2 leiomyoma resection, particularly for fundal tumors. The drill's longitudinal traction enhances exposure and dissection, minimizing risks associated with traditional methods.

**Editorial remark: Editorial remark: This is an experimental approach that is published in the sense of new ideas. The application is not recommended before the scientific assessment.**

10.36205/trocarr6.2025005	Surgical Approaches in Early-Stage Cervical Cancer: Current Debates, Evidence, and Practical Recommendations
10.36205/trocarr6.2025006	Saudi Hysteroscopy Guideline
10.36205/trocarr6.2025007	Diagnostic Hysteroscopy at the Nabil Choucair Health Center: Indications, Technique, Results
10.36205/trocarr6.2025008	Microwave Ablation of Diffuse Uterine Adenomyosis: A Novel Minimally Invasive Fertility Preserving Therapeutic Approach
10.36205/trocarr6.2025009	Beyond the Pelvis: Multidisciplinary Surgical Management of Extra Pelvic Endometriosis – A Video Case Series report
10.36205/trocarr6.2025010	Ureteroneocystostomy in a case of deep infiltrating endometriosis (Case report + Video)
10.36205/trocarr6.vid25005	A Minimally Invasive Retroperitoneal Approach to Apical Compartment Prolapse Repair via vNOTES Sacral Fixation (Video)
10.36205/trocarr6.vid25006	Parametrectomy and discoid resection for deep endometriosis of the medial and posterior compartments using the reverse technique
10.36205/trocarr6.vid25007	Spontaneous Rupture of an Unscarred Uterus at 34 Weeks of Pregnancy (Video – case report)
10.36205/trocarr6.2025011	A Novel Hysteroscopic Approach for FIGO Type 2 Submucosal Leiomyomas (Video presentation new approach)